

RECURRENT ADULT INTUSSUSCEPTION PRESENTING WITH CHRONIC ANAEMIA: A CASE REPORT

M. M. Dauda and *A. M Tabari

Departments of Surgery and *Radiology
Ahmadu Bello University Teaching Hospital, Zaria, Nigeria

ABSTRACT

This is a report of a 45-year-old man who had intussusception for 2 years but presented only after he developed chronic anaemia and cardiac decompensation.

Key words: Intussusception, chronic, anaemia

INTRODUCTION

Adult intussusception is rare occurring in 2-3 in a population of 1,000,000 per year¹. A great majority of cases are associated with a causal lesion², in contrast to childhood intussusception. Chronic intussusception with vomiting abdominal colic, passage of blood stained stools with or without a palpable mass lasting for 2 weeks or more has been documented^{3,4}. Chronic refractory anemia is not a common manifestation of intussusception in adult.

CASE REPORT

A 45 year old man presented with recurrent central abdominal pain and swelling of 2 years duration. The pain preceded the swelling on all occasions. Pain is colicky in nature non-radiating, associated with alteration in bowel habits characterized by bouts of diarrhea. Occasionally patient notices fresh blood on stools. Patient usually palpates a mass in the right side of the abdomen, which spontaneously disappears as the pain subsides. There

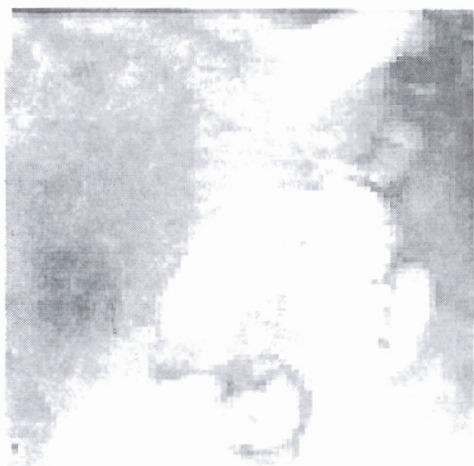
is anorexia and remarkable weight loss. Patient gradually developed dyspnoea on exertion and bilateral pitting pedal oedema. He was admitted twice on medical wards and on both occasions was transfused with packed cells for chronic anemia (normocytic, normochromic). He was referred to the surgical outpatient on his fifth episode when the attending physician palpated an abdominal mass.

Physical examination showed a chronically ill looking patient who was pale, not jaundiced, wasted, no peripheral lymphadenopathy. He had a pulse rate of 122 beats per minute regular, small volume, non-collapsing; blood pressure was normal at 120/80 mmHg supine. Respiratory rate was 26 cycles per minute, regular, resonant percussion note with vesicular breath sounds. Abdominal examination revealed fullness in the epigastrium and tenderness over the right hypochondrium and epigastrium. A mass measuring 22 x 12 cm firm in consistency was felt I could get above and below it and it was non-pulsatile. There was a clinical feeling of

emptiness in the right iliac fossa. There was no ascites, and no other organs were palpable. Rectal examination revealed clean perianal skin, with an empty rectum. No masses were felt sphincter function was good.

A working diagnosis of traverse colonic neoplasm was made. Abdominal ultrasonography showed a roundish echogenic mass (4.7cm x 5.5cm), sub-hepatic in location and anterior to the lower pole of the right kidney. There was no evidence of peristalsis and it appeared to be separate from the duodenum. The mass was thought to be a bowel lesion, probably arising from the ascending colon or hepatic flexure. Barium enema showed arrest of flow of contrast in the mid transverse colon where there was an irregular filling defect measuring (Figure 1).

Figure 1: Barium enema showing filling defect in mid transverse colon



Haemoglobin was 8.0gm/dl, and liver function tests were normal. Stool microscopy showed red blood cells of 4-5/hpf; no ova or cysts were seen. Urea and creatinine were normal. Sodium was raised at 164 mmol/l and

Potassium was low at 2.6 mmol/l. Bicarbonate was 40mmol/l. The patient was resuscitated and anemia and electrolytes were corrected. At surgery an ileo-caeco-colic intussusception was found. There were enlarged mesenteric lymph nodes. Other organs were essentially normal. Oedema and purulent exudates were noted on both the serosa of the colon and small intestine. Transmural necrosis and purulent inflammation are noted in the small intestine. There were no lead points. Histology of the resected specimen was reported as sections of intestine showing mucosal atrophy and transmural acute on chronic inflammation. Biopsied lymph nodes were reported as reactive hyperplasia.

DISCUSSION

Recurrent intussusception is rare.¹ the epidemiology of intussusception in Nigeria has changed over the years. It is now a disease of children just as is the case in Western societies. It is frequently associated with a lead point in adults; there is usually benign or malignant epithelial or mesenchymal growth of the bowel^{3,5} intestinal parasites or diverticular disease. For this reason, adult intussusception should be resected, but this is controversial.⁴ Intussusception presents variedly and is cited as a cause of acute intestinal obstruction in nearly 30% in children.⁶ In Adults however, colicky abdominal pain with passage of bloody diarrhea are the major symptoms³, constipation occurs in only 16%. This lack of obstructive features makes diagnosis difficult, as in this patient. Recurrent colicky abdominal pain, and a palpable abdominal mass is suggestive even if the intussusception is reducible. Recurrent anaemia was noted in our patient, requiring blood transfusion.

The diagnostic yield of plain radiography has been unimpressive and is either non-specific or normal in 10-20%⁸. Barium enema is frequently required to establish a definite diagnosis and provided appropriate precautions are taken it can be used to reduce it. Intussusception produces a sharply marginated convex protrusion into the column of barium⁹. However, occasionally even barium enema may be difficult to interpret. Abdominal ultrasonography classically shows a 'target' lesion of two rings of low echogenicity separated by a hyperechoic ring when seen on transverse section or a 'pseudo-kidney' sign of superimposed kidney-shaped hypoechoic and hyperechoic layers, which represent the oedematous walls of the intussusception when seen on longitudinal section⁹.

Our patient presented with chronic, recurrent colicky abdominal pain and anemia, with non-specific radiological features, consequently, it is not surprising that before the abdominal mass was elicited clinically the patient had elaborate investigations to find the possible cause of his anemia, but with little success. It has been suggested in children that chronic intussusception should be suspected in children with weight loss, and intermittent abdominal pain with prolonged diarrhea.¹⁰ In majority of adult intussusception (93%) an identifiable cause, commonly a Malignancy is present^{11, 12} and resection is preferred to reduction.

REFERENCES

1. Carter CR, Morton AL. Adult intussusception in Glasgow, U.K. *Br J Surg* 1989; 76: 727
2. Agha F. Intussusception in adults. *Am J Radiol* 1986; 146: 527-531
3. Elebute EA, Adesola OA. Intussusception in Western Nigeria. *Br J Surg* 1964; 51: 440-444
4. Reigmen JA, Festen C, Joosten HJ. Chronic intussusception in children. *Br J Surg* 1989; 76: 815-816
5. Ugwu BT, Mbah N, Dakum NK, Yiltok SJ, Legbo JN, Uba AF. Adult intussusception: The Jos experience. *West Afr Med J* 2001; 20: 213-216
6. Stringer MD, Pablot SM, Brereton RJ. Pediatric intussusception. *Br J Surg* 1992; 79: 868-876
7. Adebamawo CA, Yawe T, Ladipo JK. Recurrent intussusception reduced by the patient - a case report. *East Afr J Med* 1995; 72: 267-268
8. Sargent MA, Babyn P, Alton DJ. Plain abdominal radiography in suspected intussusception - a reassessment. *Pediatr Radiol* 1994; 24: 17-20
9. Badoe EA, Archampong EQ, daRocha-Afodu JT. (eds). Intussusception in: Principles and practice of surgery including pathology in the tropics. Ghana Publishing Corporation, Accra, 2000; 540-543
10. Eke N, Eke FU. Chronic intussusception in a child. *Nigeria J Paediatr* 1999; 26: 44-46
11. Azar T, Berger DL. Adult intussusception. *Ann Surg* 1997; 226: 134-138
12. Matter I, Assaff Y, Nash E, Kunin J, Cohen O, Eldar S. Intussusception in adults. *S Afr J Surg* 1997; 35:194-197