

Dental Radiographs Ordered by Dental Professionals: an Experience from a Resource Limited Tertiary Public Health Facility Setting at Muhimbili National Hospital in Tanzania

K.S. Sohal¹, S.S. Owibingire²

¹Dental Service Department, Muhimbili National Hospital, Dar es Salaam Tanzania.

²Oral and Maxillofacial Surgery Department, School of Dentistry, Muhimbili University of Health and Allied Sciences, Dar es Salaam, Tanzania

Correspondence to: Dr Sira Stanslaus Owibingire, E-mail address: sirraowi@yahoo.com

Background: Radiographs remain fundamental tool in diagnosis of dental diseases, their availability and social-economic status of the patient dictates the choice made by professionals. This study was done to determine the indications and types of dental radiographs ordered by dental professionals in a resource limited setting.

Methods: This was a cross sectional study involving 520 patients who underwent dental radiographic investigation. Patients were examined and interviewed. Type of radiographs taken and indications were recorded.

Results: Out of 520 patients, 189 were male, and the mean age of the participants was 31.7 +/- 13.9 years. Most of the patients were aged 20-49 years. The frequent indication was dental caries followed by periapical infection and impacted teeth. Periapical X-rays were taken for 748 teeth of which majority were upper central incisors followed by mandibular molars.

Conclusions: Even in resource limited settings dental caries is still the regular indication for taking dental radiographs, and periapical views are the most frequent type of radiograph ordered. Maxillary central incisors and mandibular molars were types of teeth commonly x-rayed mainly due to the aesthetic importance of the former and the preponderance of dental caries in the later group of teeth.

Introduction

It is generally agreed that, conventional radiography remains a fundamental anatomic tool in the diagnosis of diseases¹. The Computer Tomography and Magnetic Resonance Imaging have replaced conventional radiographs in most of the settings^{1,2}, but in resource limited settings, conventional radiographs in dentistry remain the main reliable and affordable means of imaging. Reasons for taking dental radiographs are several, ranging from investigation, confirmation of diagnosis, to follow up after treatment. There is a notable list of indications for dental x-rays ranging from assessing extent and presence of caries^{3,4,5}, tooth impaction⁶, supernumerary teeth, finding the cause of undue resistance during extractions, tumours and cysts, fractures of the jaws and teeth, TMJ ankylosis and dislocation. Moreover they are used in orthodontic⁷, prosthodontic, assessment of alveolar bone loss, furcational involvement, periapical infections, salivary gland stones and root canal treatment.

Dental X-rays fall in two major categories, which are intra-oral and extra-oral radiographs. The intra-oral radiographic views include periapical (PA), bitewing (BW) and occlusal (OC), while most common extra-oral radiograph is the Panoramic (Orthopantomogram OPG) radiograph. OPG, PA and BW radiographs are used alone or in various combinations in order to achieve final diagnoses⁸. Radiographs however useful, pose some risks to the general body health. For instance, full-mouth series (6 over a lifetime) was associated with a significantly increased risk of meningioma^{9,10}. They have also been associated to thyroid cancer and salivary gland tumours¹⁰, rhabdomyosarcoma¹¹, low birth weight¹² and brain cancer¹³. It is gratifying to note that risks are very minimal that there is no need of worry, and generally, the diagnostic value of the radiographs outweighs any potential radiation hazard¹⁴. However, provided there are some risks involved, this calls for the need to minimize the exposure of patients to unnecessary radiographic investigations.

Despite the fact that it is important to know the indications and types of dental radiographs used, there has been no documented study on this field in Tanzania and most of the other countries in the Africa with limited resources. This portrays difficulty for the hospital management and health planners to know the appropriate types of dental x-rays supplies and materials to tentatively budget or purchase and to know utilization of the radiographic services in different dental clinics in Tanzania.

Patients and Methods

This was a cross sectional descriptive study whereby all patients who attended the radiology unit of the Dental Department at the Muhimbili National Hospital were eligible to be included in the study. The duration of the study was 10 weeks and managed to recruit 520 patients in the study. Patient's demographic information was obtained and filled in a form. The principal researcher conducted the interviews in a separate room immediately after the patients had been attended by the Radiographer while the X-rays were undergoing processing. Interview was done in order to confirm social demographic information documented on the treatment card. Patient examination was done to confirm the indication for undergoing the X-ray investigation and type of teeth x-rayed. Data were coded, transferred to the computer and analyzed by using the SPSS computer program version 17. Ethical clearance was obtained from the Muhimbili University of Health and Allied Sciences Research and Publication committee through the School of Dentistry. Every interviewed patient was assured of the confidentiality of the information given and that the information was to be used for academic and research purposes only.

Results

The study population consisted of a total of 520 patients of whom 331 (63.7%) were females. The male to female ratio was 1: 1.75. The ages ranged from 3 to 78 years, the modal age group was 20-29 years and the mean age was 31.7 (+/- 13.9) years. A total of 520 dental radiographs were taken. Of these, 498 (95.8%) were periapical view, 16 (3.1%) were OPG and occlusal view were only 6 (1.2%). A total of 748 teeth in 520 patients were x-rayed using periapical (PA) X-rays. Of these, 13 were deciduous and 735 were permanent teeth. Out of the 498 patients who underwent periapical X-rays investigation 49 (9.8%) had two periapical X-rays and 5 (1%) had 3 periapical X-rays done. The most frequent tooth to be x-rayed was tooth No. 21 with frequency of 57 (7.7%) of all PA X-rays done followed by No.11 [(56) 7.6%].

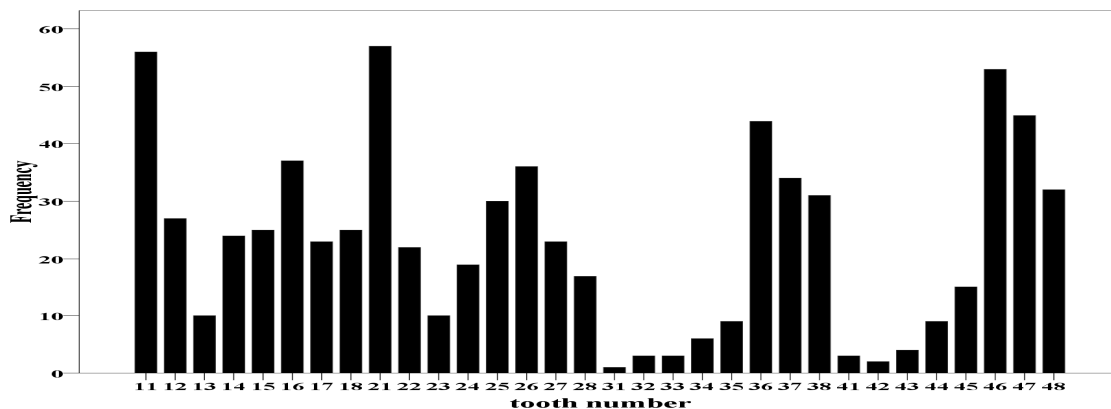


Figure 1. Distribution of Types of Teeth X-rayed

Other teeth with high frequency included No. 46 (7.2%) and 47 (6.1%). In general, the most frequent permanent teeth x-rayed (with frequency more than 30) were the maxillary central incisors (teeth No.

11,12,21,22) followed by mandibular molars (teeth No. 36,37,38,46,47,48), while the least x-rayed teeth were the mandibular incisors (teeth No. 31,32,41,42) (Figure 1).

Table 1. Type of Dental X-ray for Each Indication

Indication for taking X-ray	Type of dental radiograph			Total
	Periapical	OPG	Occlusal	
Dental caries	303	2	0	305
Periapical infection	44	0	1	45
Impacted tooth	24	0	0	24
RCT during	21	0	0	21
Root remnant	20	0	0	20
RCT before	17	0	0	17
RCT after	17	0	0	17
Periodontal infection	7	5	0	12
Infected socket	10	0	0	10
Tooth fracture	8	0	0	8
Orthodontic treatment	3	0	3	6
Defective filling	6	0	0	6
Pericoronitis	5	0	0	5
Trauma to tooth supporting structures	5	0	0	5
Tumour	0	4	0	4
Alveolar bone fracture	2	0	1	3
Dry socket	3	0	0	3
Follow up of root resorption	2	0	0	2
Abscess	0	2	0	2
Salivary gland stones	0	0	1	1
Cyst	0	1	0	1
Fracture of mandible	0	1	0	1
Fracture of maxilla	0	1	0	1
Undue resistance during extraction	1	0	0	1
Total	498	16	6	520

Key: RCT = Root Canal Treatment

Table 2. The Twelve Most Frequent Indications of Taking X-ray by Sex and Age groups

Indications (N)	Sex		Age groups (years)		
	Male No (%)	Female No (%)	0-19 No (%)	20-49 No (%)	50+ No (%)
Dental caries (305)	107 (35.1)	198 (64.9)	41 (13.4)	213 (69.8)	51 (16.7)
Periapical infection (45)	18 (40.0)	27 (60.0)	4 (8.9)	28 (62.2)	13 (28.9)
Impacted tooth (24)	12 (50.0)	12 (50.0)	2 (8.3)	21 (87.5)	1 (4.2)
RCT during (21)	4 (19.0)	17 (81.0)	3 (14.3)	16 (76.2)	2 (9.5)
Root remnant (20)	5 (25.0)	15 (75.0)	0 (0.0)	18 (90.0)	2 (10.0)
RCT after (17)	3 (17.6)	14 (82.4)	4 (23.5)	12 (70.6)	1 (5.9)
RCT before (17)	3 (17.6)	14 (82.4)	1 (5.9)	13 (76.5)	3 (17.6)
Periodontal infection (12)	6 (50.0)	6 (50.0)	1 (8.3)	8 (66.7)	3 (25.0)
Infected socket (10)	5 (50.0)	5 (50.0)	0 (0.0)	8 (80.0)	2 (20.0)
Tooth fracture (8)	4 (50.0)	4 (50.0)	2 (25.0)	4 (50.0)	2 (25.0)
Orthodontic treatment (6)	3 (50.0)	3 (50.0)	4 (66.7)	0 (0.0)	2 (33.3)
Dislodged filling (6)	3 (50.0)	3 (50.0)	0 (0.0)	5 (83.3)	1 (16.7)

Key: RCT = Root Canal Treatment

There were 24 indications among all teeth x-rayed (Table 1) of which the most frequent indication was dental caries in 305 (58.7%) of cases, followed by periapical infections in 45 (8.7%), impacted teeth in 24 (4.6%), and root remnant in 20 (3.8%). Root canal treatment (RCT) as an indication in total were in 55 (17 before, 21 during and 17 after) patients.

A total of 498 periapical view, 16 OPG and 6 occlusal view X-rays were used, the most common indication for PA was dental caries, while for OPG was periodontal infection and for occlusal view was orthodontic treatment (sample images 1-3). Out of the twelve most common indications, dental caries, periapical infections, root canal treatment (before, during and after) and root remnants were the indications with more females than males although the differences were not statistically significant as generally there were more female participants. All indications had majority of patients aged 20-49 years except for orthodontic treatment, which had most of the participants aged 0-19 (66.7%) (Table 1 and 2).

Discussion

Data from a large sample of patients who had attended Radiology Unit in the Dental Department at the Muhimbili National Hospital was taken with the objective of determining the indications and types of dental X-rays ordered by dental professionals at Muhimbili National Hospital. In the study there were more female than male patients who had been referred for undergoing dental X-ray investigations, the former comprising 63.7%. This can be attributed to number of factors, including differences in attendance to dental clinics between males and females, and male patients having tendency of bearing with pain more than female and

The results showed that dental caries was most frequent indication for taking dental X-ray (58.7%) and this can be attributed to the fact that caries is the most frequent tooth pathology that will force a person to seek dental care, and since not all carious teeth are for extraction, dental professionals prescribed X-ray so as to either assess extent, location or confirm the presence of caries. The results also pointed out that orthodontic treatment as indication for dental X-ray was more in age group of 10-19 years, and this can be correlated to the reality that most of orthodontic treatment is carried out during teenage, taking advantage of rapid skeletal and dental growth during this age, e.g. Rapid maxillary expansion can be used successfully in children and adolescents before closure of sutures but in non-growing adolescents and young adults, success rate of maxillary expansion decreases as sutures close¹⁶.

Among the type of most frequent type of dental X-ray ordered by the dental professionals periapical view (95.7%) was highly prescribed, followed by OPG (3.1%) and lastly occlusal view (1.2%). Moreover it was found that, the tooth types most affected by dental caries in this study were the molars and similar findings were also reported by other researchers^{17,18,19}. The anatomy and eruption time of molar teeth could be the probable explanation of why molar teeth are prone to dental caries¹⁹, and dentists will request for radiograph to check the extent of caries or any reason in the process of treatment of such teeth. On the other hand, in permanent dentition, the maxillary central incisors were more X-rayed followed by mandibular molars while the mandibular central incisors were the least. This may be explained by the fact that the maxillary anterior teeth are the most aesthetically important group of teeth. If they have any pathology there is a tendency of patients to actively seek attention to preserve them first before opting for extraction thus radiographic examination of it can be made. The mandibular molars are the common type of teeth affected by the dental caries due to the architecture of these teeth that is the presence of pits and fissures. Hence they retain foods due to escape from flushing action of saliva and difficulty of brushing them. Mandibular central incisors were least x-rayed and this may be ascribed to the reality that these teeth are least affected by caries since they are constantly cleansed by flushing effect of saliva and the tongue.

Limitations which might have affected the study included technical breakdown of the OPG X-ray machine during the period of study, and lack of special films for taking other types of dental radiographs like occlusal and bitewing X-rays hence limiting the types of dental X-rays that could be ordered.

The results of the study may be helpful in assisting administrators and the planners in planning for supply of films and chemicals for processing, to take appropriate measures, like installing more X-ray machines, planning for preventive maintenance and increasing manpower. Also can enhance good practice among the dental professionals by knowing whether they over or under prescribe the X-rays.

Conclusions

The findings of this study suggests that dental caries is the frequent indication for taking dental X-rays at Muhimbili National Hospital as it is for most other resource limited settings, and periapical view is the most frequent type of dental radiograph that is ordered by the dental professionals.

With increased know-how about oral health in society, the demand for different dental services in the population is increasing so will be the utilization of radiographic examination.

Since radiographs remain very important diagnostic tool, there should be more studies done to assess the quality of radiographs taken and their effects, to assess satisfaction of both patient and dental professionals to the overall radiology unit services so as to improve the quality and the service by the radiology unit.

References

1. Chen MYN, Pope JL, Ott DJ. Basic Radiology. 1st ed, 2006, Mc-Graw Hill. Pg 2.

2. Coulthard P, Horner K, Sloan P, Theaker E. Oral and Maxillofacial Surgery, Radiology, Pathology and Oral Medicine. Vol 1, 1st ed, 2003, Churchill Livingstone, Spain. Pg 10.
3. Schwartz M, Pliskin JS, Gröndahl HG, Boffa J. The frequency of bitewing radiographs. Oral Surg Oral Med Oral Pathol 1986; 61(3): 300-305.
4. Langlais RP, Skoczylas LJ, Prihoda TJ, Langland OE, Schiff T. Interpretation of bitewing radiographs: Application of the kappa statistic to determine rater agreements. Oral Surg Oral Med Oral Pathol 1987; 64(6): 751-756.
5. Pitts NB. The use of bitewing radiographs in the management of dental caries: scientific and practical considerations. Dentomaxillofac Radiol. 1996 ;25(1):5-16
6. Sağlam AA, Tüzüm MS. Clinical and radiologic investigation of the incidence, complications, and suitable removal times for fully impacted teeth in the Turkish population. Quintessence Int. 2003; 34(1):53-9.
7. Falk Kieri C, Twetman S, Stecksén-Blicks C. Use of radiography in public dental care for children and adolescents in northern Sweden. Swed Dent J. 2009; 33(3):141-8.
8. Akkay N, Kansu Ö, Kansu H, Çairankaya LB, Arslan U. Comparing the accuracy of panoramic and intraoral radiography in the diagnosis of proximal caries, Dentomaxillofac Radiol 2006; 35:170-174
9. Longstreth WT. Dental X-rays and the risk of intracranial meningioma. Neurology. 2005, 25; 64 (2):350-2.
10. Memon A, Godward S, Williams D, Siddique I, Al_Saleh K. Dental X-rays and the risk of thyroid cancer: a case-control study. Acta Oncol. 2010, 49: 447-
11. Grufferman S, Ruymann F, Ognjanovic S, Erhardt EB, Maurer HM. Prenatal X-ray Exposure and Rhabdomyosarcoma in Children: A Report from the Children's Oncology Group. U.S. National Cancer Institute grants CA21244, CA24507, CA30318, CA30969, CA29139, and CA13539.2009
12. Hujoel PP, Bollen A, Noonan CJ, del Aguila MA. Antepartum Dental Radiography and Infant Low Birth Weight. JAMA.2004, 291(16):1987-1993.
13. Neuberger JS, Brownson RC, Morantz RA, Chin TD. Association of brain cancer with dental x-rays and occupation in Missouri. Cancer Detection and Prevention; 1991, 15(1). 31-34.
14. Wall BF, Fisher ES, Paynter R, Hudson A, Bird PD. Doses to patients from pantomographic and conventional dental radiography. Br J Radiol 1979, 52, 727-734
15. Khan AA, Jain SK, Shrivastav A. Prevalence of dental caries among the population of Gwalior (India) in relation to different associated factors. Eur J Dent 2008; 2: 81-85
16. Altug Atac AT, Karasu HA, Aytac D. Surgically assisted rapid maxillary expansion compared with orthopedic rapid maxillary expansion. Angle Orthod. 2006;76:353-9.
17. Mabelya L, Frencken J, van Palenstein-Helderman W. Dental caries, plaque, calculus and gingival bleeding in 14-17 years old secondary school scholars in Morogoro, Tanzania. Odonto-Stomatologie Tropicale. 1993; 16:4-9
18. Kikwilu EN, Mandari GJ. Dental caries and periodontal conditions among primary school children in morogoro municipality, Tanzania. E A Med J 2000; 78(3): 152-156.
19. Rugarabamu PGN, Poulsen S, Masalu JRP. A longitudinal study of occlusal caries among schoolchildren in Dar es Salaam, Tanzania. Community Dent Oral Epidemiol 2002; (1):47-51.