

Foreign Bodies in the Ear as Seen at Kigali University Teaching Hospital in Rwanda

Mukara B.K., Munyarugamba P.

ENT Department, Kigali University Teaching Hospital, National University of Rwanda.

Correspondence to: Dr Mukara B Kaitesi, Email: kbatamuliza@nur.ac.rw, kaibat@hotmail.com

Background: Foreign bodies (FB) lodged in the ear is a common complaint at emergency departments. FBs range from vegetable such as seeds and grains, non-vegetable such as beads, batteries, cotton wool, toys, stones, folded paper and animate FBs such as ants and cockroaches. A prospective study was carried out in order to determine the type and outcome of FB lodged in the ear, seen at Kigali University Teaching Hospital (KUTH).

Methods: Data from 74 subjects meeting the inclusion criteria was prospectively collected from February to December 2010 in KUTH; a national public referral hospital using a questionnaire prepared for this purpose and analysed using SPSS.

Results: The patients' ages ranged from 1 to 55 years, with a peak in the 3 years old age group. Males accounted for 54% of the cases. Of the patients who were referred to KUTH, 60.8% had had attempts at extraction of the FB done prior to referral to KUTH. The majority (59.5%) of the patients had sustained no trauma to the ear, 37.8% (28) had sustained trauma to the ear yet the FB was still in-situ. Thirty (41%) of the 74 had the FB removed under general anesthesia in the operating room (OR). Various complications in the ear following removal of the FB were recorded in 41.9%.

Conclusion: The risk of complications following removal of FB ear canal is inversely proportional to the skills of the personnel, number of attempts and availability of equipment. Referral to otolaryngology should be considered if more than one attempt is made, more than one instrument is required to remove the FB or presence of any factor attributed to the FB or the ear canal that renders it difficult to remove in a non ENT setting.

Introduction

Foreign bodies in the ear are a common presenting complaint at emergency departments. FBs range from vegetal including seeds and grains, non-vegetal such as beads, batteries, cotton wool and animate FBs such as ants and cockroaches¹. Some of the FBs could be deeply impacted, large, slippery, difficult to grasp or a combination of these properties. While most foreign bodies can be easily removed by general practitioners and emergency physicians, some may be difficult and warrant referral for specialised care by an otolaryngologist. In such cases, proper assessment and early decision to refer for proper management should be considered in order to avert complications that are associated with multiple attempts at removal of FBs ranging from mild trauma to severe otologic sequelae including hearing loss^{1,2}.

The objectives of this study were:

1. To determine the frequency of FB in the ear seen at KUTH
2. To determine the types of foreign bodies seen.
3. To determine the types and severity of complications of FB removal.
4. To establish the relationship between referral patterns and complications of foreign bodies in the ear.
5. To document the treatment recommended to the patients in relation to foreign body presentation.

Patients and Methods

The study population consisted of consecutive patients presenting with FBs in the ears at Kigali University Teaching Hospital (KUTH) over a period of 6 months from February 2010. Data from 74

patients meeting the inclusion criteria was collected using a questionnaire prepared for this purpose. Age, gender, duration since insertion of the FB, whether the patient visited another health facility before being referred to KUTH, if attempts had been made to remove the FB, whether anesthesia was administered before, type of FB, method used to remove the FB, need for adjuvant treatment and any complications associated with removing the FB were recorded. Data was analysed using SPSS.

Results

Patients' age ranged from 1 to 55 years. The peak was at 3 years accounting for 24.3% while 13 (17.6%) and 10 (13.5%) patients were aged 5 and 4 years respectively. The males comprised 40 (54%) of the study population. Figure 1 gives a summary of the ages. Only 1.35% (1) of subjects had an FB in both ears while 66.2% (49) had a FB in the right ear. Only 23 (31.1%) presented within 24 hours while 31 (41.9%) presented after 24 hours of insertion of the FB; 5 (6.8%) reported after a week following FB insertion. Fifteen (20.3%) of the patients did not know for how long the FBs had been present prior to admission.

Vegetables were the most common FB encountered in 22 (27.9%) while beads were the second most common in 10 (13.5%) as shown in Figure 2. The majority (85.1%) of subjects was referred from district hospitals or private health facilities; 11 (15.9%) presented without a referral letter. Of the patients who were referred to KUTH, 45 (60.8%) had attempts at extraction of the FB done before referral to KUTH.

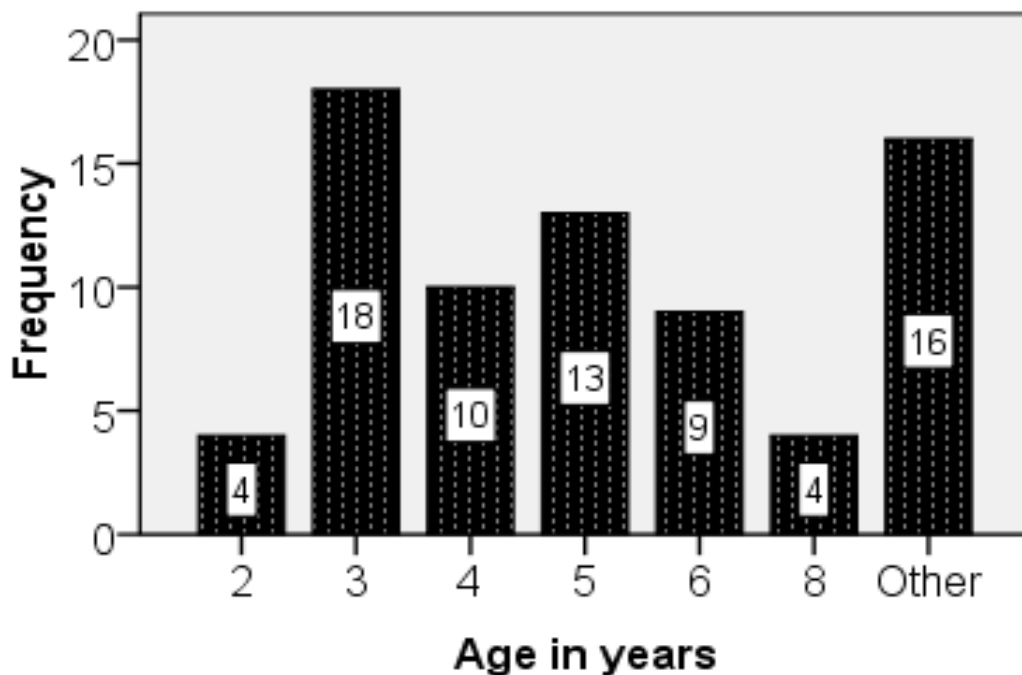


Figure 1. Age in Years

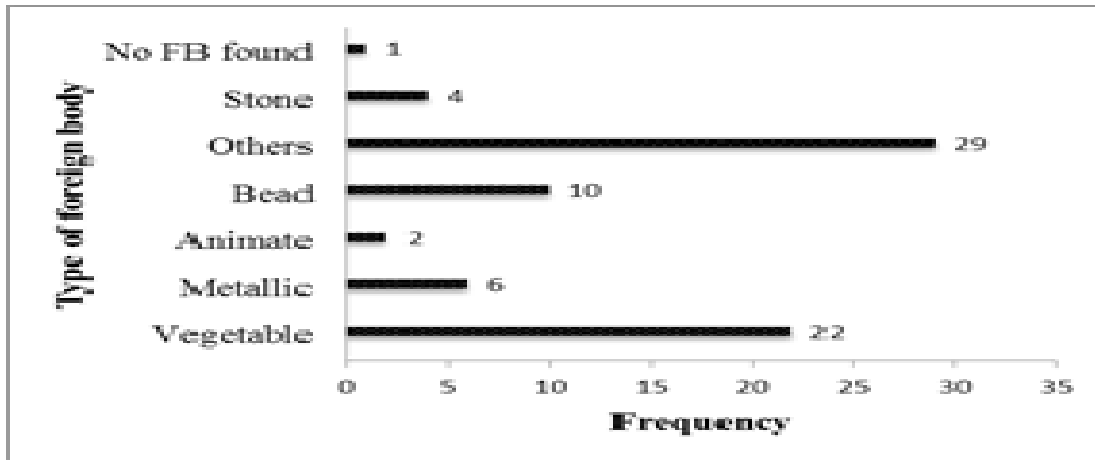


Figure 2. Types of foreign bodies seen

The majority (59.5%) of subjects had sustained no trauma to the ear, 37.8% (28) had sustained trauma to the ear yet the FB was still in-situ. Although 2.7% (2) had sustained trauma to the external auditory canal (EAC), the FB had been successfully extracted.

Of the 45 patients who underwent attempts at extraction before referral, 62.3% (28) required general anesthesia at KUTH in order to extract the FB. Conversely, only one (3.4%) patient who had not had prior attempts at extraction required general anesthesia for extraction of the FB at KUTH. A total of 43 (58.1%) of all 74 patients had no trauma to the ear at all. However, 19 (25.6%) had trauma to the external auditory canal, 5 (6.8%) had trauma extending in to the middle ear while another 7 (9.5%) had traumatic perforation of the tympanic membrane as shown in Figure 3. Of the subjects who had prior attempts of extraction before referral, only 33.3% (15) did not sustain any trauma. 11.1% (5) sustained trauma extending to the middle ear while the rest had varying extent of trauma as shown in Table 1.

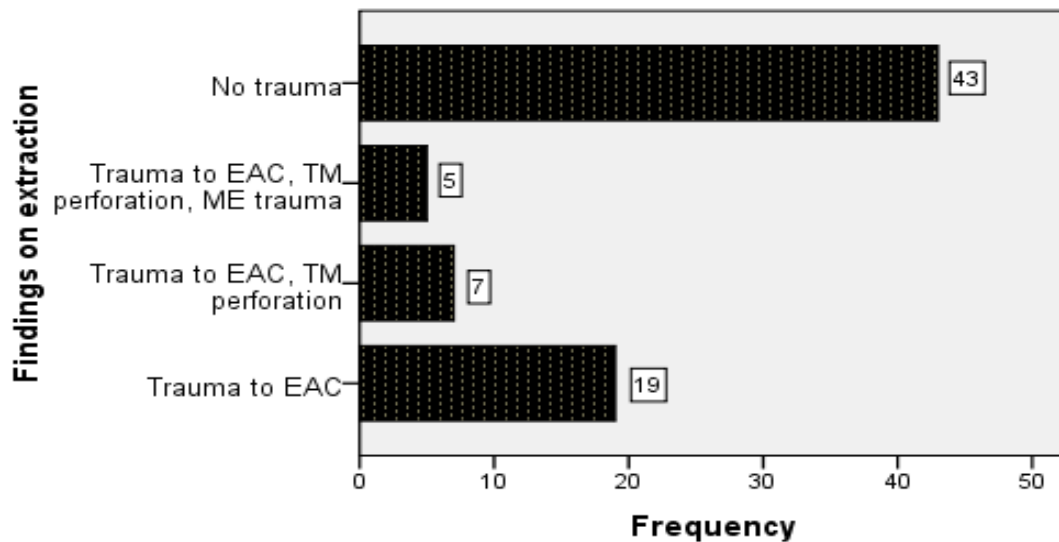
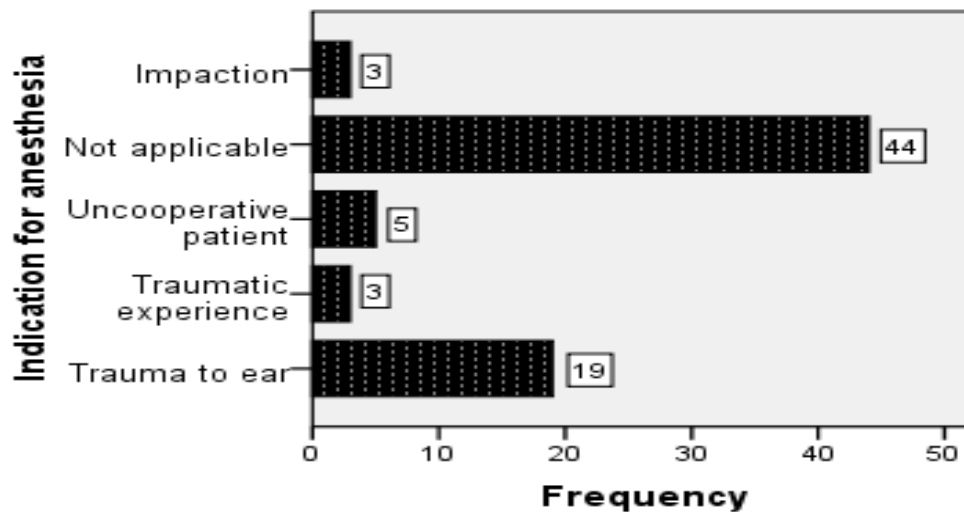


Figure 3. Findings on extraction.

Table 1. Comparison Between Prior Attempts to Extract FB and Trauma Sustained.

Attempt to extract	Findings on extraction				Total
	Trauma to EAC	Trauma to EAC, TM perforation	Trauma to EAC, TM perforation, ME trauma	No trauma	
Yes	40% (18)	15.6% (7)	11.1% (5)	33.3% (15)	45
No	3.4% (1)	0	0	96.4% (28)	29
Total	25.7% (19)	9.5% (7)	6.8% (5)	58.1% (43)	74


Figure 4. Indications for anesthesia

Thirty (41%) of the 74 patients had the FB removed under general anesthesia in the OR (Figure 4). Indication for anesthesia included trauma to the ear in 19 (63.3% (19), uncooperative patient in 5 (17% 5) impacted FB, and traumatic experience in 3 cases (10%3) each. A post auricular incision to access the middle ear was used in 1 subject while instrumentation using a hook or alligator forceps was used in 63.5% (47) subjects. In 35.1% (26) ear lavage was done.

While 93.1% (27/29) of subjects who had no prior attempts at FB extraction required no adjuvant treatment after the FB was extracted, 53.3% (24/45) of those with prior attempts at removal had an adjuvant form of treatment after the FB was extracted. Adjuvant treatment ranged from analgesics to topical steroids and systemic antibiotics, dictated by severity of injury. The remaining 46.7% (21/45) of those who had prior attempts of extraction required no adjuvant treatment at KUTH.

Overall, 64.9% (48/74) of subjects did not require adjuvant treatment after FB extraction at KUTH. Indications for adjuvant treatment are shown in figure 5.

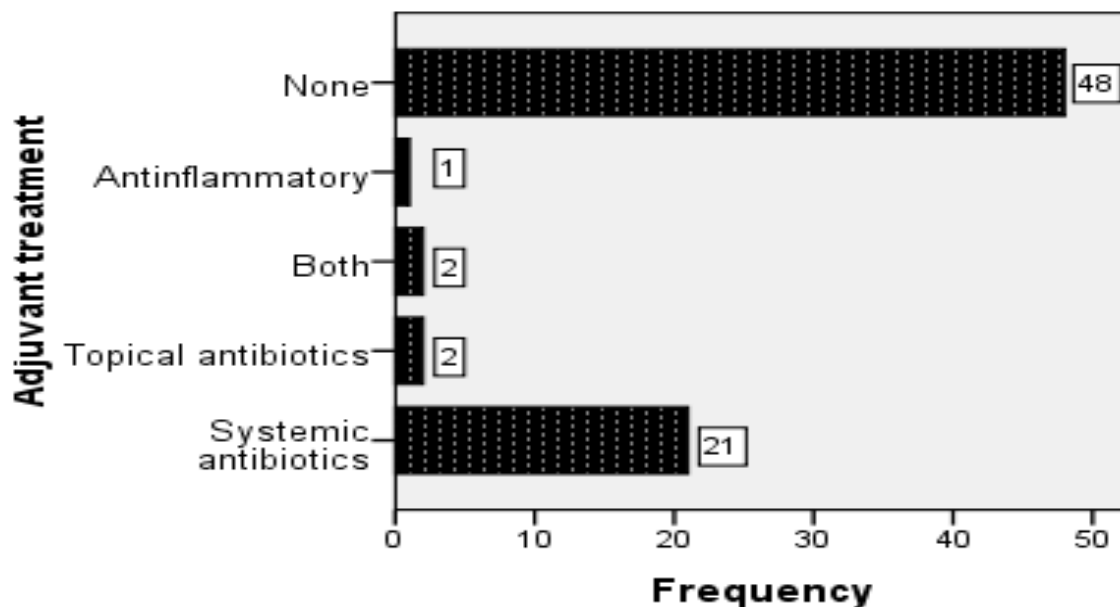


Figure 5. Indications for adjuvant treatment

Discussion

Attempts at removal of foreign bodies from the ear should be done in the presence of adequate visualisation, appropriate instrumentation and proper skills at removing foreign bodies. 78.4% of subjects were aged between 2 and 8 years explained by play and curiosity among children. There was a right ear predominance of FB in the ear (54%) which is consistent with findings in other similar studies⁶. In agreement with other studies, we had a male predominance of 54% which is comparable to the study by Ayatunde et al¹ who obtained 53% males and Thompson et al¹¹ who recorded 52% males.

A greater proportion of patients presented after 24 hours (41.9%) as compared to presentation within 24 hours of insertion of the FB (31.1%). These findings are different from those reported by Tiago et al⁶. The health system in Rwanda favours early identification and referral of patients hence the early presentation. However, attempts at extraction at lower level health facilities resulted in delay thus having a greater proportion of patients presenting after 48 hours of insertion. This is a short duration compared to the average of 14.24 days obtained in the study by Tiago et al⁶. Interestingly, 20.3% did not know for how long they had the FB before presenting to hospital. Such cases were children (analysis to show age distribution of those who did not know duration would be appropriate) who presented with symptoms caused by a long standing FB such as pain or hearing loss and adults who accidentally left cotton in-situ during ear cleaning. Animate FB would not be left unidentified or unattended due to the discomfort they cause.

In their study on 244 patients with FB lodged in the ear, Marin and Trainor⁴ found that 80% of them were removed successfully by emergency room physicians while 12% had complications. Complications were associated with multiple attempts at removal and the use of multiple instruments. In agreement with our study, this study showed that some of the patients referred to the otolaryngology clinic underwent FB removal without any form of anesthesia while some will require anesthesia⁴. 60.8% of patients seen in the ENT department had had prior attempts at

extraction. Of these, 62.3% had the FB extracted in the operating room under General anaesthesia. This proportion is higher than that recorded in other studies; 53.85% reported by Schulze et al⁷ but similar to that reported by Thompson et al¹¹ Other studies have reported ranges from 8.6% to 30%^{12,13}.

Otolaryngology still has paucity of staff and those available are station in hospitals in the city. In effect, an attempt by unskilled professionals coupled with lack of proper equipment explains the high incidence of complications associated with FB removal in this study. Only 3.4% of patients who had not been subjected to prior attempts at extraction sustained complications. This is comparable to the results obtained by Bressler's et al⁸ at 5.1% and underscores the importance of skilled staff, proper equipment and or referral to ENT specialists.

Potential complications arising from removal of FB lodged in the ear include trauma to the external auditory canal which could eventually result in stenosis of the canal, conductive hearing loss, ossicular chain disruption, sensorineural hearing loss, facial nerve paralysis, vertigo or even meningitis². Our study recorded complications of varying severity including trauma to the External Auditory Canal (EAC), tympanic membrane perforation, and middle ear trauma. These complications are reported in literature^{4,11}. We did not investigate inner ear complications such as vertigo and sensorineural hearing loss since majority of the subjects were children who could not report balance disorders. Besides, cases of FB ear whether extracted in the operating room or in the clinic are usually managed as day cases and may not return for follow up.

Adjuvant treatment is not necessary after uncomplicated removal of the FB⁹ although some extraneous factors may dictate their necessity. In our study, 93.1% of subjects who had no prior attempts at FB extraction required no adjuvant treatment after the FB was extracted compared to 53.3% of those with prior attempted removal who required adjuvant treatment. Indications for adjuvant treatment included edema of the EAC, severe trauma to the EAC and middle ear trauma. A proportion of patients had extraction attempts in an operating room in a non ENT setting before referral to KUTH. The failure to extract the FB even with the patient under General anaesthesia was due to lack of adequate skills by the Healthcare personnel at the peripheral facilities

There are different techniques for removal of FB lodged in the ear canal. These are dictated by availability of instruments and equipment, the type of FB to be extracted and the space available for manoeuvrability of the FB. Otologic forceps or micro-forceps with or without a microscope, right-angle hook, cyanoacrylate applied on the bare end of a cotton tip, ear lavage or suction can be used to remove FBs. In the current study, while a post auricular incision to access the middle ear was used in 1 subject who had an impacted FB lodged in the middle ear, instrumentation using a hook or alligator forceps was used in 63.5% of patients and ear lavage in 35.1%. Choice of technique was dictated by type of FB and patient characteristics including age and level of cooperation. A hook may be used to remove rounded, slippery ungraspable objects while forceps can remove graspable objects such as paper cotton and other irregular objects. Cyanoacrylate applied on the FB through the cotton tip can be used to extract slippery or ungraspable FBs in cooperative patients. Suction or irrigating the ear canal can be used depending on the type of FB, cooperation from the patient and space around the FB; usually in non-impacted cases without suspicion of tympanic membrane perforation^{2,10}.

Conclusion

The risk of complications following removal of FB ear canal is inversely proportional to the skills of the personnel, number of attempts and availability of equipment. Multiple attempts increase the need for adjuvant treatment after extraction which is otherwise unnecessary.

Referral to otolaryngology should be considered if more than one attempt is made, more than one instrument is required to remove the FB or presence of any factor attributed to the FB or the ear canal that renders it difficult to remove in a non ENT setting. An individualised treatment approach should be adopted for each case.

Acknowledgement

The late Dr.Nyakayiro for his role in data collection. Prof. Isaac M Macharia for his review and advice.

References

1. Ayotunde J F, Oluwole O A O, Taiwo G A I. Healthcare givers' skill and foreign bodies in the ears of children in the tropics. *International Journal of Pediatric Otorhinolaryngology* 71 no. 2 (2007): 191-195
2. Dance D, Riley M, Ludemann J P. Removal of ear canal foreign bodies in children: What can go wrong and when to refer BC Medical Journal vol. 51 no 1 (2009): 20-24
3. Steenerson, R L, G W Cronin, and L B Gary. "Vertigo and Cochlear Implantation." *Otology and Neurotology* 22 (2001): 842-843.
4. Marin JR, Trainor JL. Foreign body removal from the external auditory canal in a pediatric emergency department. *PediatrEmerg Care* 2006; 22:630-634.
5. Singh GB, Sidhu TS, Sharma A, et al. Management of aural foreign body: An evaluative study in 738 - consecutive cases. *Am J Otolaryngol* 2007; 28:87-90.
6. Tiago RSL1, Salgado DC, Corrêa PJ, Pio MRB, Lambert EE Foreign body in ear, nose and oropharynx: experience from a tertiary hospital. *Rev Bras Otorrinolaringol* 2006;72(2):177-81
7. Schulze SL, Kerschner J, Beste D. Pediatric external auditory canal foreign bodies: a review of 698 cases. *Otolaryngol Head Neck Surg* 2002; 127:73-8.
8. Bressler K, Shelton C. Ear foreign-body removal: a review of 98 consecutive cases. *Laryngoscope* 1993; 103:367-70.
9. Ansley JF, Cunningham MJ. Treatment of aural foreign bodies in children. *Pediatrics*. Apr 1998;101 101(4 Pt 1):638-641
10. Davies PH, Bengner JR. Foreign bodies in the nose and ear: a review of techniques for removal in the emergency department. *J AccidEmerg Med*. Mar 2000; 17(2):91-4.
11. Thompson KS, Wein OR, Paul O. Dutcher OP. External Auditory Canal Foreign Body Removal: Management Practices and Outcomes. *Laryngoscope*, 2003;113:1912-1915
12. Ansley JF, Cunningham MJ. Treatment of aural foreign bodies in children. *Pediatrics* 1998;101:638-41.
13. DiMuzio J, Deschler DG. Emergency department management of foreign bodies of the external auditory canal in children. *OtolNeurotol* 2002;23:473-475.