

Surgical Management of Prepubertal Urethral Prolapse: A report of 3 cases.

A.A. Abolarinwa, M.J. Bioku, I.N. Akinwumi, S.O. Ikuerowo, J.O. Esho

Department of Surgery, Lagos State University College of Medicine and Teaching Hospital, Ikeja, Lagos, Nigeria

Department of Paediatrics, Lagos State University College of Medicine and Teaching Hospital, Ikeja, Lagos, Nigeria

Correspondence to: Abolarinwa A.A, Email: docbeebie@yahoo.com.

Background: Urethral Prolapse is rare but a differential diagnosis of interlabial masses in prepubertal females. It usually presents with vaginal bleeding and may heighten the suspicion of sexual abuse.

Methods: Our series of 3 cases all presented with vaginal bleeding and all had primary surgical excision of the prolapsed urethral mucosa.

Results and Conclusion: Surgical management is definitive and should be considered as the first line treatment in our environment. Parents, caregivers and medical personnel in our environment should be able to identify and recognise it

Introduction

Urethral prolapse (UP) is a circular protrusion of the distal urethra through the external meatus¹. The diagnosis is basically clinical. Because urethral prolapse is rare, the rate of misdiagnosis by general physicians is high. Increased physician awareness and early recognition of urethral prolapse avoids unnecessary investigation and anxiety for the patients and to the care-givers. We report 3 cases of UP in prepubertal girls who had successful surgical treatment in our center between July 2004 and February 2012.

Case 1

A 6 year old girl who presented to the Urology clinic with a 2 months history of bleeding from the vulva noticed as blood stains of her pants. There were no other symptoms. On examination, there was a sherry red, doughnut shaped protrusion from the urethral meatus. It was soft and non-tender.

A clinical diagnosis of Urethral Prolapse was made. She had routine laboratory investigations which were normal. She had a circumferential excision of the prolapsed urethra with approximation of the urethral mucosa. A urethral catheter was passed and retained for 48 hours. The urine stream after removal of the catheter was satisfactory. She was discharged home and subsequent follow-up review at the clinic showed she was voiding satisfactorily and has had no recurrence after 2 years.

Case 2

A 5 year old girl presented to the paediatricians with a 2 day history of bleeding from the vulva which was noticed as blood stains on her pants after she returned from school. There was no pain, dysuria nor haematuria and no weight loss. There was no history of sexual assault. On examination, the vulva was foul smelling with a protruding, erythematous mass between the labia (Figure 1). A provisional diagnosis of *Botyroides* Tumour was made.

A high vaginal swab microscopy, culture and sensitivity yielded coagulase negative staphylococcus. A pelvic ultrasound scan and contrast enhanced magnetic resonance scan were essentially normal. She was thereafter referred to the urology unit for further review.

Examination under anaesthesia revealed a prolapsed erythematous urethral mucosa. The vagina was normal. The prolapsed urethra was excised with approximation of the urethral mucosa. A urethral catheter left in situ for 24 hours. She was discharged home the next day and seen at the outpatient clinic 3 days and 2 weeks post operation. She was voiding satisfactorily and there has been no recurrence after 4 years.

Histopathological examination of the specimen showed an almost round, firm, greyish tissue measuring 1.1 x 0.9cm and weighing 0.3g. There was a lumen in the central area of the tissue measuring 0.5cm in its widest diameter. Microscopy showed seemingly polypoid tissue covered in parts by transitional to non-keratinised stratified squamous epithelium. The stroma was loose, oedematous and contained many thin walled vessels of varying sizes. Some vessels were tortuous, few were close to the overlying epithelium with accompanying superficial ulceration and there was haemorrhage and thrombosis of the superficial vessels. The stroma was infiltrated by lymphocytes, plasma cells and eosinophils. Some peri urethral glands were noted. A pathological diagnosis of capillary hemangioma compatible with prolapse of the urethra was made.

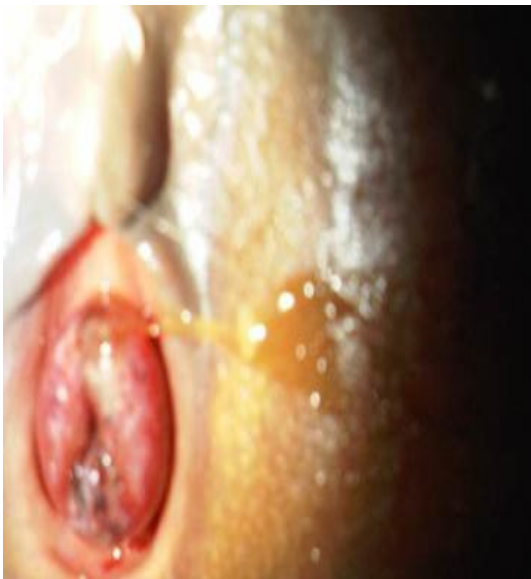

Figure 1. Circular, oedematous interlabial mass.

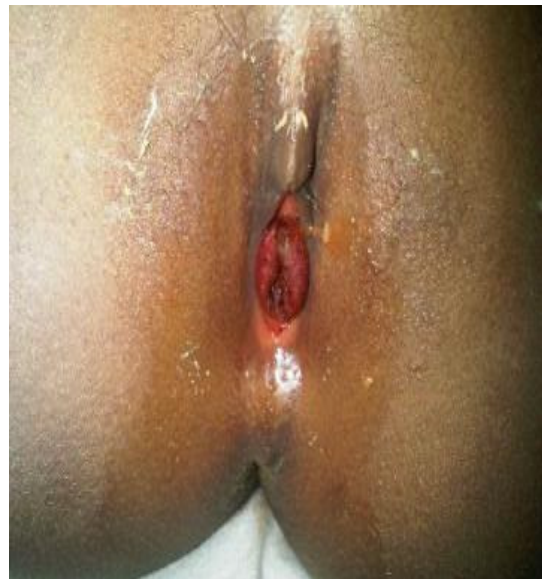

Figure 2: Congested prolapsed urethra.

Case 3

A 6 year old girl presented to the Urology clinic with a 2 weeks history of bleeding and mass from the vulva. There was no pain, dysuria nor hematuria. There was no history of sexual assault. She is a known asthmatic. On examination, there was a well circumscribed, erythematous, doughnut shaped mass at the urethral meatus. (Figure 3). A diagnosis of Urethral Prolapse was made. A urethral catheter passed through the center of the mass in to the bladder (Figure 4). She had a circumferential excision of the prolapsed urethra and approximation of the urethral mucosa. The urethral catheter was left in situ for 24 hours. She was discharged home the next day and has been seen at the outpatient clinic. She is voiding satisfactorily and no recurrence after 1 year.

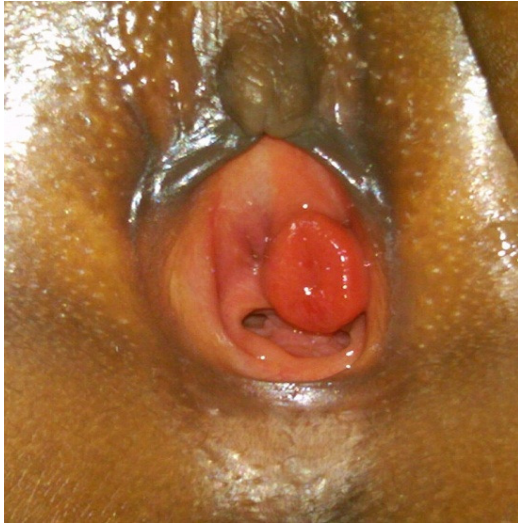

Figure 3. Doughnut shaped mass at the urethral orifice.

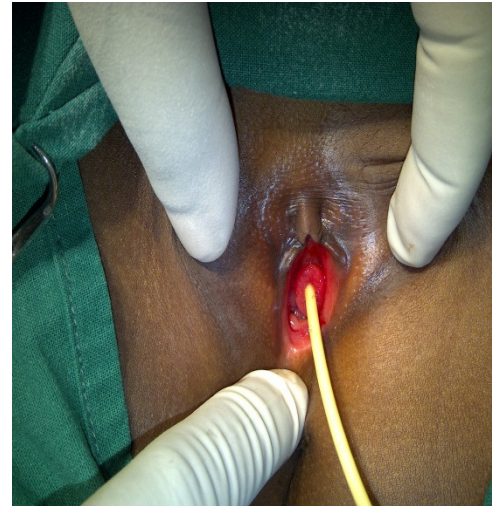


Figure 4. Urethral Prolapse with a catheter through the center of the mass

Discussion

Urethral prolapse is a pathological situation which occurs when the urethral mucosa evaginates beyond the urethral meatus, resulting in vascular congestion and oedema of the prolapsed tissue². It was first described by Solingen in 1732³. Its incidence is 1:3000 children⁴. It is more common among prepubertal girls of African descent^{5, 6}. The average age ranges between 4 and 7 years and can be seen in infants as early as 6 weeks old^{2, 7, 8}. The average age of the children in our series was 5.7 years. In Nigeria, Ola and Arowojolu⁹ reported a series of 19 cases within a 10 year period and Adesiyun and Samaila¹⁰ reported 15 cases in 10 years.

The aetiology of this rare condition is unknown; however several theories have been postulated. Some authors indeed think that the aetiology could be multifactorial¹. One report of urethral prolapse in identical twins suggests that heredity may play a role⁴. A low oestrogenic state has been suggested as an aetiological factor and may explain the preponderance of the condition in the prepubertal and postmenopausal age groups¹⁷, poor attachments between the two layers of smooth muscle surrounding the urethra, combined with episodic increases in intra-abdominal pressure predisposes to UP. Causes of increased intra-abdominal pressure in children include: constipation and chronic cough. Our 3rd case was asthmatic and this could have been a contributory factor.

Genital trauma due to cultural practices may be a predisposing factor in our environment. In a review by Adesiyun and Samaila, 16% of their patients had had some form of Female Genital Mutilation (FGM)¹⁰. They postulated that the possible explanation for FGM in the pathophysiology of urethral mucosa prolapse may be damage and/or disruption to the perineal muscular attachment of the urethra as a result of this cultural act.

As the urethral mucosa prolapses, there is constriction of the prolapsed mucosa in a circumferential pattern by the muscular tone of the urethral meatus, resulting in oedema, congestion, strangulation and necrosis thus the oedematous circular tissue classically seen in UP.

Prepubertal UP is predominantly asymptomatic. Often, it is an incidental finding during routine examination. The most common presentation is vaginal bleeding associated with an interlabial, periurethral mass. All the 3 children in our series presented with these 2 symptoms. Symptomatic children present with blood spots on their underwear or diapers. UP is quite often misdiagnosed as seen in our 2nd case which was initially thought to be a tumour^{6,15}.

Until urethral prolapse is definitively diagnosed, the presence of blood in the genital area should raise the suspicion of sexual abuse¹⁶. Voiding symptoms are typically rare in the paediatric population but when they are present, patients may report dysuria, urinary frequency or introital pain if the prolapsed mucosa becomes thrombosed or gangrenous. Hematuria is uncommon and rarely acute urinary retention may occur¹¹.

Radiological investigations are usually not necessary in prepubertal UP. A urinalysis and urine microscopy, culture and sensitivity may be done if urinary tract infection is suspected.

The classical appearance of UP of the 'doughnut' sign¹⁸ enables diagnosis to be made easily on clinical grounds alone. Also, observation during voiding or catheterization of the central opening is diagnostic¹ (Figure 4). All other causes of interlabial masses are differentials of UP.

Treatment may be medical; topical oestrogen and antibiotic creams and sitz baths. Some series of studies recommend conservative therapy for prepubertal girls as a first line approach to management^{1,19}. Surgical treatment ranges from cauterization of the prolapsed urethral mucosa to a complete mucosal excision and approximating the mucocutaneous junction at the meatus. Various techniques have been described. It should be noted that the average urethral length of a child is shorter than the adult female; approximately 26 mm as measured by perineal ultrasound,¹² thus traction on and excessive excision of the redundant mucosa should be avoided. This is to prevent damage to the external sphincter.

Better outcomes were achieved with surgical excision¹³ though a study of 65 cases in Ivory Coast showed comparable and satisfactory results with both medical and surgical treatment.¹⁴ All the children in our series had primary surgical excision.

A urethral catheter is passed and left for 24 – 48 hours. According to Fiogbe et al², the patient should stay in hospital for 24 hours after the removal of the catheter in order to monitor for a possible acute urinary retention. Two of the children in our series had a urethral catheter for 24 hours and 1 for 48 hours. We recorded no complications in our series and there has been no recurrence so far.

Conclusion

- Urethral Prolapse is rare and a disease of prepubertal girls. Its diagnosis is basically clinical.
- All medical personnel attending to children especially paediatricians and general practitioners should be familiar with the anatomy of the genital region in children and be able to recognize interlabial masses particularly Urethral Prolapse.
- Excision of the prolapsed mucosa and early hospital discharge which is simple and curative is desirable.

References

1. Raymond Rackley, Sandip P Vasavada, Michael S Ingber. Urethral Prolapse: www.emedicine.com. 2009
2. M.A Fiogbe, G.M Hounnou, A Koura, K.A Agossou-Voyeme. Urethral mucosal prolapse in young girls: A report of nine cases in Cotonou. Afr J Paediatr Surg 2011;8:12-4
3. Richardson, D.A., Hajj, S.N., Herbst, A.I. Medical treatment of urethral prolapse in children: Obstet Gynecol. 1982; 59: 69 - 72.
4. Mitre, A., Nahas, A., Gilbert et al. Urethral prolapse in girls Familial case. J Urol. 1987; 137:157.
5. Valerie, E., Gilchrist, B.F., Frischer, J., Scriven, R., Kolz, D.H., Ramensfsky, M.L. Diagnosis and treatment of urethral prolapse in children. Urology. 1999; 54(6): 1082 - 1084.
6. Falandry L. [Prolapse of the urethra in black girls: Personal experience in 11 cases. Med Trop (Mars) 1994; 54:152-6.
7. Akani CI, Pepple DK, Ugboma HA. Urethral prolapse: A retrospective analysis of hospitalized cases in Port Harcourt. Niger J Med 2005; 14:396-9.
8. Pouya M, Van Cangh PJ, Wese FX, Opsomer RJ, Saleh M. [Mucous prolapse of the urethra]. Acta Urol Belg 1995; 63:23-9.
9. Ola. B, Arowojolu O.A. Urethral Prolapse in a West African hospital. Int J Gynaecol Obstet 1999; **66**: 187 – 8
10. A. G. Adesiyun and M.O. Samaila. Childhood urethral mucosa prolapse: outcome of surgical treatment. Nig J of Surg Research, Vol 8 No 1 – 2, 2006 : 63 – 66
11. Venugopal S, Duncan ND, Carpenter R. Urethral prolapse in girls. Pediatr Surg Int. 1995;10:115–117
12. Hirdes MM, de Jong TP, Dik P, Vijverberg MA, Chrzan R, Klijn AJ. Urethral length in girls with lower urinary tract symptoms and forme fruste of female epispadias. J Pediatr Urol. 2010 Aug; 6(4):372-5. Epub 2009 Dec 28
13. Fernandes, E., Dekermacher, S., Sabadin, M. et al. Urethral prolapse in children. Urol. 1993; 41: 240.
14. daSilva Anoma S, Bertin K.D, Ossenou O, Gaudens D.A, Yao D, Roux C. Prolapse of the Urethral Mucosa in young girls in the Ivory Coast. Ann Urol 2001; **35**: 60 – 3
15. Anveden-Hertzberg L, Gauderer MW, Elder JS. Urethral prolapse: an often misdiagnosed cause of urogenital bleeding in girls. Pediatr Emerg Care. 1995 Aug; 11(4):212-4.
16. Shavit I, Solt I. Urethral prolapse misdiagnosed as vaginal bleeding in a premenarchal girl. Eur J Pediatr. 2008 May; 167(5):597-8. Epub 2007 Jun 7
17. Batra SC, Iosif CS. Female Urethra, a target for oestrogen action. J Urol 1983; **129**: 418-419
18. Shetty A, Coffman K, Harmon E. Urethral prolapse. J Pediatr. 1998; 133:552.
19. Wright M. Urethral prolapse in children--alternative management. S Afr Med J. Oct 17 1987; 72(8):551-2.