

## Massive Neurofibroma of the Breast: Late Presentation in a Low Resource Nation

C. Kajombo<sup>1</sup>, I. Roy<sup>2</sup>, M. Gemer<sup>1</sup>

<sup>1</sup>Department of Surgery, Kamuzu Central Hospital, Lilongwe, Malawi

<sup>2</sup>St. Mary's Hospital, Montreal, Quebec, Canada and associate professor, Faculty of Medicine, McGill University

**Correspondence to:** Mordechai Gemer, MD, PhD, Email: [mgemer@aol.com](mailto:mgemer@aol.com)

*Neurofibromas are benign nerve sheath tumors that are extremely rare in the breast. We report a massive disfiguring neurofibroma of the female breast. It exemplifies a disease presenting late in its natural history, typical of patients seeking medical care in low resource countries.*

**Key words:** Neurofibroma, Breast, Presentation

### Introduction

Neurofibromas are uncommon benign tumors of nonmyelating Schwann cell origin that arise in the peripheral nervous system. The vast majority occurs in the skin and is extremely rare in breast tissue. Neurofibromas usually occur in patients with neurofibromatosis (NF), although they can occur sporadically. Neurofibromatosis is genetically inherited autosomal dominant disorder and occurs across all ethnic groups. It presents in two types: Neurofibromatosis type 1 (NF 1) and neurofibromatosis type 2 (NF 2).

Neurofibromatosis type 1 (von Recklinghausen Syndrome- 1882) is the most common form of NF, accounting for up to 90% of the cases. It is associated with the peripheral nervous system. Patients usually develop multiple subcutaneous tumors and changes in skin pigmentation (café-au-lait spots). It has a frequency of 1 in 4,000 people. NF 2, which originates from a different chromosome is connected with the central nervous system, less associated with benign tumors and can cause spine and brain tumors. It has a frequency of 1 in 40,000 people. Breast neurofibromas are usually associated with NF 1.

Neurofibromas of the breast are classified in two types; dermal and plexiform. Dermal neurofibromas are associated with a single peripheral nerve, while plexiform neurofibromas are associated with multiple nerve bundles<sup>1</sup>. The clinical manifestations of both types are similar, nodules on or under the skin, and can cause itching, pain and possible disfigurement if left untreated. Dermal breast neurofibromas usually do not lead to subsequent malignant transformation, but, about 10% of plexiform breast neurofibromas may transform into a malignant peripheral nerve sheath tumor<sup>1</sup>.

We present a case report of a patient with NF1 who developed massive, disfiguring but benign neurofibroma of the breast.

### Case Report

The patient who is 27 years old female from a small village in Malawi, Africa, presented with an enlarged left breast and multiple scattered skin nodules. She claimed that the left breast was slightly enlarged at adolescence but within few years progressively got bigger to current size especially after the birth of her last child 4 years earlier. The breast was not painful and there was no history of nipple discharge. The patient also stated that since her birth, she also had nodules on her entire body but mostly on the back. The nodules were not painful but slowly got bigger. She is the only one in her family with this disorder.

On examination, the left breast was extremely stretched reaching her knees while standing and the patient placed the breast on her lap when she was sitting (Figures 1 and 2). There was a mass in the distal end of the breast measuring 25x15x10 cm, which was firm and non-tender. Large skin ulcerations were present around the areola. The right breast was normal. Multiple hyperpigmented skin nodules were noted over her body especially the back. She also had masses in her right hand and on the plantar surface of the left foot, soft in consistency and measuring 5x5 cm each.

After adequate preparation, the patient was taken to the operating room. Under general anesthesia excision of part of the stretched breast with the mass was done. The specimen weighed 7kg. The post-operative course was without any complication, the patient was discharged with sutures to be removed at the outpatient clinic (Figure 3). Macroscopically the submitted specimen showed white rubbery tissue diffusely distributed in dermal and subcutaneous locations. Microscopic examination showed benign spindle cell proliferation with loose background and mast cells, consisted with diffuse neurofibroma (Figure 4). Immunohistochemistry for S-100 demonstrated only patchy positivity.

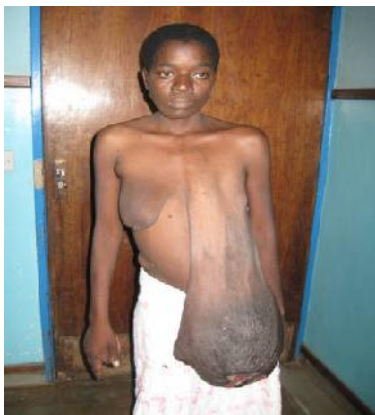

Figure 1



Figure 2

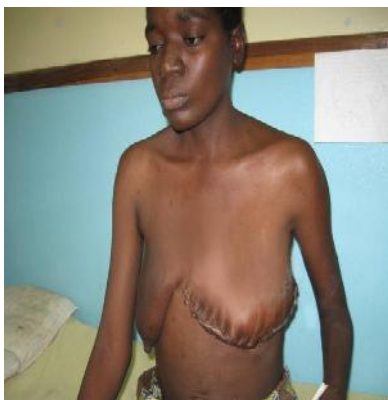

Figure 3

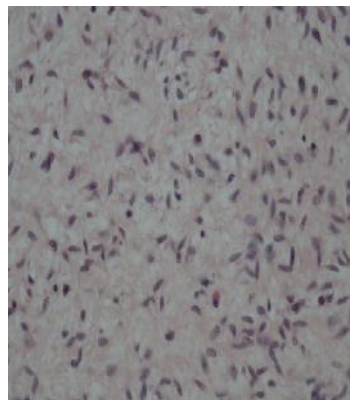


Figure 4

## Discussion

Neurofibromas of the breast are rare. So far we found in the literature, that beside our case, 15 females<sup>2,3,4,5,6,7,8,9</sup> and 5 males<sup>6,10,11,12</sup> with breast neurofibromas were previously reported. The lesions are more commonly solitary than multiple. Macroscopically, neurofibromas appear well circumscribed and if still confined by the epineurium are encapsulated. Most, however, are not encapsulated just as our patient's tumor was not. They vary in size and shape. Typically they are

white-gray tumors as in the current case, but some are brown. They may be polypoid or fusiform in shape.

Histologically neurofibromas contain interlacing bundles of elongated cells with wavy, dark staining nuclei and slender cytoplasmic processes. These cells are arranged loosely and are typically associated with mast cells. Neurofibromas lack epithelial elements. Most are immunoreactive for S-100 protein<sup>9</sup>, typically in some but not all of their component spindle cells. They keep a benign behavior and do not demonstrate a significant mitotic activity.

On mammography, small neurofibromas can appear as well-defined benign masses. They are classically peri-areolar in location. Portions of the outline may be rimmed by air density reflecting their superficial nature, giving a halo. These multiple superficial lesions can mimic and partially obscure deeper breast lesions. On ultrasound they appear as hypoechoic lesions with circumscribed margins with posterior acoustic enhancement resembling a cyst which may result in misdiagnosis<sup>1,9</sup>. MRI examinations could be of help<sup>5</sup>. Due to lack of resources we were unable to do imaging studies.

The primary pathological differential diagnosis for this spindle cell proliferation is neurilemmoma and perineurioma, although malignant phyllodes tumor, malignant peripheral nerve sheath tumor and myofibroblastoma could all be considered. The benign histological as well as the characteristic immunohistological features in our patient, however, are typical for a neurofibroma, especially in the context of the clinical diagnosis of NF1.

The literature<sup>3</sup> states that most breast neurofibromas are small but may range up to 8x6 cm in size except one case in which the neurofibroma of the pectoral region including the breast, reached the size of 25x15x5 cm, and a weight of 2.2 kg. It was confined to the chest wall<sup>7</sup>. In our patient the neurofibroma was 25x15x10 cm, weighed 7kg and reached the knees by stretching the breast tissue. We believe that this is the only reported case of breast neurofibroma of this striking magnitude. Our patient also illustrates a major drawback of some health systems in developing countries. It is a typical case of late presentation of patients seeking medical assistance.

Treatment of neurofibromas is by surgical excision. Breast neurofibromas in general are associated with a low local recurrence rate if completely excised. In our patient cosmesis was difficult to achieve due to the massive size of the tumor, ulceration of the areola and loss of the nipple. Excision of the stretched breast and the mass was done through a semi circular incision. This equalized the size of both breasts.. The patient is scheduled for follow up.

In summary, we described an exceptionally massive but benign breast neurofibroma in a patient with neurofibromatosis type 1, an example of the advanced natural history of diseases seen in low resource nations lacking adequate medical care.

## References

1. Halls SB. Breast neurofibroma. <http://www.breast-cancer.ca/type/breast-neurofibroma.htm> August 2011
2. Narayan AS, Rao KP. Neurofibroma of the breast. *J Indian Med Assoc.* 1968; 50(8):375–6
3. Sherman JE, Smith JW. Neurofibromas of the breast and nipple areolar area. *Ann Plast Surg* 1981; 7:302–7.
4. Fink D, Schneider C, Wight E, Perucchini D, Haller U. Neurofibromatosis of the breast in a patient with morbus von Recklinghausen. *Gynakol Geburtshilfliche Rundsch* 2000; 40:47–9
5. Gokalp G, Hakyemez B, Kizilkaya E, Bursa G. Myxoid neurofibromas of the breast: mammographical, sonographical and MRI appearances. *Br J Radiol* 2007; 80:e234–e7
6. Bongiorno MR, Doukaki S, Arico M. Neurofibromatosis of the nipple-areolar area: a case series. *Journal of medical case report.* 2010; 4:22

7. Laky D, Petrau DM, Anc r V, Kelemen J. Giant neurofibroma of the pectoral region including the breast. Case report. Rom J Morphol Embryol .1990; 36(3-4):213-5
8. Millman SL, Mercado CL. An unusual presentation of neurofibromatosis of the breast. Breast J 2004; 10:45–7.
9. Thompson S, Kaplan SS, Poppiti Jr. RJ, Collado-Mesa F, Rabinovich K. Solitary neurofibroma of the breast. Radiology case reports 2012; 7: No 4
10. Murat A, Kansiz F, Kabakus N, Kazez A, Ozercan R. Neurofibroma of the breast in a boy with neurofibromatosis type 1. Clin Imaging 2004; 28:415–7.
11. Jeyaretna D, Oriolowo A, Smith MFF, Watkins RM. Solitary neurofibroma in the male breast. World journal of surgical oncology 2007; 5:23
12. Hock YL, Mohamid W. Myxoid neurofibroma of the male breast: fine needle aspiration. Cytopathology 1995; 6(1):44-7