

## Manual Colostomy Reversals Following Wide Colorectal Resections at Poorly Equipped Surgical Facilities

E. B.F.K. Odimba, M. Nthele, M Mbambiko

University Teaching Hospital, Lusaka – Zambia

Correspondence to: Prof E. BFK Odimba, E-mail: [Etienne.odimba@yahoo.com](mailto:Etienne.odimba@yahoo.com)

**Background:** The decision for colostomy reversal is usually not easy and often reflects patient's desire, fully analyzed and agreed by the surgeon. The unavailability of mechanical suturing devices considerably increases this challenge. This study was aimed at sharing our experience with manual colostomy reversals (MCR) techniques after wide colorectal resections (WCRR) as well as documenting related early outcomes and complications.

**Methods:** This retrospective study was carried out between 1<sup>st</sup> January 2007 and 31<sup>st</sup> December 2009, at the Lusaka University Teaching Hospital and The Lubumbashi University Clinics. Data were collected from operating lists, clinical records of in-patients and out-patient clinic records. Only fully documented cases with consistent targeted parameters including demography, indication for the colostomy, colostomy type, reversal technique, complications, hospital stay and discharge were considered for statistically analyze.

**Results:** A total of 124 colostomies were performed during the study period; 98 were temporary. Thirty six of these 98 resections were wide and of which the MCR was achieved as follows: simple colon mobilization (56%); additional symphysiotomy (28%), trans-sacral approach (11%) and the use of an ileo-colo-rectal transplant (6%). There was no significant difference in sex and age distribution. Causes of WCRR were: sigmoid colon volvulus (58%); colorectal cancer: (17%); perforated sigmoid diverticulitis (11%), amoebic perforations (18%) and rectal cancer (6%). All 36 patients (100%) got discharged after successful management of the following complications: a faecal fistula in two patients, a surgical abdominal site infection in 3 patients and pelvic pain and discomfort..

**Conclusion:** The MCR after WCRR is feasible in selected and well prepared patients with a perfect technique. Constraints for cancer resections and patient' per operative safety shall be observed. The acquisition of colorectal stapling devices should remain the ideal.

**Key words:** colostomy, colorectal resection, Hartmann technique.

### Introduction

The objective of colostomy is either to temporarily divert faecal matters or to constitute a permanent artificial anus. In the latter, the distal colon is totally excised with the rectum and the anus or is left in place due to advanced disease that makes the resection impossible or dangerous to the patient. In temporary colostomy, the colostomy may follow a wide colorectal resection of which reversal might lead to difficulties like after some Hartmann's colostomy<sup>1, 2</sup>.

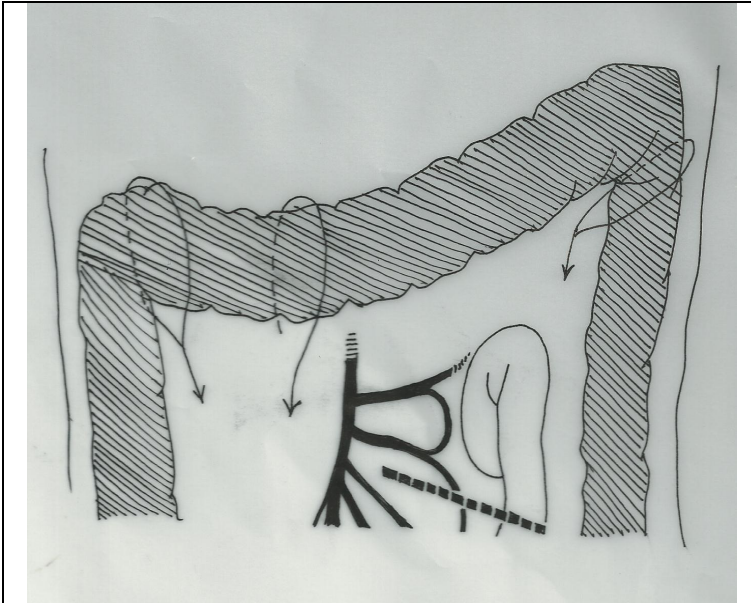
As stated by several authors worldwide the decision for colostomy reversal is usually not easy and often reflects patient's desire, fully analyzed and agreed by the surgeon<sup>1, 3, 4</sup>. The unavailability of mechanical suturing devices (like EEA) considerably increases this challenge. This study was aiming to report utilized manual colostomy reversals (MCR) techniques after wide colorectal resections (WCRR) as well as related early outcomes and complications`

### Patients and Methods

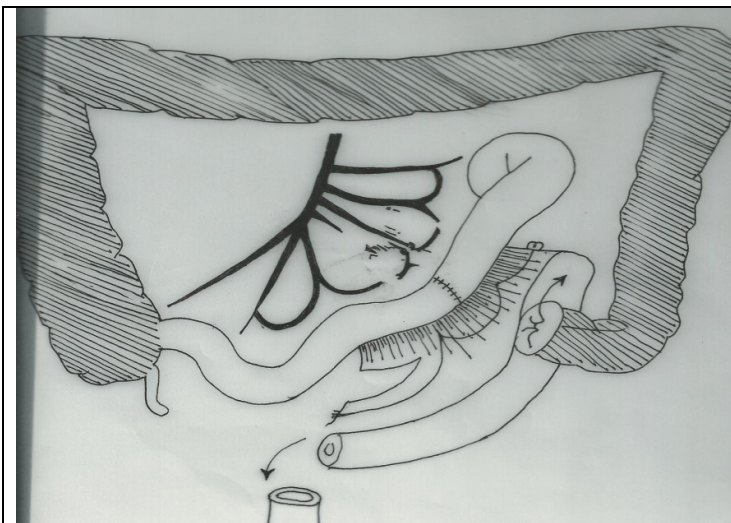
This retrospective study was carried out in two neighbouring departments of surgery of Austral Africa: the University Teaching Hospital, Lusaka (UTH) and the University Clinics, Lubumbashi (CUL), practicing manual colostomy reversals, between 1st January 2007 and 31st December 2009. The study population included all colostomised patients in the two surgical departments. It was a convenient sample size of all colostomies performed during the related period. Wide colorectal

resection (WCRR) was defined as any resection excising at least the colorectal junction. Data were collected from operating theatre lists, from in-wards and out-patient clinic records.

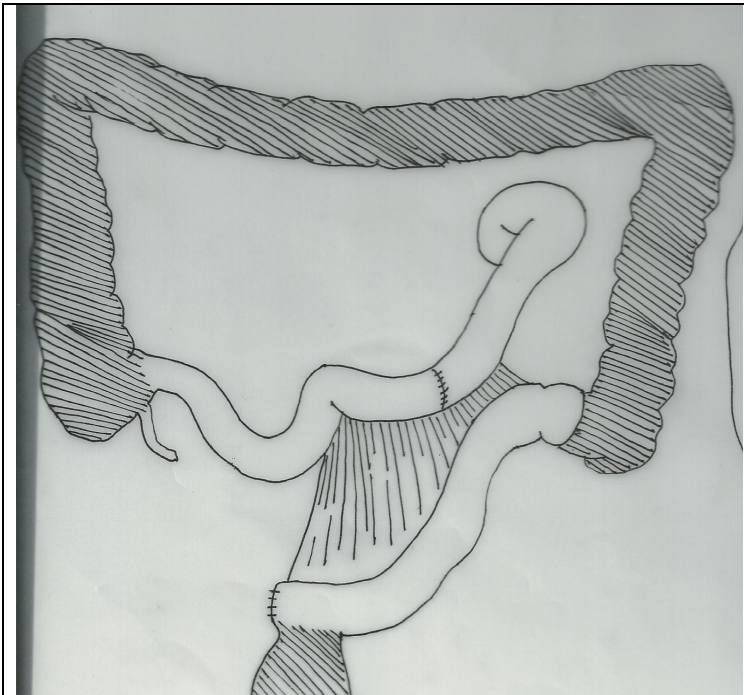
Postoperative complications taken into account were those observed before patients' discharge. Only fully documented cases with consistent targeted parameters namely demography, cause of colostomy, colostomy type, reversal technique, complications, hospital stay and discharge) were considered for statistical analysis of qualitative and quantitative variable. Formal administrative permissions was obtained and strict confidentiality of data was observed.



**Figure 1.** Manual colostomy reversal: colon mobilization from left to right



**Figure 2.** Manual colostomy reversal: ileo-colorectal transplant preparation



**Figure 3.** Manual colostomy reversal: End of ileo-colorectal transplant performance (adapted from Edelmann G. See reference)

## Results

A total of 124 patients underwent colostomy in the two departments of surgery during a period of three years. Out of 124 colostomies, 98 were temporary colostomies, giving a proportion permanent colostomies over temporary of 26/98. 36 of these 98 resections were wide giving 36 wide resections by 98 temporary colostomies (almost one WRCR by 3 temporary colostomies. For these 36 patients, the MCR was achieved as indicated in table I: by colon mobilization (descending colon plus or minor, transverse and ascending colon: see annexes Figures 1), by adding pubic symphysiotomy, by performing an abdominal trans-sacral approach and by the use of an ileo-colo-rectal transplant (Figure 2 and 3).

**Table 1.** Manual Surgical Reversal Techniques in Wide Recto-colic resections

Technique for Reversal	Number (n = 36)	%
Wide Colon mobilization	20	56
Symphysiotomy	10	28
Abdomino-trans-sacral approach	4	11
Ileo-colo-rectal transplant	2	6

Among the 36 patients, there were 19 males (53%) and 17 females (47%). The youngest was 35 years old and the eldest 65 years old with a mean age of 50years. Causes of performed WRCR stood as follows: gangrenous sigmoid colon volvulus: 21(58%); colorectal cancer: 6 (17%); perforated sigmoid colon diverticulitis 4: ( 11%), amoebic perforations of descending and sigmoid colon:3; Rectal cancer :2 (6%) All patients (100%) got discharged from hospitals after 2 to 3 weeks depending of the preformed procedure. A faecal fistula was noted in two patients (6%) after sacral approach that healed after repeated anal dilatations associated with a four-day oral fasting, exclusive intra venous nutrition and antibiotics. A surgical abdominal site infection was observed in 3 patients

(8%). Pelvic pain and discomfort were also observed in postoperative first decade after symphysiotomy and trans- sacral approaches).

## Discussion

In our study, the main cause was sigmoid colon volvulus (gangrenous), followed by colorectal cancer, colorectal perforations (from either diverticulitis or amoebic disease) and rectal cancer. In many Western or European countries the first cause of Hartmann operation is sigmoid colon diverticulitis complicated by perforation, inflammatory pseudo-tumours or by haemorrhage<sup>3, 5, 6</sup>. Hartmann operation is more and more criticized because of its colostomy complications and the difficulties to reverse the colostomy<sup>3,4,7</sup>. One step resection with primary anastomosis is in favour of many surgeons<sup>8,9</sup>. However Hartmann colostomy should keep its place in very weak patients with gangrenous bowel whose it saved life by quickly allowing removal of septic focus and good peritoneal toilet<sup>3</sup> particularly in Chinese stages III and IV<sup>10, 11</sup>

In low rectal cancer, the laparoscopic surgery allows some authors performing laparoscopic low anterior resection<sup>12</sup>. Di Matteo et al (2009) even advocate nerve sparing technique in such surgery of rectal cancer<sup>13</sup>.

### *Rate of reversal after Hartmann operation or wide resection*

We reversed all our 36 WCRR colostomies. This is not the case worldwide even in well equipped countries. In their multicentric study, Dumont et al<sup>3</sup> have a reversal rate of 77.1 %. Almost one patient out of four could not have his colon take down. However it must be noted that their patients were older than those of this study and presented with more co-morbidities. Even with mechanic suturing devices the above mentioned multicentric study<sup>3</sup>. Enumerated causes of no takedown of the colostomy as follows a too high anaesthetic risk, the presence of a non controlled extra colic malignancy, the patient with known previous anal incontinence and the patient who declines the reversal.

### *Techniques of reversal or colon takedown*

The main and common procedure used to take down the colon was the mobilization of the colon. Since a segment of the sigmoid and the descending colons had been cut off during the initial surgery, the mobilization will target the remaining left colon: descending, splenic flexure, transverse colon and sometime the hepatic flexure. Because of the need of mobilization of the splenic flexure, the infra umbilical midline approach initially performed is usually prolonged or extended to a xipho-pubic incision or may include an oblique branch to left inferior costal margin (Barraya incision). The other MCR techniques will be undertaken if the colon mobilization appears insufficient accomplish the reversal.

The adjunction of symphysiotomy is a well known procedure done in some obstructed labours<sup>14</sup>. It has also been performed for excision of some retroperitoneal tumours<sup>15</sup>. It is done by opening the pubic symphysis and pulling left and rightward the two branches using a self retaining retractor. We did not find its use in recent colostomy reversal literature but it has been done in the past by Edelman et al<sup>16</sup>. It is of some interest in the mobilization the rectal stump to perform colorectal anastomosis in a narrow pelvis. The use of symphysiotomy in obstructed labour its complications have been discussed by obstetricians by Ersdal et al in Zimbabwe and Stockholm<sup>15</sup>.

The trans-sacral approach is well known as a technique to treatment of rectal cancer and some infra peritoneal pelvic tumours<sup>15, 16</sup>. It was performed for 4 patients in this series for middle and lower rectum conditions. Many authors confirmed that the abdomino-sacral approach is an important and essential procedure for surgery on a recto-anal lesion. They also noted that the sacral approach had



been applied since the former century and was not well known and encourage more indications abdomino-sacral approach in lower rectal cancer and/or lesions located there because of its advantages such as the improved skin incision and the colo-anal anastomosis. They have also noted the sacral wound dehiscence was a common associated morbidity. The sacral approach in our series was complicated by a fistula that healed with anal dilatations and diet measures

The ileo-colo-rectal transplant has been described in the past by Edemas et al in 1967<sup>16</sup>. It is mainly used to avoid colorectal anastomosis tension and leak in wide pelvis to avoid sacral approach. It consists on interposing a segment of ileum with its pedicle between the colon and the rectum stumps (Figure 2 and 3).

### ***Complications following colostomy reversals***

We came overcame all complications encountered. A part from surgical site infection they were almost procedure related. A surgical abdominal site infection was observed in 3 patients (8%). Pelvic pain and discomfort were also observed in postoperative first decade after symphysiotomy and trans-sacral approaches and a fecal fistula resolved without further surgery after sacral approach.

The following were mentioned in the multicentre study of the 2005. The mortality was nil as in our series. The global hospital morbidity was 13% including postoperative pneumonia, prolonged confusion, prolonged depression status, urine tract infection, burse abdomen, anastomotic leak, and neurological deficit following nerve compression. The hospital stay was of 10 days +/-3. The way of improving for performing modern techniques when available as mechanical suturing laparoscopic surgery meanwhile existing means may be used to assist.

### **Conclusion**

The MCR after WCRR is feasible in selected and well prepared patients with a perfect technique. However constraints for cancer resections and patient' per operative safety shall be observed. The acquisition of colorectal stapling devices should remain the ideal.

### **References**

1. Pearce N.W., Scott S.D., Karran S.J. Timing and method of reversal of Hartmann's procedure Br. J. Surg. 1992; 79: 839-841
2. Khan A.L., Ah-See A.K., Crofts T.J., Heys S.D., Eremin O. Surgical management of the septic complications of diverticular disease Ann. R. Coll. Surg. Engl. 1995; 77: 16-20
3. Dumont F, Vibert E, Duval H, Manaouil D., Sredic A., Alfahel N, Mauvais F. De Fresnoy H., Rudant J., Katsahian S., Riboulot M., Galy C., Verhaeghe P, Dupont H., Regimbeau J.-M Morbimortalité de l'intervention de Hartmann pour péritonite diverticulaire. Étude rétrospective multicentrique à propos de 85 patients. Annales de chirurgie, Volume 130, numéro 6-7, pages 391-399 (juillet-août 2005) Doi : 10.1016/j.anchir.2005.05.005; downloaded in January 2014
4. Desai D.C., Brennan E.J., Reilly J.F., Smink R.D. The utility of the Hartmann procedure Am. J. Surg. 1998; 175: 152-154
5. Vuilleumier H., Nordback P., Givel. J.-C, Traitement actuel de la diverticulite colique Revue Médicale Suisse Revue Médicale Suisse N° 24 publiée le 15/06/2005
6. Odimba BFKE et al.- Péritonites diffuses secondaires à la perforation des sigmoïdites diverticulaires- Une étude rétrospective de 32 cas. Acta chirurgica Belgica 19, 984, 8, pp105-108
7. Maddern G.J., Nejjari Y., Dennison A., Siriser F., Bardoxaglou E., Launois B. Primary anastomosis with transverse colostomy as an alternative to Hartmann's procedure Br. J. Surg. 1995; 82: 170-171

8. Regenet N., Pessaux P., Hennekinne S., Lermite E., Tuech J.J., Brehant O. et al. Primary anastomosis after intraoperative colonic lavage vs. Hartmann's procedure in generalized peritonitis complicating diverticular disease of the colon *Int. J. Colorectal Dis.* 2003; 18 : 503-507
9. Schilling M., Maurer C., Kollmar O., Buchler M. Primary vs. secondary anastomosis after sigmoid colon resection for perforated diverticulitis (Hinchey III and IV): a prospective Outcome and analysis . *Dis. Colon Rectum* 2001 ; 44 : 699-703
10. Owens W.D., Felts J.A., Spitznagel E.L. ASA physical status classifications: a study of consistency of ratings *Anesthesiology* 1978; 49 : 239-243
11. Hinchey E.J., Schaal P.G., Richards G.K. Treatment of perforated diverticular disease of the colon *Adv. Surg.* 1978; 12 : 85-109
12. Komatsu, M.- Laparoscopic Low Anterior resection for Lower Rectal Cancer after Chemoradiation. Japan, 17<sup>th</sup> postgraduate conference of the International Association of Surgeons, Gastro-enterologists and oncologists (IASGO), Athena, 2009, Greece
13. Matteo G.- Nerve-Sparing Technique in Surgery for Rectal Cancer (Italy)-. 17<sup>th</sup> postgraduate conference of the International Association of Surgeons, Gastro-enterologists and oncologists (IASGO), Athena, 2009, Greece
14. Ersdal HL, Verkuyl DAA, Björklund K, Bergström S (2008) Symphysiotomy in Zimbabwe; Postoperative Outcome, Width of the Symphysis Joint, and Knowledge, Attitudes and Practice among Doctors and Midwives. *PLoS ONE* 3(10): e3317. doi:10.1371/journal.pone.0003317
15. Odimba BFK , Mono Broca- Les tumeurs rétro-péritonéales de l'adulte. Rapport des 11 cas et revue de la littérature. *Ann.Chir Paris*, 1982 ; 36 (4) : 263-268
16. Edelmann G .Colostomy Reversal after Colorectal resection. In *EMC Paris*, C-F., 10, 1967 ,40635,
17. Odimba BFK et al.- Side-to-side stapled anastomoses in gastro-intestinal surgery. *East and Central Journal of Surgery*, 1996; 2: 53
18. Schmeizer TM, Hope WW, Lamiti DA, Kerchner KW and Heniford BT.-Laparoscopic colostomy takedown offers advantages over traditional surgery.- *Journal of Minimal Access Surgery*, 2008; December, 2: 200-202