

Oesophageal Foreign Bodies: An Experience with Rigid Oesophagoscopy in a Developing Country.

T.O. Adedeji¹, A. A. Haastrup²

¹Department of Otorhinolaryngology Head and Neck Surgery, LAUTECH Teaching Hospital, Osogbo, Osun state, Nigeria

²Visiting Consultant, Department of Otorhinolaryngology Head and Neck Surgery, LAUTECH Teaching Hospital, Osogbo, Osun state, Nigeria

Correspondence to: Adedeji T.O, E-mail Address adedejitaiwo2003@yahoo.com

Background: This study assessed the procedure of rigid oesophagoscopy for the management of impacted oesophageal FBs.

Methods: A retrospective study of patients between January 2007 and December 2013

Results: There were total of 42 patients consisting of 30 (71.4%) males with male: female ratio 2.5: 1. Majorities (40.5%) were children and over 79% of the patients presented within the first 12 hours. About 60% of the FBs impacted at the upper oesophagus and about 43% had clear radio opaque findings on plain x-ray. Rigid oesophagoscopy and FB removal was successful in 90.5%. Minor complications occurred in 54% and the only case of mortality was due to complication from mismanagement by non Otolaryngologist before referral for specialist care.

Conclusion: Oesophageal foreign bodies are common in our locality with majority of impaction occurring in the upper third of the oesophagus. The management of impacted oesophageal FBs with rigid oesophagoscopy still remains an effective and safe procedure. Prevention, high index of suspicion, early presentation and prompt skillful removal are necessary for a satisfactory outcome

Key words: Oesophageal foreign bodies, Soft tissue radiograph, Rigid oesophagoscopy, Denture impaction, Complications.

Introduction

Foreign body ingestion (deliberate or accidental) forms a major part of emergencies that the Otorhinolaryngologist needs to tackle⁵⁻⁷. The incidence is particularly higher among the children because of their inquisitive nature and the tendency to explore every available cavity in their body ^{2, 4, 5}. Magicians and psychologically unstable patients may be found with some unusual foreign bodies ^{2, 6}. Oesophageal foreign body tends to lodge in the site of natural constrictions or at site of benign or malignant strictures particularly in the elderly¹. A wide variety of foreign bodies that have impacted in the oesophagus have been reported in literature and the incidence and type of FBs are closely related to the nature of the environment in which the patient finds himself ^{4, 7}. While meat bolus and dentures are common in elderly, coins and battery cells are frequently found in pediatric population ^{1, 4 - 6}.

Rigid oesophagoscopy has been a standard method for diagnostic and therapeutic purposes of diseases of the oesophagus such as tissue biopsy, removal of foreign bodies (FBs) and endoscopic dilatation of benign or malignant strictures of the oesophagus¹. Oesophagoscopy is an indispensable part of the practice of the Otolaryngologists all over the world and its development emanated from sword swallowing act ^{7, 8}. The first

endoscopy by Adolph Kussmaul in 1868 used mirrors and a gasoline lamp in a sword swallower⁹. These earlier rigid instruments, with their high rate of perforation have largely been replaced¹⁰. The present day's "rigid oesophagoscopy" was designed by Chevalier Jackson, who broke new grounds in aerodigestive foreign body management⁷.

Oesophageal FB poses a management challenge to the Otorhinolaryngologist and its management modalities depends on anatomic location, shape, nature and size of the foreign body and the duration of impaction^{7, 11}. Although there are various modalities of treatment/extraction of oesophageal FBs reported in literature, but rigid oesophagoscopy remains the best modality^{1, 3}. Serious complications can result in cases of impacted oesophageal foreign bodies due to late diagnosis, late referral to hospital, use of inappropriate instruments and when the surgeon is inexperienced^{5, 7, 12}. Due to morbidity and mortality that can be associated with these complications, every effort should be made to avoid complication during rigid oesophagoscopy^{4, 5, 7}.

Paucity of information on rigid oesophagoscopy in the management of oesophageal foreign bodies in our setting despite the fact that impaction of swallowed foreign bodies constitutes one of the emergencies Otorhinolaryngologist attend in Nigeria⁶ stimulated our interest to embark on this study. This study therefore assessed the procedure of rigid oesophagoscopy for the management of impacted esophageal foreign bodies and evaluates its outcome in a relatively young ENT center in Nigeria.

Patients and Methods

This was a retrospective study of patients who were managed with rigid oesophagoscopy on account of oesophageal foreign bodies at the department of Otorhinolaryngology, Ladoke Akintola University of Technology Teaching Hospital, Osogbo, Osun State, Nigeria between January 2007 and December 2013. The medical records of the patients were retrieved from the case notes through the medical records department of the hospital. Data generated with retrieval of information which included patients' age, sex, symptoms at presentation, occupation, type and mode of foreign body impaction, duration of symptoms before presentation elicited clinical signs, radiographic findings, level of FBs impaction in the oesophagus, status of the esophageal mucosa after FB extraction, outcome of intervention, duration of hospital stay after surgical intervention, and final outcome. Excluded were patients whose case records could not be located and those that had missing significant and vital information

The information was entered into a spread sheet and the data generated was analysed using SPSS version 14 (Chicago, IL). The data was presented in simple descriptive forms as proportions using tables and graphic chart.

Results

There are total of 113 patients with pharyngo-oesophageal foreign bodies out of which 49 were oesophageal FBs who had rigid oesophagoscopy but only 42 patients had complete data for analysis consisting of 30 (71.4%) males and 12 (28.6%) female with male: female ratio 2.5: 1. The age of the patients ranged from 9 months to 75 years (mean 28.5 ± 24.0 years. Majorities (40.5%) were children (9 months – 15 years) and age group 61 years and above were the least (9.5%). Table 1 shows the age distribution

and the type of FBs among the age groups. Occupation distribution shows that majority of the patients 20 (47.6%) were students/ dependants, farmers 7 (16.7%), traders 6 (14.3%), civil servants 4 (9.5%) and others 5 (11.9%). All the patients presented as an emergency, majority (79.5%) of them presented within the first 12 hours and only 5.1% presented after the first 24 hours. They presented with history of FB ingestion, dysphagia, odynophagia and drooling of saliva (Table 2).

Table 1. Age distributions and type of FBs among the patients

Age (Yrs)	Type and Number of Foreign Bodies	Total	%
0.5 – 5	Screw/Nail = 3, Batteries = 3, Fish bone=3, coin = 2, Others = 1	12	28.5
6 – 15	Metals/Nail = 2, Plastic =2, Fish bone = 1	5	11.9
16 – 30	Nail/Needle = 3, Fish bone = 3, Plastic = 1	7	16.7
31 – 45	Denture = 4, Others = 2	6	14.3
46 – 60	Denture = 5, Meat = 1	6	14.3
≥ 61	Denture = 2, Bones = 2, Meat = 1, Kola nut = 1	6	14.3
Total		42	100

Table 2. Site of impaction, radiological findings and symptoms at each site

Site of impaction	Radiological findings			Total
	Opacity	Air entrapment	Increased prevertebral soft tissue	
Below the cricopharyngeus	4	5	1	10
Upper (cervical) oesophagus	10	8	7	25
Middle (thoracic) oesophagus	3	1	1	5
Lower oesophagus	1	1	-	2
Total	18	15	9	42

All the patients had plain soft tissue radiograph while 7 patients had additional barium swallow either to further aid in localizing the site of impaction or to rule out underline pathology in the oesophagus. Only 18 (42.9%) had clear radio opaque findings on plain x-ray. Majority (59.5%) of the FBs were impacted at the cervical (upper 1/3) oesophagus. Table 2 shows the plain X-ray findings and Table 3, shows site of impaction and symptoms at presentation while Table 4 compares the spectrum of FBs in the present study with the findings from the previous published studies in Nigeria.

Table 3. Site of Impaction of FB in Relation to Presenting Symptoms

Site of impaction	Symptoms at each site
Below the cricopharyngeus	throat pain, drooling of saliva, odynophagia, dysphagia
Upper (cervical) oesophagus	throat pain, drooling of saliva, odynophagia, dysphagia
Middle (thoracic) oesophagus	FB ingestion, dysphagia, neck pain/swelling
Lower oesophagus	FB ingestion

Table 4. Spectrum of FBs in the present study compare with the findings from the previous studies

Nature of FBs	Frequencies No (%)				
	Okeowo ¹⁴ (1985)	Ahmad ¹⁰ (2001)	Salisu ¹³ (2011)	Onotai ¹ (2012)	Present study(2014)
Coin	128 (69.9)	54 (68.4)	-	5 (7.14)	2 (4.8)
Denture	4 (2.2)	1(1.3)	7 (43.75)	10 (14.23)	11 (26.2)
Needle/nails/metal	3 (1.6)	3 (3.8)	5 (31.25)	11 (15.72)	8 (19.0)
Bone	28 (15.3)	14 (17.7)	2 (12.5)	18 (25.71)	9 (21.4)
Toy/plastic	-	-	-	7 (10.0)	3 (7.1)
Meat	1 (0.5)	3 (3.8)	2 (12.5)	9 (12.86)	2 (4.8)
Battery	-	-	-	-	3 (7.1)
Kola nut	15 (8.2)	-	-	-	1 (2.4)
Others	5 (2.7)	4 (5.0)	-	4 (5.71)	3 (7.1)
Total	183 (100)	79 (100)	16 (100)	70 (100)	42 (100)

Dentures were the most common (26.2%) FBs followed by bones (21.4%). All the impacted dentures occurred in the adult, majority (72.7%) of these occurred among farmers (45.4%) and traders (27.3%) while coins and cell battery were found among the children ≤ 5 years ($X^2 = 42.2$, $p < 0.001$). Rigid oesophagoscopy and FB removal was successful in 38 (90.5%) while in 3 (7.1%) patients; FBs have passed down into the stomach, they were followed up with serial plain radiograph and were subsequently passed out with faeces and 1 patient discharged against medical advice. Figure 1 shows the duration on admission while Figure 2 shows the type of FBs and the associated complications following rigid oesophagoscopy, most of the complications were managed conservatively with nasogastric tube, antibiotics and analgesics. The only case of mortality was due to mismanagement by quack that had perforated the oesophagus before referral for specialist care.

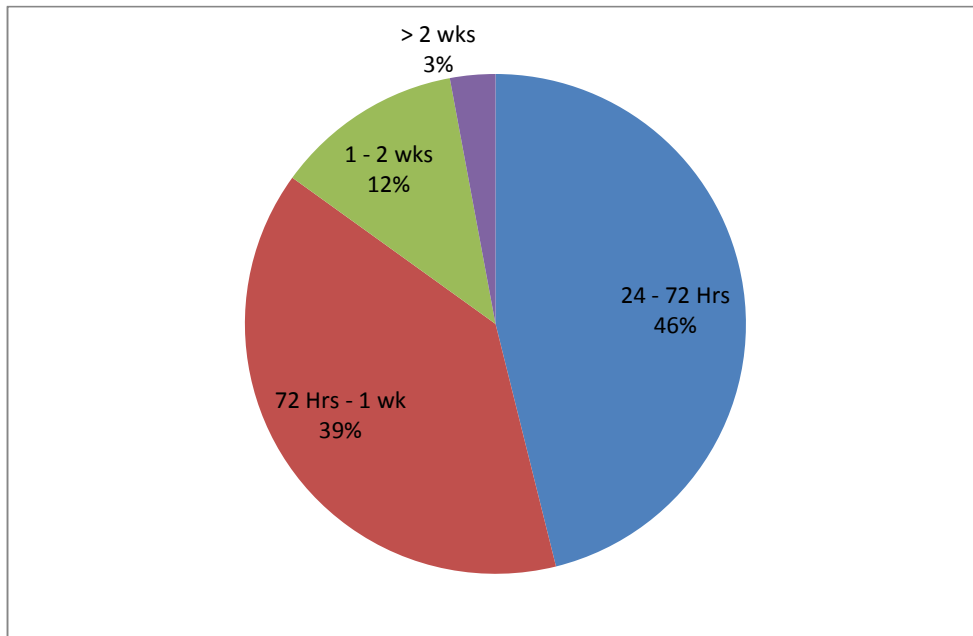


Figure 1. Duration on admission.

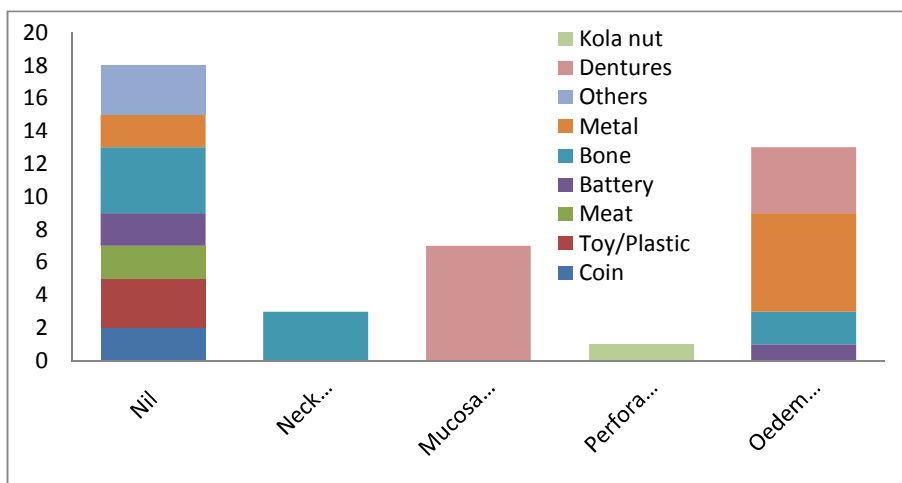


Figure 2. Complications and the associated type of FBs following rigid oesophagoscopy.

NB: The only case of perforation from kola nut was iatrogenic from mismanagement by non Otolaryngologist.

Discussion

Oesophageal foreign body is one of the urgent clinical conditions that are frequently encountered in otolaryngology practice. Early presentation, diagnosis and accurate treatment are vital to prevent complications¹⁶. Although various modality of extraction

like fibre-optic flexible oesophagoscopy, Foley's catheter, digestive enzymes, glucagon, atropine, magnets and forceps have been employed; but rigid oesophagoscopy under general anaesthesia is regarded as the preferred method of removal^{1, 4, 15}. Türkyilmaz et al in Turkey opined that rigid endoscopy is an effective and safe procedure for oesophageal foreign body removal¹⁶.

The preponderance of the disease in the male gender supported by 71.4% prevalence among the male in the present study agreed with the findings from the previous published studies^{1, 13}. Male preponderance can be associated with high level of activity, restlessness and inquisitiveness especially among the children. As seen in the present studies and in agreement with the findings of previous researcher, majority of foreign body ingestions usually occur in the paediatric population^{1, 4, 17, 18}. Uba et al⁵ reported that retained oesophageal foreign body is a common childhood health hazard and that early diagnosis and prompt skillful removal are necessary for a satisfactory outcome. A similar study from Ghana reported that FB ingestion is perhaps the commonest paediatric emergency and that the exact rate of occurrence may never be known because many are not reported especially in rural communities⁴. The contributing factor may be due to the care free attitude of some parents/guardians. The availability of some of these materials in various homes which are either displayed recklessly, or used as toy by the children or as a means of pacifying these children who are in their explorative stage. Indiscriminate access to such materials predisposes such children to oesophageal FB impaction. Published studies from Sokoto, Nigeria reported that 'the vulnerability of children to otorhinolaryngeal foreign bodies was among other reasons due to curiosity, boredom, and the wish to explore the orifices of the body and that oesophageal foreign bodies decreases with increasing age^{19, 20}. It is therefore necessary for parents and caregivers to have high index of suspicion, monitor their children intimately and also remove potential FBs from the environment to prevent occurrence of such impaction.

About 95% of our patients presented within the first 24 hours of FB impaction in the oesophagus. Similar studies from Kano and Sokoto in Nigeria have reported 80% – 94 % of early presentation to health facility of patient with oesophageal FBs¹³. Presentation of foreign body impaction in the throat is often dramatic due to dysphagia and or drooling of saliva which may be a source of apprehension to the patient^{2, 11}. This may be responsible for early presentation in majority of our patients. A study from Port Harcourt however reported late presentation of most of their patients usually after 72 hours of the incident⁷. Delayed presentation was reported to be an outstanding factor that determines the prognosis of patients with impacted foreign bodies^{2, 7, 13, 21}.

Although plain radiographs remains the most basic investigation for patients with suspected impacted oesophageal FBs, radiological diagnosis of oesophageal foreign bodies require experience. In the present study, only 42.9% of our patients had the radiographic confirmation of radio-opaque FBs while others only had tell tale signs in form of air trapping or increased prevertebral soft tissues. This finding was similar to those reported by other researchers^{7, 11}. Salisu et al¹³ reported that tale-tell signs such as air trapping, straightening of cervical spine and tracheal compression give a rough guide regarding the site of oesophageal FB impaction. Onotai et al⁷ opined that although the radiographic diagnosis of FB impaction in the oesophagus was very useful, it cannot

be relied upon solely because some foreign bodies may not be visible and such radiolucent materials that are lodged in the oesophagus may pose diagnostic challenge and give false negative results. Other studies had reported sensitivity and specificity of radiologic diagnosis and localization in cases of oesophageal FB impaction to range between 39 – 55% and 72 – 100% respectively for plain radiograph^{11, 22, 23}. The use of barium (a contrast material) to aid localization of level of impaction in cases that were not clear as was found in 16.7% of our patients was similar to report from other previous studies^{24, 25}.

Although there are three anatomic areas of constriction, usually the first area of constriction in the upper third of the oesophagus just below the cricopharyngeal junction is the most common site of impaction. This is consistent with the findings in the present study where 83.3% of impaction occurred at the cricopharyngeal and upper oesophageal region. This was similar to the report of Onotai in Port Harcourt where 85.7% of impaction occurred at the upper oesophagus⁷. Other published studies had reported 62% - 75% of oesophageal FB impaction at the upper oesophagus^{4, 13, 20}.

Although the present study focused on oesophageal FBs, our findings shows some differences in the proportions of various FBs when compared with the previous published studies in the same region or within the country as a whole. While coin was the major Fbs implicated in the previous studies constituting 68 – 70% of the proportions of impacted FBs^{6, 14}, the present study and other recent published studies had demonstrated a sharp decline or disappearance of coin from the spectrum of impacted Fbs in the oesophagus^{7, 13, 19}. The reason may be due to the fact that coins are no longer accepted universally as a means of exchange in Nigeria in contrast to what obtained few decades ago. Amutta in Sokoto, North western Nigeria opined that absence of coin in their study could be due to non availability of coins again in Nigeria because of its low value as a result of inflation and the conversion of coin to paper currency¹⁹. There is however emergence of other forms of oesophageal FBs, for instance cell batteries and dentures are now becoming commonly implicated among the spectrum of extracted oesophageal FBs in Nigeria^{7, 13}.

While denture impaction was rare about 2 decades ago in Nigeria^{6, 14}, it has constituted the preponderance of oesophageal FBs as seen in the present study (26%) and supported by other recent studies (14 – 43%)^{7, 13}. This may be due to increasing desire to restore functions and aesthesis following dental loss leading to an increase in the number of people wearing dentures with its consequence of proportionate increase in the incidence of esophageal impacted dentures^{26, 27}. Other factors responsible might be due to ignorance, poverty, carelessness in handling the dentures and failure to present for routine medical checkup even when the denture is loose or shaking. Apart from denture impaction that occurs exclusively among the adults as seen in this study, true foreign body ingestion among the adults occurs more commonly among those with psychiatric disorders, unconscious patients, mental retardation or impairment caused by alcohol, and those seeking some secondary gain^{11, 19, 24, 28}. Although none of our patients had history suggestive of psychiatric illness, one of them however ingested cola for money making ritual purposes. Akenroye et al² reported about uncommon and undeclared oesophageal foreign bodies that were impacted in the oesophagus following magical and ritual purposes.

Some other studies outside our country however still reported coins as the predominantly encountered oesophageal FBs^{1, 16}. Asif et al²⁹ in Pakistan reported 56% prevalence of coin in their study, Turkeyilmaz et al¹⁶ in Turkey reported coin as the most preponderant FB in their report while in Asia, where fish is a common staple diet, fish bone is the most common foreign body in the esophagus¹. Peter et al⁴ in Ghana reported fish bone as the leading cause (44.6%) of oesophageal FBs followed by coin (33.2%). This underscores the facts that the incidence and type of oesophageal FBs are closely related to the nature of the environment in which the patient finds himself/ herself and the prevailing socioeconomic situations in such area^{4, 7, 19}.

Successful removal of FBs by rigid oesophagoscopy in 90.5% of the patients in the present study was comparable to the previous published report^{1, 7, 29}. A similar study in Pakistan reported successful removal of FBs with rigid oesophagoscopy in 95.28% of the patients¹. Hussain et al³⁰ documented that foreign body were removed successfully with rigid endoscopy as the main treatment modality under general anesthesia in 87.8% of patients while other researchers reported 90 – 93 % successful removal of FBs with rigid oesophagoscopy without complication^{31, 32}. Appropriate/ proper choice of the instruments and surgeon's proficiency are the necessary requirement to prevent complications and for successful removal⁷. Early presentation, prompt diagnosis and skillful removal are other necessary requirement for a satisfactory outcome^{26 - 29}.

Extraction of difficult and complicated cases via transcervical or transthoracic oesophagotomy had been reported but none of our patients had any of such procedures⁷.

Gmeiner et al³³ compared rigid with flexible oesophagoscopy in the management of oesophageal FBs and concluded that due to lower rate of severe complications, better patient comfort with a lower rate of dysphagia, and lack of requirement for general anesthesia, flexible oesophagoscopy should be the first line approach to FBs removal and that rigid oesophagoscopy should be considered for second line therapy. Pino et al³⁴ in Spain also reported that the number of procedures of rigid oesophagoscopy has decreased to a great extent because of flexible endoscopy which is the first choice technique and that only less than 15% of FB extraction requires a rigid oesophagoscopy in there center. The spectrum of Fbs in our locality where sharps objects like dentures, bones, nails and metals constituted the predominant objects might be difficult to manage with flexible endoscope. Hence rigid oesophagoscopy still remain the first line therapy for most of our patients. Onotai et al⁷ opined that rigid oesophagoscopy is particularly important in the extraction of sharp and pointed foreign bodies like nails and dentures and that such extraction requires special attention and expertise.

Spontaneous expulsion as it occurred in 7.1% of our patients agreed with findings of previous published studies^{19, 29, 30}. Such occurrences however occur sporadically and do not justify expectant, watchful or conservative management especially in an environment where sharp, large and rigid FBs like dentures form the greater proportion of the spectrum of impacted FBs. Expectant/ conservative management is also contraindicated in cases of cell batteries due to its corrosive tendencies.

Various complications seen in this study were similar to the report of previous researchers^{19, 29, 33}. Complication can result from the impacted FBs especially if presentation is delayed or iatrogenic from surgical maneuver during extraction³⁵. Although every precaution was made to avoid complications, some of these complications like mucosa oedema and laceration were inevitable as some voluminous object like dentures could not be effectively manipulated and placed inside the lumen of the wider rigid oesophagoscope during extraction. We gently brought such voluminous FBs out along with the rigid oesophagoscope causing some mucosal lacerations and oedema.

In some of unorthodox medical facilities, unconventional maneuvers and manipulations are done often without success, only for the patients to present to the Otolaryngologists after complications had set in. This was the scenario in only case of oesophageal perforation which subsequently died in the present study. The affected patient had swallowed cola for ritual purposes following which attempted dislodgement was made to push the FB down into his stomach without appropriate instrument and illumination. He only presented following oesophageal perforation and mediastinitis. There is therefore, a need for serious public enlightenment and education to eradicate or minimized this avoidable morbidity and mortality.

There are some limitations in this study; a hospital-based study may not completely capture what obtains in the community. The retrospective nature with its inherent problems including incomplete and loss of information is also noted. Furthermore, the lack of comparative analysis in the distribution of the FBs between different age groupings, different sites/region, is also admitted a limitation.

Conclusion

Oesophageal foreign bodies are common especially among children with majority of impaction occurring in the upper third of the oesophagus. The management of impacted esophageal foreign bodies with rigid oesophagoscopy still remains an effective and safe procedure in our environment despite its challenges. Prevention, high index of suspicion, early presentation, diagnosis and prompt skillful removal are necessary for a satisfactory outcome

Acknowledgement

The authors acknowledge Dr Jimoh, a resident in the department that collated the data as well as other consultants that allow their patients to be included in the study.

References

1. Hussain G, Iqbal M, Ihsanullah, Hussain M, Ali S. Esophageal Foreign Bodies: An Experience with Rigid Esophagoscope. *Gomal J Med Sci.* 2010; 8(2) 218 - 220
2. Akenroye M I, Osukoya A T. Uncommon, undeclared oesophageal foreign bodies. *Niger J Clin Pract* 2012; 15:244-6.
3. Onotai LO, Ebong EJ. Impacted fishing hook in the upper cervical esophagus of two Nigerians: Case reports. *J Med. Med. Sci.* 2012; 3(6): 265 – 270.

4. Peter A, Mohammed DI. Pattern of Foreign Bodies in the Throat. *Journal of Natural Sciences Research* 2012; 2 (4): 8 – 12.
5. Uba AF, Sowande AO, Amusa YB, Ogundoyin OO, Chinda JY, Adeyemo AO, Adejuyigbe O. Management of oesophageal foreign bodies in children. *East Afr Med J.* 2002; 79(6):334-8.
6. Ahmad BM, Dogo D, Abubakar Y. Pharyngo-oesophageal Foreign Bodies in Maiduguri The Nigerian Journal of Surgical Research 2001; 3 (2): 62 – 65
7. Onotai LO, Etawo US. The Challenges of Rigid esophagoscopy in the management of esophageal foreign bodies in Port Harcourt. *Int. J. Med. Med. Sci.* 2012; 2 (5): 108-113
8. Brian WB, Meyer D. Sword swallowing and its side effects. *BMJ* 2006; 333:1285. doi: <http://dx.doi.org/10.1136/bmj.39027.676690.55>
9. Huizinga E. On oesophagoscopy and sword-swallowing. *Ann Otol Rhinol Laryngol* 1969; 78:32-9.
10. Kubba H, Spinou E, Brown D. Is same-day discharge suitable following rigid esophagoscopy? *Ear Nose Throat J* 2003; 82:33-6.
11. Segun-Busari S, Afolabi OA, Alabi BS, Adebola SO. Multiple oesophageal coin-like foreign bodies appearing like one: A caution for otorhinolaryngologist *Int. J. Med. Med. Sci.* 2013; 5(6) 247 – 250. DOI: 10.5897/IJMMS09.395
12. Orji FT, Akpeh JO, Okolugbo NE. Management of esophageal foreign bodies: experience in a developing country. *World. J. Surg.* 2012; 36(5):1083-1088.
13. Salisu A. Sharp and Irregularly Shaped Esophageal Foreign Bodies: Outcome of Endoscopic Extraction in Kano *BOMJ* 2011; 8 (1): 1 – 4
14. Okeowo PA. Foreign bodies in the pharynx and oesophagus. A ten years review of patients seen in Lagos. *Nigerian Quart J Hosp Med* 1985; 3:46-50.
15. Sittirai P, Pattarasakulchai T and Tapatiwong H. Esophageal foreign bodies. *J. Med. Assoc. Thai.* 2000;83(12):1514-1518.
16. Türkyilmaz A, Aydin Y, Yilmaz O, Aslan S, Eroğlu A, Karaoğlu N. Esophageal foreign bodies: analysis of 188 cases. *Ulus Travma Acil Cerrahi Derg.* 2009; 15(3):222-7.
17. Cheng W, Tam PK. Foreign-body ingestion in children in children: experience with 1265 cases. *J Pediatr Surg* 1999; 34: 1472-6.
18. Panieri E, Bass DH. The management of ingested foreign bodies in children-a review of 663 cases. *Eur J Emerg Med* 1995; 2:83-7.
19. Amutta SB, Iseh KR, Aliyu D, Abdullahi M, Abdulrahman GA. Ear, nose, and throat foreign bodies in a tertiary health institution in Sokoto, Nigeria. *Sahel Med J* 2013;16:87-92
20. Iseh KR, Oyedepo O, Aliyu D. Pharyngo-oesophageal foreign bodies: Implication for health care services in Nigeria. *Ann Afr Med* 2006; 5:52-5.
21. Muir AD, White J, McGuigan JA, McManus KG, Graham AN. Treatment and outcomes of esophageal perforation in a tertiary referral centre. *Eur J Cardiothorac Surg* 2003; 23(5): 799-804.
22. . Lue AJ, Fang WD, Manolidis S. Use of plain radiography and computed tomography to identify fish bone foreign bodies. *Otolaryngol. Head Neck Surg.* 2000; 123:435-8.
23. Akazawa Y, Watanabe S, Nobukiyo S, Iwatake H, Seki Y, Umehara T, Tsutsumi K, Koizuka I/ The management of possible fishbone ingestion. *Auris Nasus Larynx.* 2004; 31(4):413-416.

24. Hashmi S, Walter J, Smith W, Latis S. Swallowed partial dentures. J R Soc Med. 2004; 97(2): 72-75.
25. Agrawal D, Lahiri TK, Parmar A, Sharma S. Swallowed Partial Dentures. Indian J dent Sc. 2012; 4(2): 7 - 12
26. Akinpelu OV, Amusa YB, Eziyi JA, Haastrup AA, Ameye SA. Oesophageal denture impaction producing Horner's syndrome: a case report. J Laryngol Otol. 2007; 121(9):e17. Epub 2007 Jul 12
27. Tihan D, Trabulus D, Altunkay A , Karaca S, Cihan A, Aliş H. Esophageal perforation due to inadvertent swallowing of a dental prosthesis. Turk J Gastroenterol 2011; 22 (5): 529-533
28. Parameswari R, Musthafa S, Pappachan JM, Babu A, Thanath JK, Parackal S. Acquired tracheo-esophageal fistula caused by a denture. India J Surg 2007; 69(1): 19 – 21
29. Asif M, Haroon T, Khan Z, Muhammad R, Malik S, Khan F. Foreign body esophagus: types and site of impaction. Gomal J Med Sci 2013; 11(2): 163-6.
30. Hussain G, Iqbal M, Ihsanullah, Hussain M, Ali S. Esophageal foreign bodies: an experience with rigid esophagoscope. Gomal J Med Sci 2010; 8: 218-20.
31. Gilyoma JM, Chalya PL. Endoscopic procedures for removal of foreign bodies of the aerodigestive tract: The Bugando Medical Centre experience. BMC, Ear, Nose and Throat Disorders 2011; 11: 2-5.
32. Saki N, Nikakhlagh S, Safai F, Peyvasteh M. Esophageal foreign bodies in children. Pak J Med Sci 2007; 23: 854-6.
33. Gmeiner D, Rahden B H A, Mecoc C, Hutter J, Oberascher G, Stein H J. Flexible versus rigid endoscopy for treatment of foreign body impaction in the esophagus. Surgical Endoscopy. 2007; 21(11):20 – 26
34. Pino RV, Trinidad RG, Marcos GM, Pardo RG, González PA, Blasco HA. Esophagoscopy in adults: Our experience and review of the literature]. Acta Otorrinolaringol Esp. 2003; 54(9):642-5.
35. Morales-Angulo C, Rodríguez IJ, Mazón GA, Rubio SA, Rama J. Diagnosis and treatment of cervical esophageal perforation in adults. Acta Otorrinolaringol Esp. 1999; 50(2):142-6