

Favourable Outcome After Resection for Contained Malignant Colorectal Perforation

T E Madiba

Colorectal Unit, Department of Surgery, University of KwaZulu-Natal and Inkosi Albert Luthuli Central Hospital, Durban.

Presented at the World Surgical Congress of the International Surgical Society in Helsinki, Finland on 25-29 August 2013.

Correspondence to: Professor T E Madiba, E-mail: madiba@ukzn.ac.za

Background: Perforation in colorectal cancer occurs due to direct perforation from or from proximal colon rupture. This study was aimed at documenting our experience with malignant colorectal perforation and to establish trends in presentation. Analysis of ongoing database of all patients with colorectal cancer in the KwaZulu-Natal State Hospitals established since 2000 was undertaken. The Setting was the Colorectal Unit in a tertiary centre

Patients: All patients with malignant perforation were extracted from the database and analyzed. Data collected included demographics, presentation, treatment, outcome, and follow-up. The main outcome measure was the In-hospital mortality

Results: By the end of 2012, the database was then comprised 1425 patients, of whom 48 (3.4%) were found to have malignant perforation. The Male-to-female sex ratio was 1:1, and age (mean \pm SD) was 54.5 ± 15.6 years. Perforation occurred in 3%, 2%, 4%, and 5% of Africans, Indians, Coloureds, and Whites respectively. The disease distribution was right colon (15), descending colon (5), hepatic flexure (1), sigmoid (21), and rectum (6). Twelve patients with intestinal obstruction required emergency resection (25%). The rest underwent elective resection with the perforation discovered either at operation or at histopathologic analysis. One, 19, 23, 5 patients had Stage I, II, III, and IV respectively. There was no postoperative mortality. Only 6 patients had early disease and were deemed not to require adjunctive or palliative therapy. Patients were followed up for 14.6 ± 19 (range 1-94) months. Seven patients were lost to follow up, and two are confirmed dead. Up to now four of the 39 evaluable patients have developed metastases.

Limitation: Inadequate follow-up data

Conclusion: Malignant perforation occurs in about 3% of colorectal cancers in our geographical area of Southern Africa. The sex distribution and prevalence is the same in all population groups. Disease distribution follows general norms. Interestingly the perforation rarely leads to peritonitis. There was no postoperative mortality in this cohort.

Keywords: colorectal cancer, malignant perforation, Hartmann's procedure, emergency colectomy, South Africa.

Introduction

Carcinoma of the colon and rectum accounts for about 1.2 million new cases worldwide¹, and it is the third most common cancer in men and second most common in women. Colorectal cancer ranks second in terms of both incidence and mortality in more developed countries such as the USA². While this cancer is estimated to account for 9.4% of all cancers worldwide, it appears to account for only 2.5% of all cancers in Africa³.

Up to 30% of patients with colorectal carcinoma present with complications, the most common being obstruction and perforation⁴⁻⁸, of which 2-10% are due to perforated colorectal cancer⁹⁻¹¹. Perforation in colorectal cancer occurs due to either direct perforation from tumour necrosis or from proximal colon rupture or blow-out from an obstructed tumour and a competent ileo-caecal valve producing a closed-loop obstruction¹⁰⁻¹². Greater morbidity and

mortality have been reported for perforated colorectal cancer^{5, 6, 10, 13}. The criticism of these previous studies is that they did not clearly describe the mechanism of perforation namely free vs contained or perforation at the tumour site vs proximal perforation¹⁰. There are few, if any, studies specifically dedicated to contained colorectal perforation. The author hypothesized that, when considered in isolation, contained perforation of colorectal cancer has a favourable outcome and that the previously quoted high mortality may have been due to the failure to differentiate between contained and free perforation.

The aim of this study was to establish clinicopathological trends in patients with contained malignant perforation of colorectal carcinoma and to document outcome in our geographic setting. The main outcome measure was in-hospital mortality.

Patients and Methods

The colorectal cancer database in the KwaZulu-Natal Province was established in 2000 and is still on-going¹⁴. All patients with colorectal carcinoma attending all KwaZulu-Natal Hospitals are referred to the Colorectal Unit at Inkosi Albert Luthuli Central Hospital where they are seen in the Multidisciplinary Clinic. All patients with pathologically proven malignant perforation were extracted from the database at the end of 13 years and analyzed. Data collected included demographics, presentation, staging, treatment, outcome, and follow-up. For the purposes of this study, the UICC staging was used.

Diagnosis of perforation was made either on the basis of gross operative findings and confirmed by histology or entirely on pathologic review and histopathology. A free perforation was defined as a perforation into the peritoneum with localized or generalized peritonitis. A contained perforation occurred into a confined space localized by peritoneum, omentum, or bowel. Data were collected on a dedicated proforma. Data were analyzed using Ms-Excel, in which different ethnic groups were compared. Continuous data are presented either as mean and standard deviation or median values (range). One way analysis of variance (ANOVA) was used to compare ages of the different population groups.

Ethical approval was obtained from the Biomedical Research Ethics Committee of the University of KwaZulu-Natal.

Results

At the end of 2012, the database comprised 1425 patients (495 Africans, 569 Indians, 64, Coloureds and 297 Whites). Of these 48 were found to have malignant perforation (3.4%) comprising patients of African (16), Indian (15), Coloured (2), and White (15). There were 24 males and 24 females. Mean age at presentation was 54.1 ± 15.1 years. The median age (range) was 40.5 (19-68), 56 (38-73), 56.5 (54 - 59), and 66 (39-82) years for Africans, Indians, Coloureds and Whites respectively. The age of presentation tended to be less in patients of African descent (African vs White, $p < 0.0001$, Indian vs Coloured vs White, $p = \text{NS}$). Clinical manifestations included abdominal pain (19), abdominal distension (12), change in bowel habit (12), loss of weight (7), abdominal mass (6), rectal bleeding (5), vomiting (5), and loss of appetite (5).

Procedures undertaken are shown in Table I. The perforation occurred at the site of the tumour and was contained in all; none of the patients presented with localized or generalized peritonitis. The most common site of perforation was the sigmoid colon (21) followed by the right colon (15), rectum (6) descending colon (5), and hepatic flexure (1). Twelve patients (25%) presented with colonic obstruction and the perforation was discovered at the time of emergency resection. The rest of the patients underwent elective surgery with the perforation discovered either at operation or on pathologic analysis.

The majority presented as stages II (19, 40%) and III (23, 48%). Only 5 presented as stage IV (10%) and one as stage I (2%). Figure 1 shows the comparison of staging for the perforated tumours and the entire cohort of 1425 patients. Of the perforated cancers, 45 patients had moderately differentiated carcinoma, while one each had mucinous, poor, and undifferentiated carcinoma. No patient had peritoneal carcinomatosis or peritoneal metastases. Three patients had a resection with residual microscopic disease (R-1 resection) at the circumferential margin (6.4%). All proximal and distal margins were free of tumour. There was no postoperative mortality.

Six patients did not present for treatment at the Oncology Clinic and have been lost to follow-up. Six other patients were deemed not to require adjunctive or palliative therapy because of good prognostic features. The rest received adjuvant chemotherapy. Patients were followed for 14.6 \pm 19 months. Two patients have been confirmed dead due to disease progression. Four of the other 34 patients have developed metastases to date.

Table 1. Procedures Undertaken in 47 Patients with Colorectal Cancer Perforation.

Procedure	No	%
Sigmoid colectomy	18	38
Right hemicolectomy	15	30
Left hemicolectomy	4	9
Anterior resection	4	9
Subtotal colectomy	3	6
Abdomino-perineal resection	2	4
Extended right hemicolectomy	1	2
Extended left hemicolectomy	1	2

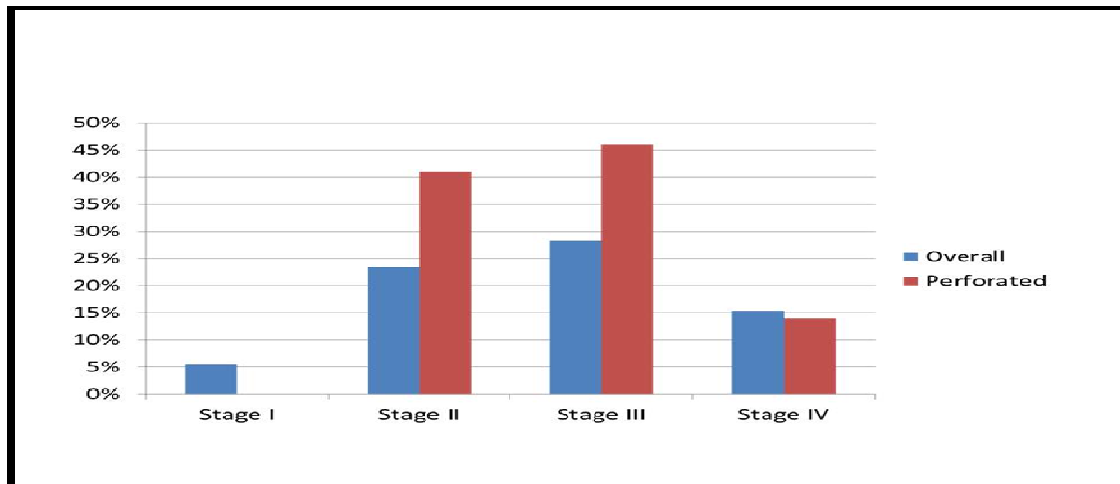


Figure 1. Comparing the age distribution of patients with contained perforation compared to all patients with colorectal cancer.

Discussion

This study demonstrated that contained neoplastic perforation occurred in 3% of patients with colorectal cancer with no peritonitis confirmed at the time of surgery and no in-hospital mortality. This rate falls within the 2.6 – 10% reported in the literature^{5, 9-12, 15}. Only 27% required emergency operation because of associated malignant large bowel obstruction.

The mean age of 55 years noted in this series is considerably less than the 63-72 years reported in the world literature^{9, 11, 16}. Interestingly, the age at presentation for Africans was the youngest, being about two decades younger than the world literature, while White patients were the oldest at presentation, again in agreement with the world literature. These population differences in age distribution mimics that seen in the general population of patients with colorectal cancer in KwaZulu-Natal, where Africans were a decade younger than the other population groups¹⁴.

As seen in most series^{10, 16} the sigmoid colon was the most common site of the primary lesion; this incidence differs the general disease distribution of colorectal cancer in the world literature and in south Africa¹⁴, where the rectum is the most common site. The greater tendency for perforation in the sigmoid colon compared to other regions is unknown but may be related in part to the narrower diameter of the lumen. There was no difference in sex distribution, and moderate differentiation was a finding in all except three patients; similar observations have been made by others¹⁰.

In contrast to obstructing colorectal cancer which has been repeatedly shown to be associated with advanced disease^{9, 13, 17}, reports on perforated colorectal cancer have yielded conflicting results. Some studies have suggested a greater incidence of metastatic disease, more advanced disease stage, and greater residual tumour burden at the time of presentation for perforated colorectal cancer^{6, 8-12, 15, 16, 18, 19}. Other studies have shown perforated cancers to be less advanced compared to obstructing cancers^{9, 10}. The reason for this difference may be related to a presumed longer time required to cause obstruction, resulting advanced stage at diagnosis, compared to the shorter time needed for tumour necrosis which appears to be the basis for perforation¹⁰.

The operative treatment of colorectal cancer with or without a contained perforation or obstruction depends primarily on the location of the lesion and the ability of a given patient to tolerate the procedure^{20, 21}. Circumstances which may lead to the modification of the surgical procedure are the presence of free perforation with peritonitis or the presence of obstruction in addition to perforation which may lead to changes on the calibre of the proximal bowel thereby potentially affecting the safety of an anastomosis. A segmental colectomy following oncologic principles suffices in the majority of cases with contained perforation. Subtotal colectomy with primary anastomosis may be considered for patients with left-sided perforation associated with obstruction which may lead to distension and ischaemia of the proximal colon; this approach relieves the obstruction (and its occult or obvious perforation) as well as the proximal distended colon or ischemia²²⁻²⁴. Otherwise resection of the neoplasm with proximal colonic diversion and a Hartmann's procedure may be indicated if there is local peritonitis. All patients in this series, however, were able to be managed by colectomy and primary anastomosis.

The clinical course of patients with malignant colorectal perforation depends on the onset of symptoms, as well as the patient's nutritional status, age, and co-morbidities²³. Whereas patients with free perforation generally present *in extremis*, those with contained perforation tend to present in a more elective fashion, albeit with signs of infection, such as fever and leucocytosis⁸. The predominant symptoms in this series were abdominal pain, abdominal distension, and change in bowel habit.

The zero mortality rate in this study is striking compared to the reported 5-40% in-hospital mortality for perforated colorectal cancer in other series^{5-7, 10-13, 15, 19, 25-27}. This discrepancy may be explained by the fact that contained perforation does not lead to peritonitis with its sequelae. This finding is supported by the observed greater mortality rate for free neoplastic perforation or perforation proximal to the obstructed tumour compared to contained perforation, suggesting that free perforation leads to peritonitis and possibly later carcinomatosis both of which lead to subsequent death^{8, 10, 11, 15, 28}. A free perforation is associated with greater

mortality whether it is associated with generalized peritonitis or localized abscess²⁷. The risk factors predictive of poor outcome are patient's age, degree of peritonitis and sepsis, tumour stage, cardiopulmonary co-morbidities, ASA grade, and the presence or absence of distant metastasis at presentation^{5, 8, 10-12, 15, 17, 19, 25}. Furthermore, patients in this study did not undergo emergency laparotomy except when there was associated obstruction and, even under these circumstances; the reason for the emergency procedure was the presence of colonic obstruction. Another possible explanation for the extremely low operative mortality may be that all these patients needed to be able to arrive at their local hospital and were thus not physiologically compromised. It is possible that patients with free perforation and thus with severe physiologic compromise may have been selected out and demised before arrival at the local hospital. This very low mortality is supported by findings in the only other study reporting on contained perforation⁸.

Our 93% rate of an R-0 resection compares favourably with other studies in which R-0 resection is reported in 62–68% of patients with perforated colorectal cancer⁸. Whether or not the malignant process extends to the circumferential margin is dependent not on the perforation itself but rather on the extent to which the malignant process has permeated through the bowel wall along with the necrosis as it causes the perforation.

The prognosis of patients with neoplastic perforation has not been entirely clear in the literature with some studies documenting a negative effect on patient outcome^{10, 29}, while other studies have associated perforation with positive outcome^{10, 12, 30, 31}. Two studies have associated a poorer survival and recurrence rates with perforation proximal to the tumour compared to non-perforated tumours, suggesting that spillage of tumour cells from the perforation into the peritoneal cavity results in tumour spread by peritoneal dissemination and a negative influence on survival^{8, 10}. Other series have suggested that once immediate post-operative morbidities have been corrected and if radical oncologic treatment has been performed, long term outcomes are similar to those of non-perforated controls. Therefore, an aggressive surgical approach based on oncologic criteria is indicated, and this further suggests that perforation with spillage of tumour cells into the contained area of perforation, if it indeed occurs, does not reach a degree that augments tumour implantation and is not necessarily an indicator of poor prognosis^{8, 10, 12, 16, 27}. These conflicting data stem from the tendency of previous studies to not clearly differentiate between free and contained perforation or between neoplastic and proximal perforation. Prognosis seems to be related to the nature of the perforation and the site of perforation in relation to the tumour itself, with consensus dictating that these patients should receive aggressive surgical intervention and appropriate adjuvant oncologic therapy¹⁰.

The limitations of this study are that the duration of follow-up was very poor. Follow-up is a major problem in our geographic society, with socio-economic status and difficulties with transport for face-to-face follow-up being major drivers of the poor follow-up. Also, it is likely that other patients with a perforated colorectal cancer were managed locally and might have been too ill to be sent to our regional units.

The strength of the study is that it specifically addresses contained perforation of colorectal cancer as opposed to free perforation and it differentiates direct neoplastic perforation from proximal perforation. This is an improvement on previous studies, whose weakness was failure to differentiate between free and contained perforation as well as neoplastic and proximal perforation. Moreover, this work is the first report to address this condition in South Africa and in Africa.

Conclusion

Malignant perforation in our setting is similar to that reported in the literature. The prevalence is the same in all population groups, and the sex incidence is similar, but the age at presentation

is younger in native Africans. The disease distribution follows general norms with minor variations. Contained perforation rarely led to peritonitis in our patient cohort which probably explains the zero postoperative mortality. The long term outcome depends on other factors and not on the perforation status. Therefore, provided these patients receive the same radical, oncologic resection as non-perforated colorectal cancer, the short and long term outcome should be quite similar.

Acknowledgement

The author would like to thank Dr Michael Sarr, Mayo Clinic, for critique of the final version of the manuscript.

References

1. Jemal A BF, Center MM. et al. Global Cancer Statistics. *CA Cancer J Clin* 2011; **61**(2): 69-90.
2. Stewart BW KP. Colorectal cancer. In: Stewart BW KP, ed. WHO World Cancer Report. Lyon: IARC Press; 2003: 198-202.
3. Parkin DM BF, Ferlay J, et al. Global Cancer Statistics, 2002. *CA Cancer J Clin* 2005; **55**: 74-108.
4. Gunnarsson H, Holm T, Ekholm A, Olsson LI. Emergency presentation of colon cancer is most frequent during summer. *Colorectal Dis* 2011; **13**(6): 663-8.
5. Kelley WE, Jr., Brown PW, Lawrence W, Jr., Terz JJ. Penetrating, obstructing, and perforating carcinomas of the colon and rectum. *Arch Surg* 1981; **116**(4): 381-4.
6. Runkel NS, Hinz U, Lehnert T, Buhr HJ, Herfarth C. Improved outcome after emergency surgery for cancer of the large intestine. *Br J Surg* 1998; **85**(9): 1260-5.
7. Smothers L, Hynan L, Fleming J, Turnage R, Simmang C, Anthony T. Emergency surgery for colon carcinoma. *Dis Colon Rectum* 2003; **46**(1): 24-30.
8. Zielinski MD, Merchea A, Heller SF, You YN. Emergency management of perforated colon cancers: how aggressive should we be? *J Gastrointest Surg* 2011; **15**(12): 2232-8.
9. Alvarez JA, Baldonado RF, Bear IG, Truán N, Pire G, Alvarez P. Presentation, treatment, and multivariate analysis of risk factors for obstructive and perforative colorectal carcinoma. *Am J Surg* 2005; **190**(3): 376-82.
10. Chen HS, Sheen-Chen SM. Obstruction and perforation in colorectal adenocarcinoma: an analysis of prognosis and current trends. *Surgery* 2000; **127**(4): 370-6.
11. Anwar MA, D'Souza F, Coulter R, Memon B, Khan IM, Memon MA. Outcome of acutely perforated colorectal cancers: experience of a single district general hospital. *Surg Oncol* 2006; **15**(2): 91-6.
12. Mandava N, Kumar S, Pizzi WF, Joseph Aprile I. Perforated colorectal carcinomas. *Am J Surg* 1996; **172**(3): 236-8.
13. Phillips RK, Hittinger R, Fry JS, Fielding LP. Malignant large bowel obstruction. *Br J Surg* 1985; **72**(4): 296-302.
14. Zulu B MT. Colorectal cancer in the KwaZulu-Natal Province: An established disease with a variable clinicopathological spectrum. *S Afr J Surg* 2011; **49**: 92-3.
15. Kriwanek S, Armbruster C, Dittrich K, Beckerhinn P. Perforated colorectal cancer. *Dis Colon Rectum* 1996; **39**(12): 1409-14.
16. Biondo S, Kreisler E, Millan M, et al. Differences in patient postoperative and long-term outcomes between obstructive and perforated colonic cancer. *Am J Surg* 2008; **195**(4): 427-32.
17. Garcia-Valdecasas JC, Llovera JM, deLacy AM, et al. Obstructing colorectal carcinomas. Prospective study. *Dis Colon Rectum* 1991; **34**(9): 759-62.
18. Khan S, Pawlak SE, Eggenberger JC, Lee CS, Szilagyi EJ, Margolin DA. Acute colonic perforation associated with colorectal cancer. *Am Surg* 2001; **67**(3): 261-4.

19. Kyllonen LE. Obstruction and perforation complicating colorectal carcinoma. An epidemiologic and clinical study with special reference to incidence and survival. *Acta Chir Scand* 1987; **153**(10): 607-14.
20. Chiappa A, Zbar A, Biella F, Staudacher C. One-stage resection and primary anastomosis following acute obstruction of the left colon for cancer. *Am Surg* 2000; **66**(7): 619-22.
21. Deen KI, Madoff RD, Goldberg SM, Rothenberger DA. Surgical management of left colon obstruction: the University of Minnesota experience. *J Am Coll Surg* 1998; **187**(6): 573-6.
22. Arnaud JP, Bergamaschi R. Emergency subtotal/total colectomy with anastomosis for acutely obstructed carcinoma of the left colon. *Dis Colon Rectum* 1994; **37**(7): 685-8.
23. Cuffy M, Abir F, Audisio RA, Longo WE. Colorectal cancer presenting as surgical emergencies. *Surg Oncol* 2004; **13**(2-3): 149-57.
24. Reemst PH, Kuijpers HC, Wobbes T. Management of left-sided colonic obstruction by subtotal colectomy and ileocolic anastomosis. *Eur J Surg* 1998; **164**(7): 537-40; discussion 41-2.
25. Biondo S, Pares D, Marti Rague J, et al. Emergency operations for nondiverticular perforation of the left colon. *Am J Surg* 2002; **183**(3): 256-60.
26. Mulcahy HE, Skelly MM, Husain A, O'Donoghue DP. Long-term outcome following curative surgery for malignant large bowel obstruction. *Br J Surg* 1996; **83**(1): 46-50.
27. Lee IK, Sung NY, Lee YS, et al. The survival rate and prognostic factors in 26 perforated colorectal cancer patients. *Int J Colorectal Dis* 2007; **22**(5): 467-73.
28. Crowder VH, Jr., Cohn I, Jr. Perforation in cancer of the colon and rectum. *Dis Colon Rectum* 1967; **10**(6): 415-20.
29. Willett C, Tepper JE, Cohen A, Orlow E, Welch C. Obstructive and perforative colonic carcinoma: patterns of failure. *J Clin Oncol* 1985; **3**(3): 379-84.
30. Garcia-Peche P, Vazquez-Prado A, Fabra-Ramis R, Trullenque-Peris R. Factors of prognostic value in long-term survival of colorectal cancer patients. *Hepatogastroenterol* 1991; **38**(5): 438-43.
31. Steinberg SM, Barkin JS, Kaplan RS, Stablein DM. Prognostic indicators of colon tumors. The Gastrointestinal Tumor Study Group experience. *Cancer* 1986; **57**(9): 1866-70.