

## Course of the Sciatic nerve: a Review of Cases Seen at Mulago Hospital, Kampala - Uganda

J. Kukiriza, C. Ibingira, J. Ochieng

Department of Anatomy, School of Biomedical Sciences, Makerere University, Uganda

Correspondence to: J Ochieng, Email: [ochiengjoe@yahoo.com](mailto:ochiengjoe@yahoo.com)

**Background:** *The sciatic nerve is the largest in the body with nerve roots L4, 5 S1, 2, 3. It is commonly injured in the body particularly following administration of gluteal intramuscular injections to children. The nerve usually leaves the pelvis by passing through the greater sciatic foramen below the piriformis and anterior to the superior and inferior gemelli and the obturator internus muscles. However, it should be noted that this usual course varies on many occasions and these variations have been cited as predisposing factors to certain clinical conditions including piriformis syndrome, coccydynia, muscle atrophy, traumatic administration of intramuscular injections leading to foot drop and bilateral gluteal fibrosis. This study describes the course of the sciatic nerve among adult subjects at Mulago hospital complex.*

**Methods:** *This was a cross-sectional descriptive study conducted at the department of anatomy dissection laboratory Makerere University and the associated Mulago teaching hospital mortuary. Dissections of the lower limbs from the gluteal region through the thigh to the leg were done to expose the nerves and surrounding structures.*

**Results:** *A total of 80 adult thighs and gluteal regions were dissected in 56 males and 24 females to trace and expose sciatic nerves. . All sciatic nerves were located in the lower medial quadrant between the ischial tuberosity and the greater trochanter. In the gluteal region, the whole sciatic nerve measured 4.2 cm, and among subjects with bifurcated nerves, the tibial and common peroneal nerves were 4.67cm and 3.3cm, respectively, along a perpendicular line drawn medially from the midpoint between the posterior superior iliac spine and the greater trochanter.*

**Conclusion:** *The course of the sciatic nerve in the gluteal region is variable and hence, appreciation of these variations can be useful during clinical and surgical procedures in the gluteal and thigh regions.*

**Key word:** sciatic nerve, course, cases

### Introduction

The sciatic nerve (L4, 5 S1, 2, 3) is largest and most commonly injured nerve in the body particularly following administration of gluteal intramuscular injections to children. It usually has two branches as the tibial and common peroneal nerves and innervates the muscles and skin of the gluteal region, posterior thigh, leg and foot.

The nerve leaves the pelvis by passing through the greater sciatic foramen below the piriformis and anterior to the superior and inferior gemelli and the obturator internus muscles <sup>1, 2</sup>. However, this usual course may at times vary and these variations have been cited as predisposing factors to certain clinical conditions like Piriformis syndrome, Coccydynia, muscle atrophy and trauma when administering intramuscular injections leading to foot drop and bilateral gluteal fibrosis <sup>3-7</sup>. Proper location of the nerve is also important for sciatic nerve block that is employed to facilitate surgery on the leg and foot. Despite the importance of the nerve, its vulnerability to iatrogenic injury and plenty of literature on its course, no such documentation had been made among the Ugandan population. We are reporting findings of a study conducted among cases seen at the department of Anatomy Makerere University and its associated Mulago National Referral and Teaching Hospital.

This study set out to describe the course of the sciatic nerve among cases seen at Mulago hospital complex.

### Subjects and Methods:

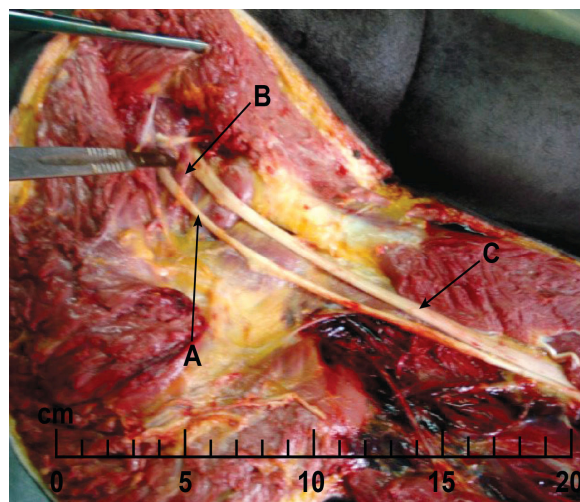
This was a cross-sectional descriptive study conducted at the department of anatomy dissection laboratory Makerere University and Mulago teaching hospital mortuary. Using a dissection manual, the lower limbs were dissected from the gluteal region to the upper leg in order to expose the nerve. The relationships and branches of the nerve along its course were then identified, recorded and photographed. Measurements were taken using a tape to estimate the distances. Ethical review and approval was sought from the Makerere University Faculty of Medicine Research and Ethics Committee. Informed consent was obtained from the next of keens of the deceased in case of the postmortem specimens.

### Results

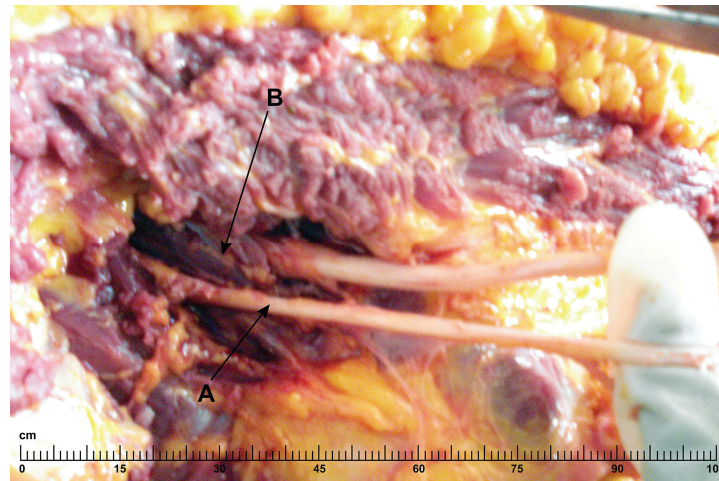
A total of 80 adult thighs from 56 males and 24 females were dissected. 60 were postmortem (41 male/19 female) and 20 were from the anatomy dissection laboratory (15 male/5 female).

All the sciatic nerves were located in the lower medial quadrant between the ischial tuberosity and the greater trochanter. In 18 (22.5%) of the cases, the nerve bifurcated in the gluteal region but all others occurred in the posterior thigh. In 4 (5%) of the cases, the tibial nerve passed below superior gamellus and the common peroneal nerve passed above the same muscle. Yet in another 2 (2.5%), the common peroneal nerve passed above and the tibial nerve below the piriformis. (Figure 1 and 2)

In one case (1.2%) the common peroneal nerve pierced the piriformis and the tibial nerve passed below it. In the gluteal region, the whole sciatic nerve was 4.2 cm, and among subjects with bifurcated nerves, the tibial and common peroneal nerves were 4.67cm and 3.3cm respectively along a perpendicular line drawn medially from the midpoint between the posterior superior iliac spine and the greater trochanter.



**Figure 1.** Common peroneal nerve (A) passing above superior gamellus (B) and Tibial nerve (C) passing below.



**Figure 2.** Common peroneal nerve (A) passing above piriformis (B) and the Tibial nerve passing below piriformis.

### Discussion

All the sciatic nerves were located in the lower medial quadrant between the ischial tuberosity and the greater trochanter. This is in agreement with other studies which have indicated that the traditional outer upper quadrant is still safe for administration of intramuscular injections and hence calling the lateral side of the gluteal region a side of safety. The superolateral quadrant of the gluteal region has also been preferred for intramuscular injections because it has been found to be relatively free of nerves and blood vessels <sup>(8)</sup>. Hence the need to stress that gluteal injections should be given in the lateral upper quadrant in order to minimize the injuries to the nerve which are still common in Uganda.

The common peroneal nerve passed through the piriformis muscle in 1.2% of all cases in this study. Similar studies have found, however, the whole sciatic nerve passing through the piriformis in 0.8% in Americans<sup>(9)</sup> 2.2%,<sup>(10)</sup>, and 15% in another study among Americans <sup>(11)</sup> of individuals, respectively. The implication of this in individuals with this variation is that when the piriformis muscle contracts, it compresses the nerve which may lead to sciatic nerve pain known as piriformis syndrome. <sup>(9-11)</sup>. The findings of 2.2% and 0.8% are close to what is being reported in the current study of Ugandan population which is 1.2%. However, this is very far from the 15% reported in another study.

The tibial nerve passed below the superior gamellus while the common peroneal nerve passes above the superior gamellus in 5% of the cases. (Figure 1) A similar variation was observed in some of the cases dissected in previous studies <sup>(12-14)</sup>. This makes the Uganda population exhibit similarities to other populations. In 2.5% of the cases the common peroneal nerve passed above the piriformis muscle whereas the tibial component passed below (Figure 2). Similar variations have been reported in other related studies <sup>(15, 16)</sup>.

As a result of these variations, the tibial nerve may be either found between the piriformis and the external rotators of the thigh or between the superior gamellus and the obturator internus muscle, resulting in the compression of this nerve when these muscles contract leading to piriformis or superior gamellus syndromes <sup>(17)</sup>. Much as the occurrence of these variations is not so high, their existence should be taken into consideration by clinicians in the etiology and

pathogenesis of sciatica. It should be noted that the above variations occurred in cases where the sciatic nerve entered the gluteal region in a bifurcated state indicating a high risk of compression of the nerve in these people than in cases where the nerve enters the gluteal region in an intact state.

The sciatic, tibial and common peroneal nerves were found at mean variable distances along a perpendicular line drawn medially from the midpoint between the posterior superior iliac spine and the greater trochanter of the femur of; 4.2cm, 4.67cm and 3.3cm respectively. Previous studies have reported this distance to be 3-5cm and 2-5cm <sup>(18, 19)</sup>. Hence the findings in this study are in agreement with previous studies elsewhere. This technique is applied to locate the nerve during the posterior approach of sciatic nerve block in the gluteal region. It is usually done in surgery of the knee, tibia, ankle, foot, calf and Achilles tendon. The major trunk of the nerve before it gives off the hamstring branches is found at variable distances on this medial perpendicular line. As a result, the needle is placed at the 5cm point if the anesthesia is to be placed proximal to the nerve. Additionally, modern technology like ultrasound-guided nerve blocks has proved to be more successful and effective and should be applied in our population. (13, 14 20-22)

## Conclusions

The sciatic nerve and its components in this study were found in the lower medial quadrant of the gluteal region and therefore the outer upper quadrant is still safe for administration of intra muscular gluteal injections.

The tibial nerve passed between the superior and the inferior gamelli while the common peroneal nerve passed between the piriformis and the superior gamellus in 5% of cases. The common peroneal nerve pierced the piriformis and the tibial nerve passed below it in 1.2% of cases. The point of 5cm along a perpendicular line drawn medially from the midpoint between the posterior superior iliac spine and the greater trochanter of the femur is still safe for needle placement during sciatic nerve block in the gluteal region among the Ugandan population studied.

## Acknowledgement

We appreciate the financial assistance from SIDA/SAREC which enabled this study to be conducted. Our thanks go to the Departmental staff of Anatomy and Pathology, School of Biomedical Sciences, Makerere University.

## References:

1. Moore KL, Daley FA. *Clinically oriented anatomy*, Fifth edition. Baltimore, Lippincott Williams and Wilkins. c2006. p. 379
2. Snell RS. *Clinical Anatomy*. Seventh edition. Lippincott Williams and Wilkins. 2006. Chapter 10, Sciatic nerve; pg 610- 611.
3. Small SP. *Preventing Sciatic nerve injury from intramuscular injections*. Journal of Advanced Nursing. 47(3): 2004 August; pp. 287- 296
4. Papadopoulos SM., McGill cuddy JE, Alberts LW. *Unusual case of piriformis muscle syndrome*. Arch. Neurologia. 47(10): 1990; pp.1144-1146.
5. Okello J, Franceschi F, Kintu D, Otim L. *Report on foot drop in CORU Mengo Hospital*. East and Central journal of surgery. 12 (1): 2006 April; pp. 139-143.
6. Ekure J. *A case report of bilateral gluteal fibrosis*. East and Central African journal of surgery. 11(2): 2006 December; pp.78-104



7. Naddumba EK, Ndoboli P. Sciatic nerve palsy associated with intramuscular quinine injections in children. East and Central African Journal of surgery vol.4, no.2, 1999, pp. 17-20.
8. O'rahilly, Muller, Carpenter and Swenson, *Basic anatomy*, 2008, Partmouth Medical School, ([http://www.partmouth.edu/~humananatomy/part\\_3/chapter\\_14.html](http://www.partmouth.edu/~humananatomy/part_3/chapter_14.html))
9. Beaton LE, Anson AJ. *The relationship of the sciatic nerve and of its subdivisions to the piriformis muscle*. Anat. Rec. 70; 1-5. 1937.
10. [http://www.en.wikipedia.org/wiki/piriformis\\_syndrome](http://www.en.wikipedia.org/wiki/piriformis_syndrome)
11. <http://www.rice.edu/~jenky/sports/piri.html>
12. Babinski M A, Machado FA., Costa WS. *A rare variation in the high division of the Sciatic nerve surrounding the Superior gemellus muscle*. European journal of morphology. Volume 41; 1<sup>st</sup> February 2003. pg 41-42.
13. Jaijesh P, Satheesha N. *A case report of bilateral high division of sciatic nerve with a variant inferior gluteal nerve*. Journal of neuroanatomy. Vol 5: 33-34, August (2006) Available at; (<http://www.neuroanatomy.org>)
14. Nuket M, et al. *A case of bilateral high division of the sciatic nerves, together with a unilateral unusual course of the tibial nerve*. Journal of neuroanatomy, volume 2; 2003, page 13-15. ([http://www.neuroanatomy.org/2003/013\\_015.pdf](http://www.neuroanatomy.org/2003/013_015.pdf))
15. Machado FA, Babinski MA, Brasil FB, Favorito LA, Abidu FA, Costa MG: *Anatomical variations between sciatic nerve and piriformis muscle during fetal period in human*. Int. Journal of Morphology. 21(1); 2003. Pp29-35.
16. Prasad AM, et al. *Clinically important variations in the lower limb- a case report*. European journal of anatomy, 9(3): (2005). Pp.167-169.
17. Arifoglu Y, Sürü .C. H. S, Sargon. M.F, et al. *Double superior gemellus together with double piriformis and high division of the sciatic nerve*. Volume 19, number 6 / March, 1998.
18. Shruti S, et al. *Neurological complication after anterior sciatic nerve block*. Journal of Anesth Analg. vol.100: 2005. Pp.1515-1517.
19. Labat G. Regional anesthesia: *Its technique and clinical application*. Philadelphia, PA: WB. Saunders, 1992. ([http://www.cookcountryregional.com/chapter\\_frame7.htm](http://www.cookcountryregional.com/chapter_frame7.htm))
20. Simon. M. *Nerve blocks for anesthesia and analgesia of the lower limb- A practical guide: Femoral, Lumbar plexus, Sciatic nerve*. Issue 11 (2000), article 12. Available at: [http://www.nda.ox.ac.uk/wfsa/htm/u11/u1112\\_04.htm](http://www.nda.ox.ac.uk/wfsa/htm/u11/u1112_04.htm)
21. Vicente D.T, Salvador S, Francisco M et al. *Ultrasound guidance for lateral mid femoral sciatic nerve block; a prospective comparative randomized study*. Anesth Analg. 2007; 104: 1270 -1274.
22. J. Kukiriza; H. Kiryowa, J. Turyabahika; J. Ochieng; CBR Ibingira. *Levels of Bifurcation of the Sciatic Nerve among Ugandans at School of Biomedical Sciences Makerere and Mulago Hospital Uganda*. East and Central African Journal of Surgery. Vol 15 No 2 July/Aug 2010