

#### Fourth Consecutive Ectopic Pregnancy- Beating the previous number

S.R. Singhal<sup>1</sup>, V. Sangwan<sup>2</sup>

**Institutional Affiliation-** <sup>1</sup>Professor, <sup>2</sup>Assistant Professor, Department Of obstetrics and Gynecology, Pt B D Sharma Post Graduate Institute Of medical Sciences, Rohtak, Haryana, India.

**Correspondence to:** Savita Rani Singhal, Email- savita06@gmail.com

*Recurrent ectopic pregnancy is not very uncommon. There are few case reports of consecutive three ectopic pregnancies. We present an interesting case of 26 years old patient who presented with consecutive fourth ectopic pregnancy which is not reported in literature. In this patient, for the first ectopic pregnancy left salpingectomy and for the second ectopic pregnancy, laparotomy followed by conservative surgical treatment (milking of right fallopian tube) was done three and two and half years ago respectively. Third ectopic pregnancy was managed medically by giving one intramuscular injection of 50 mg of methotrexate. Present one was fourth ectopic in right fallopian tube for which, patient was given medical treatment (intra muscular methotrexate) and she was advised to undergo in vitro fertilization.*

**Key Words :** Ectopic pregnancy, Consecutive, Fourth.

#### Introduction

Recurrent ectopic pregnancy is not uncommon. Various factors like pelvic inflammatory disease, tubal surgery, infertility and previous history of ectopic pregnancy can lead to consecutive ectopic pregnancies. The incidence of recurrence reported after first and second ectopic is 15% and 27.5% respectively <sup>1</sup>. A case of consecutive fourth ectopic pregnancy is being reported for the first time.

#### Case Report-

A 26-years old, gravida four with history of previous three consecutive ectopic pregnancies was admitted with history of seven weeks of amenorrhea and pain abdomen for one day. Her general condition and vitals were stable. Ultrasound reported a heteroechoic mass of 2.5 X 3.0 cm size in right adnexa with minimal free fluid and her serum  $\beta$  hCG levels were 4000 mIU/ml. Diagnosis of unruptured ectopic pregnancy was made and conservative treatment with single dose of 50 mg methotrexate was started. She responded well and her  $\beta$ hCG levels on day 4 and day 7 were 2710 and 900 mIU/ml respectively. Detailed past history and records revealed that she was married for seven years and could not conceive for first four years for which she took off and on treatment. However, three years back her first pregnancy was left tubal pregnancy which ruptured and for which left salpingectomy was done.

Two and half years back she had right tubal pregnancy which was managed by exploratory laparotomy followed by milking of the tube as the pregnancy was already in the process of tubal abortion. After two months of that episode, two years back, she again developed ectopic pregnancy in the right tube which was managed conservatively

with single dose of 50 mg of methotrexate. Present was the fourth consecutive ectopic pregnancy after a gap of one and half years which was managed conservatively and she was advised to go for in vitro fertilization.

## Discussion

There are case reports of three consecutive recurrent ectopic pregnancies<sup>2,3,4</sup>. Milingos<sup>3</sup> reported a patient who had three consecutive ectopic pregnancies on the ipsilateral side after natural conception and was treated surgically in each case with partial salpingectomy, removal of tubal stump, and resection of the uterine cornua, respectively. In the present case also three ectopics were ipsilateral after left sided salpingectomy in the first ectopic pregnancy. Adelusi et al<sup>2</sup> reported a case of three consecutive ectopic pregnancies in a 36-year-old woman who was under treatment for infertility. There is a report of seven ectopic pregnancies but those were not consecutive and patient had term deliveries before and in between the ectopic pregnancies<sup>5</sup>. There is no significant difference in the outcome in terms of recurrence and further fertility after medical and conservative surgical management. In the present patient infertility and ectopic pregnancy caused recurrent ectopic pregnancies.

Early diagnosis and management of ectopic pregnancy is crucial as delay can be disastrous for the patient's fertility as well as for her life, as previous ectopic pregnancy is a high risk for recurrence. One important issue is whether a woman with previous three ectopic pregnancies, who is at very high risk for recurrent ectopic pregnancy, should go for spontaneous conception or be offered other options for fertility treatment. In the present case this was fourth consecutive ectopic pregnancy unreported so far in a span of three years and she was counselled for in vitro fertilization.

## Conclusion

Every woman with a previous ectopic pregnancy is at high risk for recurrence and woman should be counselled to report at the earliest in next pregnancy to rule out ectopic gestation as delay can be disastrous for fertility and her life.

## References

1. Tulandi T. Reproductive performance of women after two tubal ectopic pregnancies. *Fertil steril* 1988; 50:164.
2. Adelusi B, AL- Meshari A, Akande EO, Chowdhury N. Three consecutive recurrent ectopic pregnancies. *East Afr Med J* 1993 Sep; 70(9):592-4.
3. Milingos DS, Black M, Bain C. Three surgically managed ipsilateral spontaneous ectopic pregnancies. *Obstet Gynecol* 2008 Aug; 112:458-9.
4. Eryilmaz ÖG et al. Recurrent Ectopic Pregnancies: Analysis of Risk Factors of Thirteen Patients. *J Clin Analytical Med* 2012; 3(2): 131-3.
5. Faiz SA, Sporrang BG, Al-Meshari AA case of seven recurrent ectopic Pregnancies. *Saudi Med J* 2003; 24 (5): 52.

## Retrocaval Ureter: a Case Report

T. BerheGebretsadik<sup>1</sup>, Y. Suga<sup>2</sup>

<sup>1</sup> Assistant professor of urology, Department of surgery, St. Paul Hospital Millennium medical college, Addis Ababa, Ethiopia

<sup>2</sup> Lecturer and surgery resident, Department of surgery, St. Paul Hospital Millennium medical college, Addis Ababa, Ethiopia

**Corresponding author:** Tekleberhan Berhe, E-mail: tekberr@yahoo.com

***Retrocaval ureter or preureteral vena cava is a rare congenital abnormality which leads to external ureteral compression by the inferior vena cava (IVC) resulting in lumbar pain and Hydronephrosis. Intravenous urography, retrograde pyelography, CT, and MRI are main diagnostic investigations. Surgical intervention is required in most of cases.***

***We present a case of 22 years old male who presented with right flank pain and Hydronephrosis. Diagnosis was confirmed by IVU and retrograde pyelography. Exploration of ureter, its transaction and end to end anastomosis was done anterior to the inferior vena cava.***

### Introduction

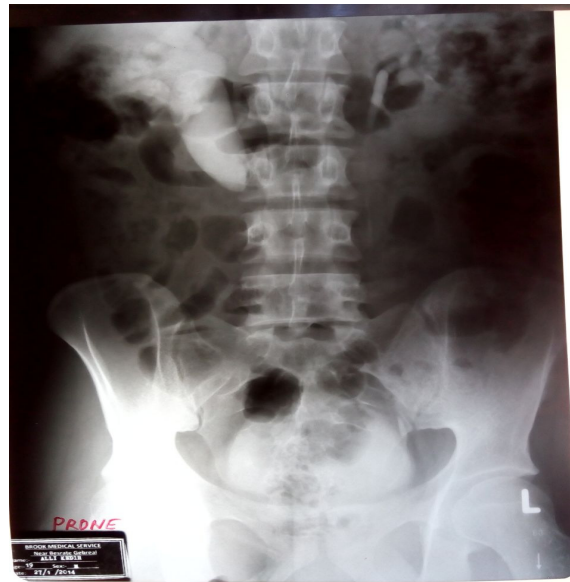A variety of vascular lesions can cause ureteral obstruction. With these lesions, the vascular system rather than the urinary system is anomalous. Retrocaval ureter also referred to as circumcaval ureter or preureteral vena cava is a rare congenital anomaly with the ureters passing posterior to the inferior vena cava. It was initially considered as aberration in ureteric development; however current studies in embryology have led to it being considered as an aberration in the development of the inferior vena cava<sup>1,2,3</sup>. Hence it is being suggested that the anomaly be referred to as a pre-ureteral vena cava<sup>4,5</sup>. This disorder involves the right ureter, which typically deviates medially behind (dorsal to) the inferior vena cava, winding about and crossing in front of it from a medial to a lateral direction, to resume a normal course, distally, to the bladder. The renal pelvis and upper ureter are typically elongated and dilated in a J or fishhook shape before passing behind the vena cava. Cardinal veins are considered to be the basic abnormality in which right subcardinal vein forms the main portion of IVC ventral to the ureter instead of right supra cardinal vein. Consequently the ureter winds behind the IVC from medial to lateral instead of lying lateral to it.

Intravenous Urography (IVU) and retrograde ureteropyelography are very helpful for the diagnosis. On IVU there may be hydronephrosis of the right kidney, dilatation of the upper 1/3rd of ureter an S-shaped curve of the ureter and on oblique view ureter hugging the lumbar spine. Abdominal ultrasound demonstrates hydronephrosis. IVU usually does not demonstrate the middle and distal ureter requiring a retrograde ureteropyelogram to demonstrate the ureter and hence confirm the diagnosis. Retrograde pyelography reveals medial displacement of non-dilated lower ureter beyond the midline. Ultrasound and CT or MRI also have been useful in defining the vascular malformation. When necessary, CT may be the procedure of choice to confirm the diagnosis and avoid retrograde ureteropyelography<sup>6</sup>.

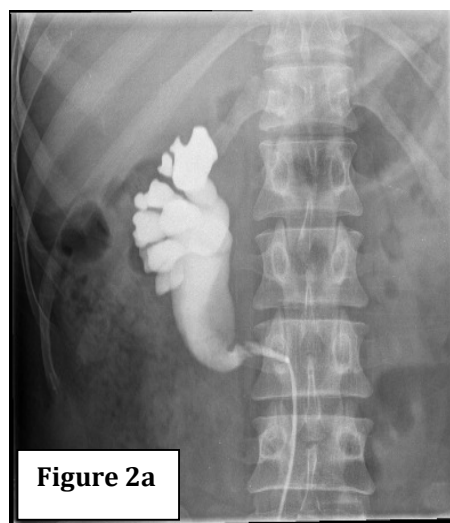MRI can nicely demonstrate the course of a preureteral vena cava and may be a more detailed and less invasive imaging modality when compared with CT and retrograde pyelography. Clinically, patients may present with symptoms of flank pain, recurrent infections and haematuria. It is of interest, as this case report happens to be the second symptomatic case to be reported in Ethiopia and one of the few cases in Africa<sup>7,8</sup>.

### Case Report

A 22 year old male patient presented to us with history of right flank pain of 2 years duration and recent onset of hematuria. He had no other urinary complaints. Physical examination was unremarkable. Urinary microscopy showed 4-5 RBC casts. Complete blood count, urea and creatinine were all normal. Through right flank subcostal incision the right ureter was explored. Right ureter was dilated and passing behind the IVC and then normal looking ureter coursing downward. The Right ureter was transected and spatulated end to end anastomosis over double J stent done. Post-operative recovery was uneventful. Double J sent removed after 4 weeks and follow up sonography showed remarkable improvement in hydronephrosis.

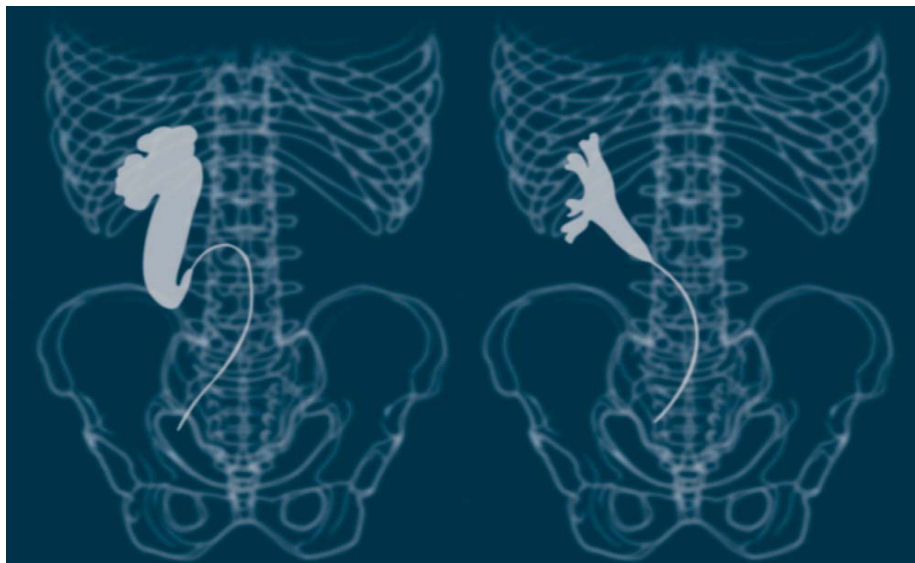


**Figure 1.** Intravenous Pyelography



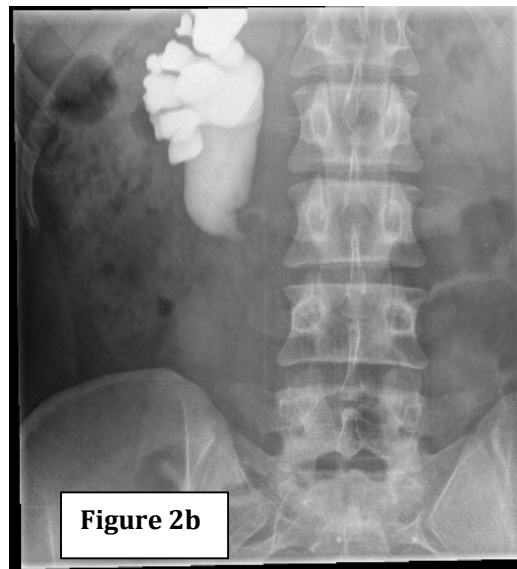

Figure 2a & 2b.. Retrograde pyelography.



**Figure 3.** Diagrammatic representation illustrating the radiological features of Type I (left side) and Type II (right side) circumcaval ureter (modified from Bateson and Atkinson. Circumcaval ureter: a new classification. ClinRadiol 1969;20:173-7).

### Discussion

Retrocaval ureter is a rare condition that results from an anomaly in the development of the inferior vena cava <sup>9</sup>. The incidence was reported to be approximately 1 in 1000 people, with male predominance <sup>10</sup>. It was first reported by Hochstetter in 1893 <sup>11</sup>. Although the lesion is congenital, most patients do not present until the third or fourth decade of life. Common



presentation includes right flank pain, recurrent urinary tract infections and varying degree of haematuria

Retrocaval ureter can be classified into two varieties according to radiological appearances <sup>(12)</sup>.

1. The more common type I has hydronephrosis and a typically obstructed pattern demonstrating some degree of fishhook-shaped deformity of the ureter to the level of the obstruction, and
2. Type II has a lesser degree of hydronephrosis or none at all. Here, the upper ureter is not kinked but passes behind the vena cava at a higher level, with the renal pelvis and upper ureter lying almost horizontal before encircling the vena cava in a smooth curve (Figure 3).

In type I, the obstruction appears to occur at the edge of the iliopsoas muscle, at which point the ureter deviates cephalad before passing behind the vena cava. In type II, the obstruction, when present, appears to be at the lateral wall of the vena cava as the ureter is compressed against the perivertebral tissues. Both CT scan and magnetic resonance imaging are efficient methods of confirming the diagnosis.

Surgical intervention is often required to alleviate the symptoms. Open surgical exploration is commonly used technique. Surgical correction involves ureteral division, with relocation and ureteroureteral or ureteropelvic reanastomosis, usually with excision or bypass of the retrocaval segment, which can be aperistaltic. Open surgical exploration is commonly used technique although it is being replaced by minimally invasive laparoscopic technique with advantages of minimal postoperative pain and early recovery <sup>13,14,15,16,17</sup>.

## References

1. Chuang VP, Mena CE, and Hoskins PA. Congenital anomalies of the inferior vena cava. Review of embryogenesis and presentation of a simplified classification. *Br J Radiol.* 1974; 47: 206–213.
2. Schluskel, RN, Retik AB. Preureteral Vena Cava. In: Kavoussi LR, Novick AC, Partin AW, Peters CA editors. *Campbell-Walsh Urology*. 9th ed. El-sevier Saunders; 2007.p 3418-3420.
3. Lesma A, Bocciardi A, Rigatti P. Circumcaval Ureter: Embryology. *European Urology* 2006; (supplements 5):444 – 448
4. Dreyfuss W. Anomaly simulating a retrocaval ureter. *J Urol.* 1959; 82:630.
5. Lerman I, Lerman S, Lerman F. Retrocaval ureter: Report of a case. *J Med Soc N J.* 1956; 53:74.
6. Bass FE, Redwine MD, Kramer LA, Huynh PT, Harris JH. Spectrum of congenital anomalies of the inferior vena cava: cross-sectional imaging findings. *RadioGraphics* 2000; 20:639–52.
7. A.Tegegne, C. Cobas, East and Central African Journal of Surgery, Vol. 14, No. 1, March-April 2009, pp. 119-121
8. M.Y. Kyei, E. D. Yeboah, G. O. Klufio, J. E. Mensah, S. Gepi-Atee, L. Zakpaa, B. Morton, and B. Adusei. Two case reports on retrocaval ureter, Number 4 Ghana Medical Journal 2011; 4: 45.
9. Lautin EM, Haramati N, Frager D, Friedman AC, Gold K, Kurtz A, et al. CT diagnosis of circumcaval ureter. *AJR Am J Roentgenol.* 1988; 150(3):591–594.

10. Uthappa MC, Anthony D, Allen C. Case report: Retrocaval ureter: MR appearances. *Br J Radiol.* 2002; 75(890):177-179.
11. Ouyang CC, Chueh SC, Hsu TC, Chen J, Tsai TC, Chiu TY. Retrocaval ureter- three case reports and review of the literature *J Urol ROC* 1994; 5:49-53.
12. Bateson EM, Atkinson D. Circumcaval ureter: A new classification. *Clinical Radiol.* 1969; 20: 173-7.
13. Bhandarkar DS, Lalmalani JG, Shivde S. Laparoscopic ureterolysis and reconstruction of a retrocaval ureter. *SurgEndosc* 2003; 17:1851-1852.
14. Tobias-Machado M, Lasmar MT, Wroclawski ER. Retroperitoneoscopic surgery with extracorporeal uretero-ureteral anastomosis for treating retro-caval ureter. *Int Braz J Urol* 2005; 31:147-150.
15. Nagraj HK, Kishore TA, Nagalakshmi S. Transperitoneal laparoscopic approach for retrocaval ureter. *J Minim Access Surg.* 2006; 2(2): 81-2.
16. Singh O, Gupta SS, Hastir A, Arvind NK. Laparoscopic transperitoneal pyeloplasty and reteroureterostomy of retrocaval ureter: Report of two cases and review of the literature. *J Minim Access Surg.* 2010; 6(2): 53-5.
17. Hemal AK, Rao R, Sharma S, Clement RG. Pure robotic retrocaval ureter repair. *Int Braz J Urol.* 2008; 34(6): 734-8.