

Role of Magnetic Resonance Imaging in Assigning Sex in an Ambiguous Genitalia Child: A case report

F. R. Lyimo, F. J. Minja², V. P. Sensa³

¹Department of Radiology, Muhimbili National Hospital, Dar es Salaam, Tanzania.

²Yale Diagnostic Radiology Department, Yale University School of Medicine, USA

³Department of Urology, Muhimbili National Hospital, Dar es Salaam, Tanzania

Correspondence to: FR Lyimo, Email: freddielly@gmail.com

A three years old child with ambiguous genitalia since birth had been referred to Muhimbili National Hospital (MNH), a tertiary referral hospital, in order to be evaluated and assigned sex correctly. Due to periphery location of the referring center, social and economic constraints, the child was not presented earlier. Physical examinations were done followed by imaging studies. Magnetic resonance imaging (MRI) performed, showed female sex which was confirmed by karyotyping. In conclusion, use of MRI plays a potential key role in sex assignment of ambiguous genitalia children.

DOI: <http://dx.doi.org/10.4314/ecajs.v21i2.15>

Introduction

Ambiguous genitalia, is among a group of disorders of sex development (DSD) characterized by abnormal appearance of external genitalia. This condition poses both medical and social emergency and requires timely management. Sex assignment among children with ambiguous genitalia remains a great challenge and requires multidisciplinary approach. Previous studies and reports indicate that ambiguous genitalia is a cause of great anxiety and confusion to health care providers, family and society at large. However, the use of MRI in assigning sex of ambiguous genitalia child is limited. We report a case of ambiguous genitalia child whose sex was determined by use of MRI and confirmed by karyotyping.

Case Report

We present a case of 3-year-old child referred to MNH, a tertiary referral hospital facility with a history of ambiguous genitalia since birth. The child presented with history of absence of testicles and urinary opening was seen on the inferior aspect of the phallus. No other abnormality was reported. Maternal drug history was unremarkable during this child's pregnancy. There was negative history of ambiguous genitalia in the family. Male sex was assigned at birth.

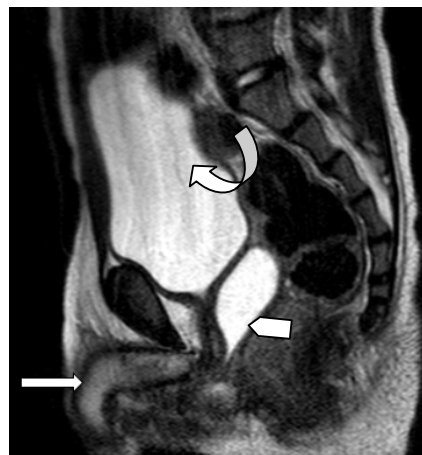

Figure 1. Sagittal T2W MRI showing phallic structure (arrow) which was enlarged clitoris, fluid filled distended uterus (arrow head) and fluid filled urinary bladder (curved arrow).

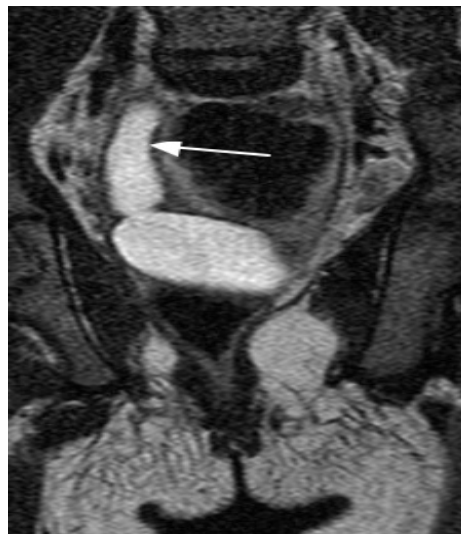

Figure 2. Coronal T2W MRI showing right unicornuate fluid filled uterus (hydrometra)

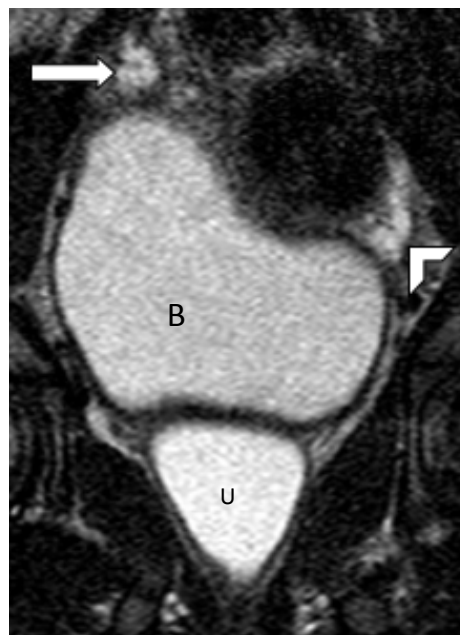


Figure 3. Coronal T2W MRI showing ovaries (long arrow and arrow head) and full urinary bladder (B) and fluid filled uterus (U)

Pelvic exam revealed phallic structure with urethra at its inferior aspect. Labia majora was seen; however, there was no vaginal opening. No masses were felt in the inguinal region suggestive of testes. There was no pubic, armpit or facial hair seen. The rest of exam did not give ancillary findings. A clinical diagnosis of female pseudo-hermaphrodite with vaginal synechia was made with a differential diagnosis of male gender with hypospadias and undescended testis. This was because of close resemblance of the phallic structure to penis and urethra being visualized on its underside.

Pelvic ultrasound revealed two fluid containing structures of which one was the urinary bladder, the other was suggestive of distended fluid filled uterus. Ovaries were not visualized.

Testes were not visualized. Both kidneys had normal sonographic appearance. No supra renal mass lesion suggestive of adrenal mass was seen on either side of the abdomen. The remaining abdominal organs had normal sonographic findings. Ultrasound results were therefore inconclusive.

Pelvic MRI revealed a phallic structure which was enlarged clitoris (Figure 1). Clitoromegaly was demonstrated supported by lacking corpora carvenosum and corpus spongiosum which normal supporting penile tissues⁵ are.

There was fluid filled distended right unicornuate uterus (Figure 2). Both ovaries were visualized (figure 3). Urinary bladder was fully distended (Figure 1 and 2).

Radiological diagnosis of female gender with right unicornuate fluid filled uterus, clitoromegaly and vagina synechiae was made. Karyotyping confirmed female sex. Final diagnosis was female pseudo-hermaphrodite (46XX, with two ovaries) with vaginal synechiae. The Child was planned to have vaginoplasty with clitoroplasty after appropriate counseling and consent from parents. The parents defaulted however.

Discussion

Disorders of sex development constitute social and medical emergency requiring multidisciplinary approach in management. It is of extreme importance to accurately establish genital anatomy prior to definitive management of these disorders^{1,2,4}. DSDs are classified into female pseudo-hermaphroditism (46 XX, with 2 ovaries), male pseudo-hermaphroditism (46 XY, with 2 testes), true hermaphroditism (both ovaries and testes present) and gonadal dysgenesis¹. Imaging plays a crucial part in illustration of internal organs and urogenital anatomy in children with DSDs⁶.

Ultrasound being cheap, non-invasive, not involving radiation or sedation and readily accessible is the usual first investigation of choice for the assessment of internal sex organs. Uterus and ovaries can relatively be easily identified when are under maternal hormones influence during the neonatal period ^(1,3,6,7). During pregnancy, ultrasound assessment of fetal sex is recommended only when medically specified and in twin situation⁸.

Our patient's age was outside neonatal period range. Pelvic sonography was the least beneficial in describing internal genitalia as timing was past maternal hormone influence period; Ultrasound showed two cystic structures; one was identified as urinary bladder. The other was suggestive of the distended fluid filled uterus. Ultrasound failed to locate both ovaries in our case. There was no supra renal mass seen suggestive of adrenal mass bilaterally. Further and more informative imaging evaluation was necessary to determine internal genital anatomy.

While not be the first modality of choice in pelvic imaging, MRI is instrumental tool due to its superior soft tissue contrast in providing detailed internal pelvic anatomy. It lacks sonographic limitations of body habitus, depth of ultrasound waves penetration and ability to distinguish tissue types of specific types. Information provided by MRI is vital and may change course of management^{5,9}.

Magnetic resonance imaging identified the uterus, vagina, penis and ovary in 93%, 95%, 100% and 74% of cases respectively. MRI can differentiate between clitoral hypertrophy and penis in female pseudo-hermaphrodite as the former lacks or has poorly developed penile structures³.

In our case MRI accurately described the fluid filled right unicornuate uterus, ovaries, enlarged clitoris and absence of vagina.

References

1. AlJurayyan N. Imaging of disorder of sex development. Ann Saudi Med. 2013 Jul-Aug;33(4):363-7.
2. Al-Jurayyan NAM. Ambiguous genitalia: two decades of experience. Ann Saudi Med. 2011 May-Jun;31(3):284-8.
3. Chavhan GB, et al. Imaging of ambiguous genitalia: classification and diagnostic approach. Radiographics. 2008 Nov-Dec;28(7):1891-904.
4. Choi HK, et al. MR imaging of intersexuality. Radiographics. 2008 Jan-Feb;18(1):83-96.
5. Wasnik AP, et al. Normal and Variant Pelvic Anatomy on MRI. Magn Reson Imaging Clin N Am. 2011;19(3):547-66.
6. Oluwafemi Aj, Et Al. Radiological Evaluation Of Ambiguous Genitalia: A Case Report and Review of Literature. International Journal of Latest Research in Science and Technology. 2014 Jul-Aug;3(4):195-8.
7. Mansour SM, et al. Does MRI add to ultrasound in the assessment of disorders of sex development? Eur J Radiol. 2012 Sep;81(9):2403-10.
8. Moshiri M, et al. Evaluation and management of disorders of sex development: multidisciplinary approach to a complex diagnosis. Radiographics. 2012 Oct;32(6):1599-618.
9. Law YM, Fielding JR. MRI of pelvic floor dysfunction: Review. Am J Roentgenol. 2008;191(6 SUPPL.):45-53.