

Chondromyxoid Fibroma Of Distal 1/3rd Of Fibula A Rare Tumour At Rare Site

K K Mane, S Khan, S Singhanian, M Gudhe, G Mundada, P K Singh, M Arora

Department of Orthopaedics, AVBRH, Sawangi (M), Wardha, Maharashtra, India

Correspondence to: K K Mane, E – mail – karan.mane@gmail.com

Chondromyxoid fibromas are rare, benign tumours account for <1% of primary bone neoplasms. Most commonly affected in 2nd and 3rd of life. We report one such case of chondromyxoid fibroma in distal fibula of a 15-year-old girl. The patient was managed with lower 3rd fibulectomy and fibular turnoplasty from middle 3rd fibula with 1/3rd tubular plate fixation for stabilization followed by bone grafting. The patient is disease free since 3 years.

Key Words: Chondromyxoid fibroma, lower 1/3rd of fibula, Fibular Turnoplasty

DOI: <http://dx.doi.org/10.4314/ecajs.v21i2.18>

Introduction:

Chondromyxoid fibroma is a rare benign bone tumour accounting for <1% of primary bone neoplasms¹. Patients most commonly affected tend to be in their second or third decades of life^{2, 3}. The most common site is around the knee (metaphysis of the tibia or femur) [40%], followed by the foot (17%)⁴. CMF of lower end of fibula accounts for only 0.186 % of all bone tumours⁵. Other frequent sites are the pelvis, spine, and sternum⁵. It presents as a local swelling, persistent pain, and eventually results in pathological fracture. Initially it manifests as a purely osteolytic lesion with a general oval and eccentric form. This area shows sharp outlines and tends to extend to the cortical bone, which may also be scalloped, with no visible signs of periosteal reaction⁵. Histopathologically, the tumour is characterized by slow growth and is generally made up of compact and elastic tissue with a whitish colour, with lobules containing chondroid, myxoid, and fibroid material.

Case Report:

A 15 yrs old female came with complaint of pain in left lower leg for 3 months, which was moderate to, severe in nature. Clinical examination revealed swelling and tenderness on the anterolateral aspect of left lower leg. A diffuse non-tender oval swelling of 6 x 4 cms was present over the left lower leg, lateral aspect, the overlying skin was normal and there was no rise local in temperature. Swelling was fixed to the underlying bone smooth surface, hard and bony in consistency. There were no palpable or audible bruits distal pulsations were palpable.

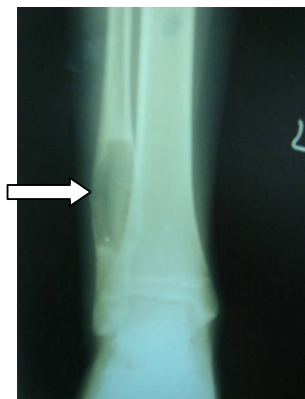

Figure 1. Anteroposterior Radiograph of Ankle suggestive of Osteolytic Lesion in Distal one third of Fibula

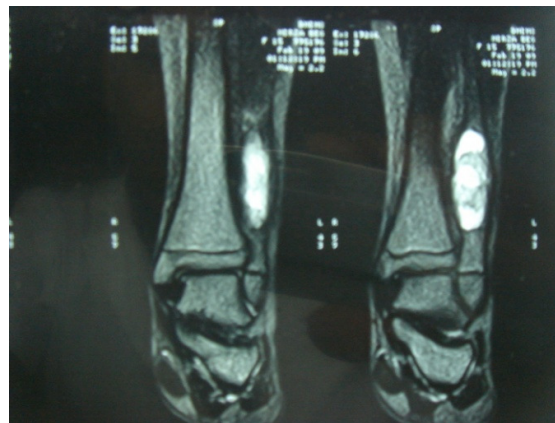

Figure 2. Magnetic Resonance Imaging of the ankle with differential diagnosis of ABC and CMF

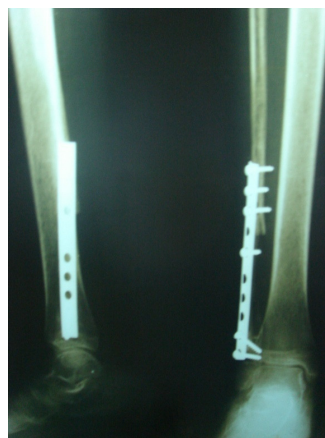


Figure 3. Post-operative X – ray after Tumour Excision

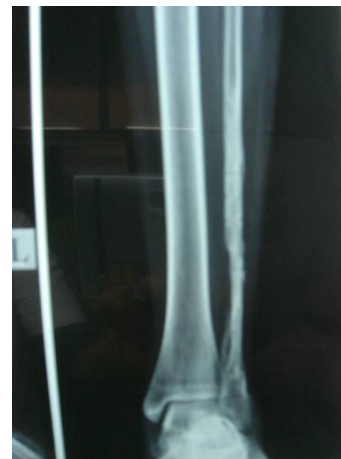

Figure 4. X – ray after implant removal

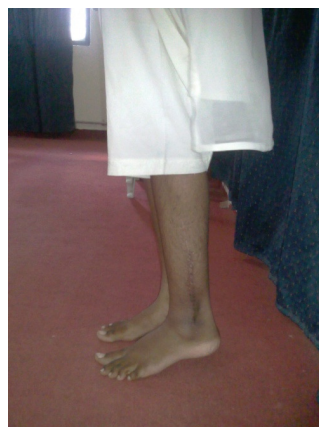

Figure 5. Clinical Picture of Ankle, patient walking full weight bearing

Radiographs showed an osteolytic lesion of the lower end of fibula (Figure 1). MRI was done to make a confirmatory diagnosis and report said aneurismal bone cyst/simple bone cyst (Figure 2). Histopathology was done It consisted of mixture of fibroid myxoid and chondroid areas of varying maturity with increased cellularity at periphery. There are occasional foci of giant cell calcification and irregular nuclei. The patient was planned for operative procedure; lower 3rd fibulectomy was done with fibular turnoplasty from middle 3rd fibula with 1/3rd tubular plate fixation for stabilization (Figure 3). After 6 months the graft was incorporated and after 1 year the implant was removed (Figure 4). 3 years after all these procedures the patient was asymptomatic. Repeat Radiographs were done and there was no sign of recurrence and patient is full weight bearing mobilizing with out any restrictions (Figure 5).

Discussion –

Chondromyxoid fibromas are rare tumours that should form part of the differential diagnosis. Some of the tumours mimicking like CMF include: -

1. Simple bone cyst^{2,6,7}.
2. Aneurysmal bone cyst – usually demonstrates fluid-fluid □levels and periosteal new bone formation without matrix □mineralisation⁸
3. Non-ossifying fibroma – usually no cortical ballooning □or cortical erosion⁸
4. Fibrous dysplasia – usually at a central location without □internal septations. The peak incidence of osteofibrous dysplasia occurs in the first decade of life and the lesions typically demonstrate more sclerosis⁸
5. Giant cell tumour – expansile, lytic tumour that usually extends to the subchondral bone⁸
6. Enchondroma – more classically involves the hands and feet⁷
7. Chondroblastoma – usually epiphyseal lesions with calcified matrix in approximately 50 per cent of tumours⁸

Hence the final, definitive diagnosis is made by clinical, radio- logical and pathological evaluation of tumour characteristics. Histologically the tumour consists of primitive cartilaginous tissue, fibrous tissue as well as immature myxoid tissue that may, histologically, mimic a chondrosarcoma thus necessitating imaging modalities (X-ray, CT and MRI) to aid in the final diagnosis. With above discussion we are stressing upon the need to include this lesion in painful radiologically lytic lesion of the bone even though these tumours are very rare and often misdiagnosed radiologically.

References

1. Jaffe HL, Lichtenstein L. Chondromyxoid fibroma of bone: a distinctive benign tumor likely to be mistaken especially for chondrosarcoma. Arch Pathol (Chic) 1948;45:541–51.
2. Adam A, Dixon AK. Grainger & Allison's Diagnostic Radiology. 5th ed. In: Stoker DJ, Saifudin A. *Bone Tumors: General Characteristics and Benign Lesions*. Philadelphia: Elsevier Churchill Livingstone; 2008: 1039-41.
3. Stoller DW, Tirman PFJ, Bredella MA. Diagnostic Imaging Orthopaedics. Salt Lake City: Amirsys; 2004: 8/30-8/33.
4. Fahmy ML, AlRayes M, Iskaf W, Hammouda A. Chondromyxoid fibroma of the foot: case report and literature review. Foot 1998;8:106–8.
5. Campanacci. Bone and soft tissue tumors. Piccin Nuova Libreria: Padova; 1999:265–77.
6. Dähnert W. Radiology Review Manual. 6th ed. Philadelphia: Lippincott Williams & Wilkins; 2007: 57- 8.
7. Greenspan A. Orthopedic Imaging. 4th ed. Philadelphia: Lippincott Williams & Wilkins; 2004: 617-22.
8. Stoller DW, Tirman PFJ, Bredella MA. Diagnostic Imaging Orthopaedics. Salt Lake City: Amirsys; 2004: 8/30-8/33.