

Short communication

***Cassia alata* alters Liver Structure in Rat**

¹Amao S.Y, ¹Ajani R.S and ^{1,2}Oladapo O

Departments of Anatomy¹, and Medicine²; College of Medicine, University of Ibadan, Nigeria

ABSTRACT: *Cassia alata* is a common plant in South West and its parts are freely used as herbs by the natives. Concomitantly, the prevalence of chronic liver disease is on the increase, thus the study was designed to investigate the effects of its crude extract on the rat liver structure. The methanolic extract of *cassia alata* was administered orally to three randomly grouped wistar rats with a weight range of 160-260 grammes for twenty one days. Each group had four animals and the fourth group served as control. The three groups received 50g/kg body weight, 100g/kg and 150 g/kg respectively of the methanolic extract. Lethargy was observed amongst the animals that had the extract. All the four groups had positive percentage mean group weight change (Group A 10.5, Group B 10, Group C 10.5 and Group D 29.4; Group A being the control). Microscopic anatomy of the liver of the rats revealed evidence of chronic inflammatory response that was most severe in the Group D wistar rats, the group that received the largest dose of the methanolic extract. The study was able to demonstrate that *Cassia alata* is capable of causing chronic liver injury in rats

Keyword: *Cassia alata*, rat liver, histoarchitecture

INTRODUCTION

The use of various parts of plants for the treatment of diseases and injuries that afflict mankind is not only well known but also common and is as old as the existence of man on Earth. *Cassia alata*, either its leaves or bark has been used and is still being used globally (Sofowora 1986, Khan 2001, Kulip 1997) for the treatment of various human ailments including dermatological and gastrointestinal disorders.

In Nigeria, and particularly amongst the people of South West Nigeria, leave extracts of *Cassia alata* is

applied topically to treat certain dermatological conditions such as eczema, scabies and ring worm. It is also used as a purgative .

Previous studies have elucidated the active fractions of the plant (Watt 1962) some of which are toxic. Since the pattern of usage does not allow for dose estimation, the cumulative toxic effects cannot be ignored. Thus there is the need to evaluate the toxicity on certain metabolic organs such as the liver.

The incidence of chronic liver diseases in Nigeria is on the rise. Hepatocellular carcinoma is the commonest male cancer in Africa. In most cases it is secondary to liver cirrhosis which is commonly due to Hepatitis B infection and aflatoxicosis from consumption of contaminated grains (Llovet 2003). The liver is a major metabolic organ thus the investigation of hepato-toxicity of *Cassia alata* in wistar rat may help to suggest likely toxicity in human liver. This will help to stem the tide of the rising incidence of chronic liver disease whose management is largely palliative rather than being curative.

The rationale for the study is to evaluate the effects of methanolic extract of *Cassia alata* on the morphology and histoarchitecture of wistar rat liver

*Address for correspondence: rsaajani@yahoo.co.uk
Phone: +2348023007362

MATERIALS AND METHODS

The methanolic extract of *C. alata* (MECA) was obtained from the dried leaves using Soxhlet technique. Twenty (20) adult wistar rats (160-260g) were randomly divided to four equal groups, Group A, which served as the control, received normal rat feed and water ad libitum. Groups B, C and D received 50mg/kg, 100mg/kg and 150mg/kg of MECA (p.o) respectively. The body weights of the rats were monitored prior to and throughout the period of treatment. Twenty two days into treatment all the rats were sacrificed. The liver of each animal was removed and fixed in 10 % formaldehyde. Microscopic slides using hematoxylin and eosin stain were prepared from all the harvested liver tissues.

RESULTS AND DISCUSSION

The group C and D animals exhibited evidence of lethargy as shown by sluggishness, reduced appetite and weight loss. This could be attributed to toxicity (these animals had higher than normal doses). This

finding is in consonance with previous studies (Sodipo 1998). Previous toxicity studies (Sodipo 1998, Adefemi 1998) of *C.alata* could not elucidate the safe dose but rather they were able to demonstrate that the duration of administration of the extract is very important in toxicity. In this study, all the animals gained weight also the percentage mean weight change in all the groups was positive. This may imply that the extract is neither catabolic nor anorexic.

Microscopic slides prepared from the liver of the animals that received the extract showed inflammatory response whose severity has a direct relationship with the concentration of extract administered.

From the foregoing, one can infer that the extent of microscopic injury is directly proportional to the amount of extract administered since the magnitude of any inflammatory response depends of the severity of the injury, insult or pathology that potentiated it. Also it is well known that most chronic liver pathologies (chronic active hepatitis, cirrhosis, hepatoma) usually have an inflammatory reaction in the early phase of their aetiopathogeneses. One can deduce that a lifelong administration of the extract in rats may result in irreversible progressive liver pathology.

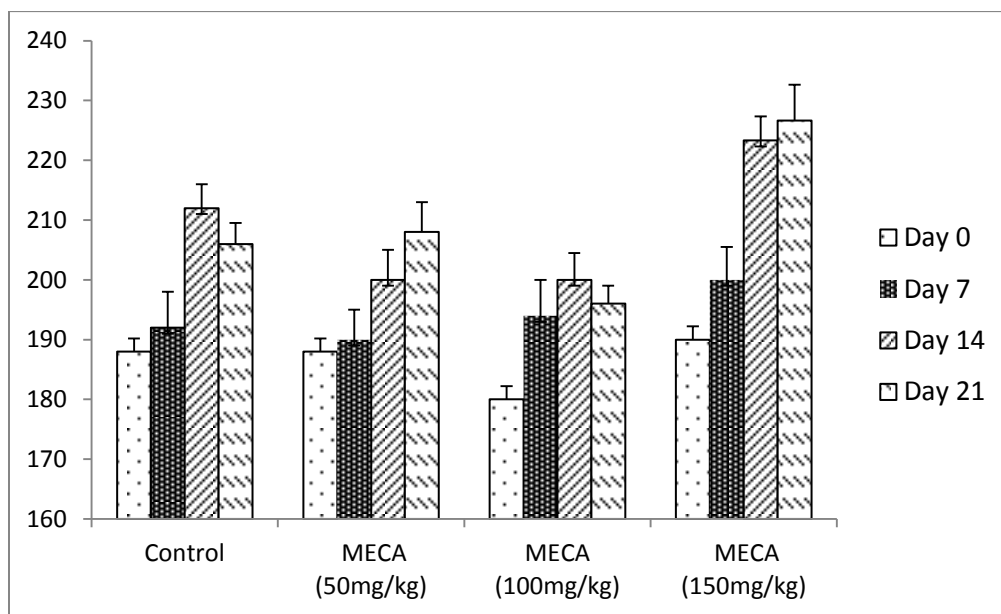


Fig. 1

Effect of the methanol extract of *Cassia alata* (MECA) on body weight changes in rats. Control animals received distilled water. Each bar represents the mean \pm SEM of five rats in each group.

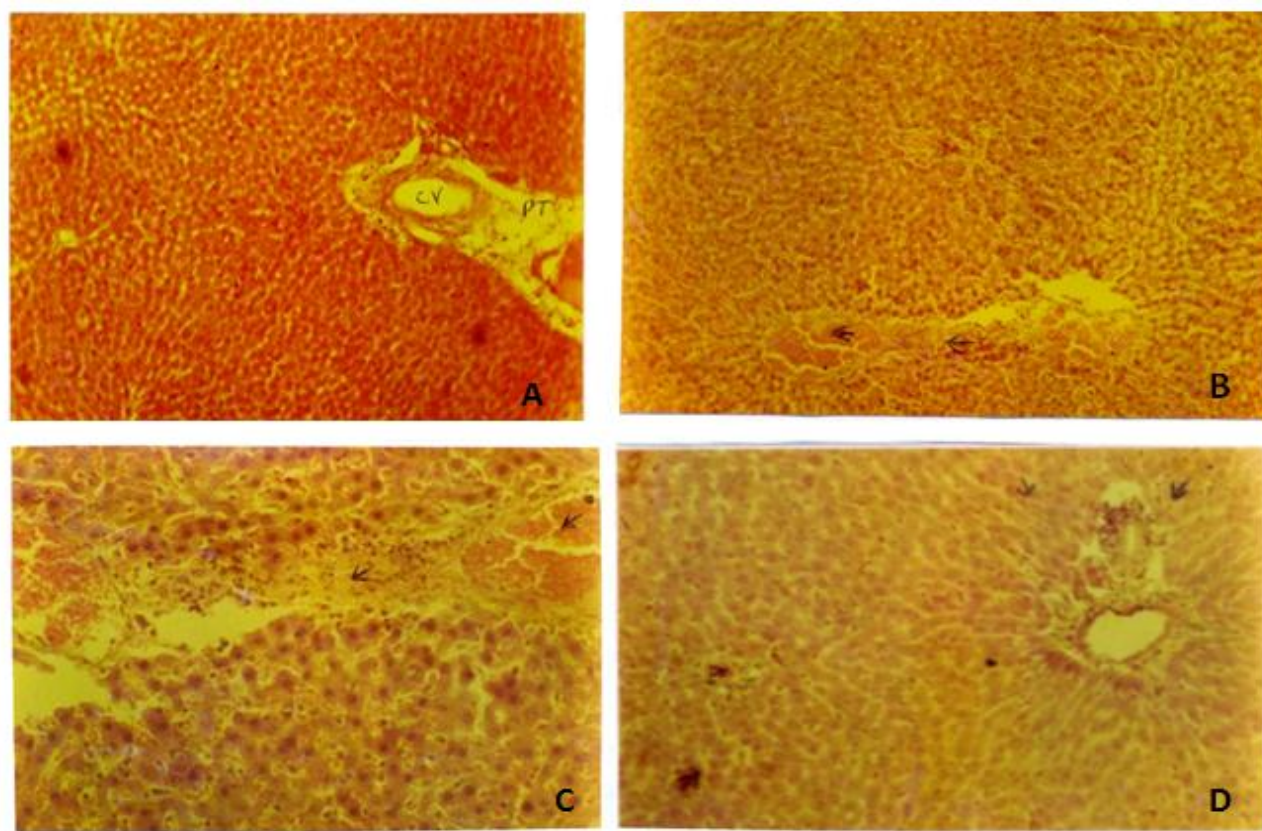


Fig.1. A photomicrograph of liver of control (A) and *Cassia alata* treated rats (B, C and D) showing the presence of numerous inflammatory cells in the treated groups. H & E, X100

Amongst Nigerians, the use of *C.alata* either as herbal preparation or as leaf extract has no dosage or duration of administration. It is either applied topically or ingested. Either route, the active ingredients get to the liver where it will be metabolised. Most cutaneous fungal infections require treatment for at least three weeks and worst still; the recurrent rates are pretty high. Thus the habitual users of *Calata* are exposed to the danger of accumulation and thus to the possibility of liver injury

This study has been able to indirectly demonstrate the ability of methanolic extract of *C. alata* to cause liver injury with a severity that is dose dependent in wister rats. It can thus be reasonably concluded that cumulative effect of *C.alata* in humans may result in liver injury. This may be contributory to the increasing incidence of chronic liver diseases in our environment. Further studies using bigger rodents and longer periods of administration may be helpful to firmly establish the ability of *C. alata* to cause chronic irreversible and progressive hepatocellular damage.

Finally while it is impossible to eradicate the use of crude leaves extracts by the Natives due to a legion of reasons (cultural and socioeconomical) , they need to

before warned against the inherent on the inherent danger of habitual and excessive usage of *c.alata*

REFERENCES

- Adefemi OA, Elujoba AA and Odesanmi WO.(1998):** Evaluation of the potentials of *Cassia pordocarpa* with reference to official senna. *West Afri J. Pharmacol. Drug Res.* ; 8:41-8
- Khan MR, Kihara M and Omotoso AD.(2001):** Antimicrobial activity of *Cassia alata*. *Fitoterapia* ; 72 (5): 561-4
- Kulip YA.(1997):** Preliminary survey of traditional medicinal plants in the west Africa coast and interior of sabah. *J Trop forest Sci*; 10 (2) 271-4
- Llovet JM,Burroughs A and Bruix J. (2003):**Hepatocellular carcinoma. *Lancet* ; 362:1907-17
- Sodipo AA, Effraim KD and Emmagun E. (1998):** Effects of aqueous leaf extract of *Cassia alata* on some haematological indices in albino rats. *Phytotherapy Res* ; 12 (6):431-33
- Sofowora A.(1986) :**The State of Medicinal Plant Research in Nigeria.1st Edition. University Press, Ibadan, Nigeria :86.
- Watt YM and Brayer-Brand MG.(1962):** The medicinal and Poisonous Plants of Southern and Eastern Africa Living stone, Edinburgh and London.