

www.ajbrui.net

Afr. J. Biomed. Res. Vol.17 (September, 2014); 193- 201

Full Length Research Paper

Anti-ulcerogenic Activity of *Aspilia Africana* Leaf Extract: Roles of Gastric Acid, Oxidative Stress and Neutrophil Infiltration

Ajeigbe K.O^{1, 4*}, Onifade A.A³, Omotoso D.R², Enitan S.S¹ and Olaleye S.B⁴

Department of ¹Physiology and ²Anatomy, Igbiniedion University, Okada.

³Immunology Unit, Department of Chemical Pathology, College of Medicine, University of Ibadan

⁴Gastrointestinal Secretion and Inflammation Research Unit, Department of Physiology, College of Medicine, University of Ibadan. Ibadan, Nigeria

ABSTRACT

Aqueous decoction of *Aspilia africana* C.D Adams (Asteraceae) is an effective antiulcer agent in Southern Nigeria, but little is known about the possible underlying mechanisms. This study investigated the role of gastric acid, neutrophil infiltration and oxidative stress in the anti-ulcerogenic properties of aqueous leaf extract of *Aspilia africana* (ALEAA) in rats. Male albino rats were treated with 250, 500, 750 mg/kg ALEAA for 21 days. Gastric ulceration was induced by indomethacin, scored, and assayed to determine the concentration of malondialdehyde (MDA), catalase (CAT) and superoxide dismutase (SOD) in homogenized samples. Acid output was measured by pyloric ligation method while neutrophil infiltration evaluated by histometry. Indomethacin caused gastric ulcer with an index of 7.50 ± 0.23 , increase in MDA concentration and reduction in the concentration SOD and CAT ($p < 0.05$). Pre-treatment with 500 and 750 mg/kg of ALEAA prevented ulcer formation by 45% and 62%, and lipid peroxidation 51% and 57% respectively while SOD and CAT increased in a similar manner. Also, acid output significantly reduced in the 500 and 750 mg/kg ALEAA treated rats by 25% and 36%. Neutrophil infiltration of the ulcerated stomach pre-treated with the three doses decreased (21.5 ± 1.40 cells/field, 15.0 ± 2.50 cells/field, and 11.3 ± 1.00 cells/field versus 42.7 ± 5.50 cells/field). *Aspilia africana* enhanced gastroprotection via reduction of acid output, neutrophil infiltration and oxidative stress.

Key words: Gastroprotection, acid output, Lipid peroxidation

INTRODUCTION

Gastric ulcer is a break or defect in the normal gastric mucosa integrity, which extend through the muscularis mucosa into submucosa or deeper. It is known to result when aggressive factors (endogenous, exogenous and/or infectious agent) overcome mucosal defense

mechanisms in the stomach (Allen and Garner, 1980; Wallace, 1992; Tulassay and Herszenyi, 2010).

Endogenous aggressive factors include gastric acid, pepsin, refluxed bile, leukotrienes, abnormal motility, Reactive Oxygen Species etc., while *Helicobacter pylori* infection, indiscriminate use of NSAIDs, alcohol abuse, stress, smoking and lifestyle factors constitute part of the exogenous aggressive factors. Mucosal defense

*Corresponding author:

E-mail: kazeemajeigbe@gmail.com

Tel: +2348035705220

Date Received: December, 2013

Date Accepted: June, 2014

Abstracted by:

Bioline International, African Journals online (AJOL), Index Copernicus, African Index Medicus (WHO), Excerpta medica (EMBASE), CAB Abstracts, SCOPUS, Global Health Abstracts, Asian Science Index, Index Veterinarius

mechanisms which protect the integrity of the stomach wall, on the other hand, are mucus-bicarbonate barrier, prostaglandin, mucosal blood flow, cell renewal and migration, antioxidants, and some growth factors.

Peptic (gastric and duodenal) ulcer disease is a serious and growing global health problem. It is estimated that 10% of whole world affected (Uyanikoglu *et al.*, 2011) and 4 million new cases develop every year (Zelickson *et al.*, 2011). Besides, it is the most predominant of gastrointestinal diseases, 40% in developed and 80% in developing countries due to indiscriminate NSAIDs use and *Helicobacter pylori* infection respectively (Malfertheiner *et al.*, 2009). Due to its high morbidity, mortality and economic loss (Dimaline and Varro, 2007), the search for anti-ulcer herbal agents remain inexhaustible because they are considered and generally accepted as safer, more accessible and more cost effective than conventional therapy against ulcer (Al Mofleh, 2010). The protective effects of several medicinal plant species have been investigated for anti-ulcer properties. Such plants include *Egletes viscosa* Less (Asteraceae) (Rao *et al.*, 1997), *Garcinia kola* Heckel (Guttiferae) seeds (Ibironke *et al.*, 1997), *Landolphia owarensis* P. beaur. (Apocynaceae) (Olaleye *et al.*, 2008), *Matricaria chamomilla* L. (Asteraceae) (Cemek *et al.*, 2010), *Momordica charantia* L. (Cucurbitaceae) (Alam *et al.*, 2009) etc. In fact, a growing body of evidence from both experimental and clinical studies has shown that anti-ulcer activity of some plants involves antisecretory, cytoprotective and/or antioxidant effect as underlying mechanisms of action.

Another plant that has been reported to be gastroprotective is *Aspilia africana*. It is a semi woody herb occurring throughout the regions of the savannah and tropical Africa on wastelands (Hutchinson, 1962). It is known by various names among the Nigerian populace (*Orangila* in Igbo, *Tozalin* in Hausa and *Yunyun* in Yoruba). The plant has been reported in literature to possess antimicrobial (Macfoy and Cline, 1990), anti-fertility (Eweka, 2007), haemostatic and anti-inflammatory (Okoli *et al.*, 2007) activity. Phytochemical analysis of the plant reveals that it is rich in flavonoids, saponin, tannins, glycoside and alkaloids (Adeniyi and Odufowora, 2000; Iwu, 1993). Kuate *et al.* (1999) reported the presence of four essential oils obtained by hydrodistillation from the leaves of *Aspilia africana*. These oil samples include sesquiterpenes, monoterpenes, germacrene and alpha-pinenene. Although Nguelefack *et al.* (2005) and Okoli *et al.* (2007) reported the anti-ulcer and wound healing activity of n-hexane and methanol leaf extracts of *Aspilia africana*, the mechanistic events involved in the process is still

unknown. Since gastric acid secretion, oxidative stress and neutrophil activation/infiltration have all been implicated in the pathogenesis of peptic ulceration, it is pertinent to investigate the said anti-ulcer activity of the plant in this light. Besides, many anti-ulcer drugs employed at least one of these mechanisms to cure the disease (Schmassmann, 1998; Al Mofleh, 2010). We therefore, aimed to evaluate comprehensively the anti-secretory, cytoprotective and/or anti-oxidative potentials of *Aspilia africana* as possible mechanisms for its anti-ulcer activity using indomethacin ulcer model. This will underscore the gastroprotective properties of the plant, and further strengthen its virtue as a good anti-ulcer agent.

MATERIALS AND METHODS

Animals

Forty-two male albino rats weighing 150-170 g were purchased from the Central Animal Facility, College of Health Sciences, Igbinedion University Okada, Nigeria, and kept in plastic cages under hygienic conditions, with proper aeration at $25 \pm 2^\circ\text{C}$, and a relative humidity of 45 - 50%. The rats were fed on standard rat diet produced by Bendel Feed and Flour Mills Limited twice daily and tap water *ad libitum*. Prior to commencement of administration, the rats were allowed to stabilize in the Animal House with standard 12 h light-dark cycle, for a period of 14 days. The Animal Care and Ethics Committee of Igbinedion University, Okada approved the experimental protocols.

Preparation of Aqueous *Aspilia africana* Extract

A bulk of fresh *Aspilia africana* leaves (single batch) sufficient for the study was collected from the field after authentication at the herbarium of the Department of Pharmacognosy, Igbinedion University, Okada where a voucher specimen is deposited. The leaves were air-dried at room temperature and pulverized to fine powder. The extraction was carried out using Soxhlet extractor with water as solvent. The extract was then concentrated to approximately 10% of the original volume using a rotary evaporator (BUCHI, type RE111, Rotavapor).

Experimental Protocol

The animals for the ulcer studies were randomly assigned into five (6) groups of seven rats each ($n = 7$) and treated as follows:

Group 1: Control group, received distilled water.

Group 2: Indomethacin (25 mg/kg) only

Group 3: 250 mg/Kg/d (ALEAA) + Indomethacin (25 mg/kg)

Group 4: 500 mg/Kg/d (ALEAA) + Indomethacin (25 mg/kg)

Group 5: 750 mg/Kg/d (ALEAA) + Indomethacin (25 mg/kg)

Group 6: Omeprazole (20 mg/kg) + Indomethacin (25 mg/kg)

Oral gavage using metal oral cannula and calibrated hypodermic syringe was employed in the administration of the aqueous extract of *Aspilia africana* once daily for twenty-one (21) days at the volume of 1 ml/100 g body weight. Indomethacin was dissolved in 5% sodium bicarbonate to form a clear solution. All the animals were sacrificed under sodium pentobarbitone anaesthesia.

Ulcer Induction and Index determination:

Four hours after the oral administration of indomethacin, the stomachs were opened along the greater curvature, washed in normal saline to remove debris and pinned on a cork mat for ulcer scoring. This was done by locating the wounds in the glandular region under a simple microscope. The length (mm) of all the elongated black-red lines parallel to the long axis of the stomach in the mucosa was measured. Index of ulceration was calculated as the total lesion lengths divided by the number in each group (Ajeigbe *et al.*, 2011). After the measurement of the ulcer index, gastric tissues were excised for biochemical and histopathological evaluation as briefly described below:

Biochemical Analysis:

Determination of malondialdehyde (MDA). The assay method of Hunter *et al.*, (1976) modified by Gutteridge & Wilkins (1982) was adopted. Malondialdehyde (MDA), a product of lipid peroxidation, when heated with 2-thiobarbituric acid (TBA) under acid conditions forms a pink colored product which has a maximum absorbance of 532 nm. The stomach homogenate was supplemented with 1 g of TBA in 100 ml of 0.2% Sodium Hydroxide (NaOH) and 3 ml of glacial acetic acid, thoroughly mixed, and incubated in boiling water bath for 15 min. It was then allowed to cool, and centrifuged. Absorbance was read at 532 nm and the results expressed as nanomoles MDA/mg wet tissue.

Determination of catalase activity.

Activity of catalase in gastric mucosa was determined according to the procedure of Sinha (1972). This method is based on the reduction of dichromate in acetic acid to chromic acetate when heated in presence of hydrogen peroxide (H₂O₂), with the formation of perchromic acid as an unstable intermediate. The chromic acetate so

produced is measured. Absorbance was read at 480 nm within 30-60 seconds against distilled water.

Determination of superoxide dismutase (SOD) activity.

A method originally described by Misra and Fridovich (1972) as reported by Magwere *et al.*, (1997) was employed. The homogenate was supplemented with 2.5 ml of carbonate buffer, followed by equilibration at room temperature; 0.3 ml of 0.3 nM adrenaline solution was then added to the reference and the test solution, followed by mixing and reading of absorbance at 420 nm.

Histopathological studies:

Histological studies were performed according to the method previously described by Ogihara and Okabe, (1993). At autopsy, small pieces of tissues including ulcers were embedded in paraffin and sectioned at 5 µm in an automated microtome. Haematoxylin and eosin staining were done to determine neutrophil infiltration (Haber and Lopez, 1999), and inflammatory cells infiltration assessment done subjectively using the scale: 0 = no infiltration; 1 = very mild infiltration; 2 = mild infiltration; 3 = moderate infiltration; 4 = marked infiltration (Trevethick *et al.*, 1993).

Pyloric ligation acid secretion studies:

Gastric acid collection was done previously described by Olaleye *et al.* (2008). Briefly, an abdominal incision through the *linea alba* was made to expose the stomach and a ligation was made at the junction of the pylorus with the duodenum. The 4 h gastric secretion collection was drained into a graduated test tube and centrifuged at 2000 rpm for 10 min. The supernatant volume and pH were recorded. The total acid content of the gastric secretions was also determined by titration to end point (pH 7.0) with 0.1 N NaOH, using phenolphthalein as an indicator.

Blood Neutrophil count evaluation:

Before sacrifice, the animal's thorax was opened and approximately 2 ml of blood were withdrawn by cardiac puncture (using a 21 gauge butterfly needle) and added to vials containing EDTA as an anti-coagulant. Haematological indices were determined using the Sysmex® Automated Haematology Analyzer KX-21N, Sysmex Corporation, (Kobe-Japan) as described by Samuel *et al.* (2010). The auto-analyzer was operated as instructed in the User's operational manual.

Statistical Analyses

Data are presented as Mean ± SEM and subjected to one way analysis of variance (ANOVA) and Tukey test

using Graphpad prism version 4.0 for windows from GraphPad software, San Diego, California, USA. P values < 0.05 were regarded significant.

RESULTS

Effect of ALEAA on Development of Gastric Lesions:

Indomethacin caused severe damage to glandular stomach of the rat with an ulcer index of 7.50 ± 0.23 , increase in MDA concentration and reduction in the concentration of catalase and superoxide dismutase ($P < 0.05$). Pre-treatment with 250, 500 and 750 mg/kg

ALEAA prevented the formation of ulcers by 32, 45 and 62% respectively (Figure 1).

Effect of ALEAA on Lipid peroxidation and Antioxidant Enzymes

Lipid peroxidation induced by indomethacin with a value of 5.489 ± 0.20 nmol/mg. MDA concentrations was attenuated by 51 and 57% reduction on pre-treatment with 500 and 750 mg/kg of the extract. Also, attenuated significantly was the inhibition of CAT and SOD in a dose-dependent manner (Table 1).

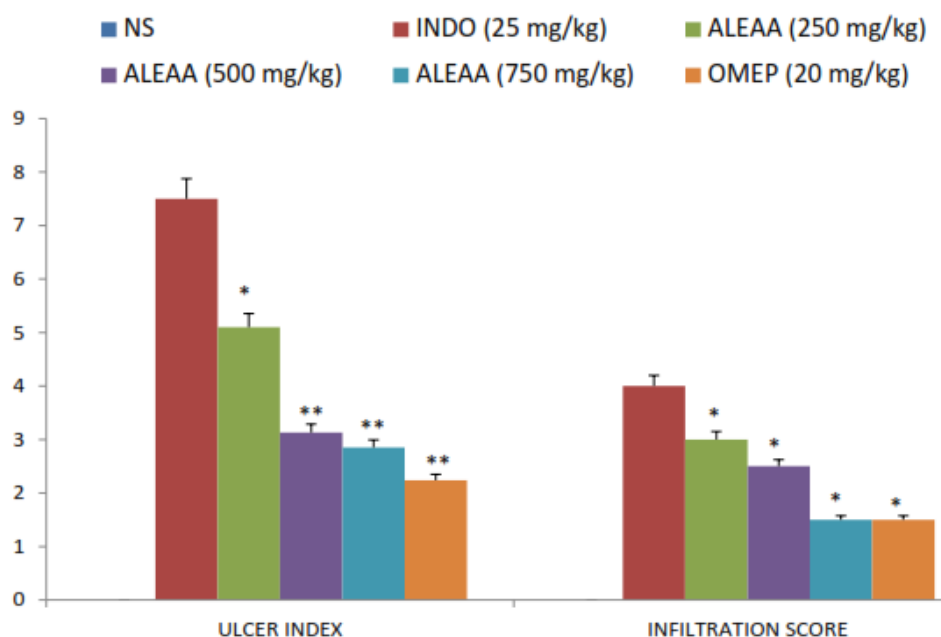


Figure 1:

Effect of varying doses of Aqueous Leaf Extract of *Aspilia africana* (ALEAA) on indomethacin induced gastric ulcer: ulcer severity and inflammatory cells infiltration score (* $p < 0.05$, ** $p < 0.001$ cf ulcer control) NS= Normal saline, INDO=Indomethacin, OMEP=Omeprazole.

Table 1:

Effect of varying doses of Aqueous Leaf Extract of *Aspilia africana* (ALEAA) on indomethacin induced gastric ulcer: lipid peroxidation and antioxidant enzymes

Group	Treatment	MDA (nmol/mg)	SOD (mmol/mg)	CAT (μ mol/mg)
1	Normal saline (1 ml/Kg b.w)	2.511 \pm 0.10	1.583 \pm 0.12	0.845 \pm 0.01
2	Indomethacin (25 mg/kg b.w)	5.489 \pm 0.20 ^a	0.227 \pm 0.05 ^a	0.401 \pm 0.10 ^a
3	ALEAA (250 mg/Kg b.w) +Indo (25 mg/kg)	5.257 \pm 0.35	0.421 \pm 0.03 ^b	0.405 \pm 0.03
4	ALEAA (500 mg/Kg b.w) + Indo (25 mg/kg)	2.690 \pm 0.10 ^b	0.600 \pm 0.02 ^b	0.526 \pm 0.02 ^b
5	ALEAA (750 mg/Kg b.w)+Indo (25 mg/kg)	2.360 \pm 0.15 ^b	0.725 \pm 0.04 ^b	0.532 \pm 0.17 ^b
6	Omeprazole (20 mg/kg b.w)+Indo (25 mg/kg)	2.005 \pm 0.10 ^c	0.815 \pm 0.05 ^c	0.640 \pm 0.20 ^c

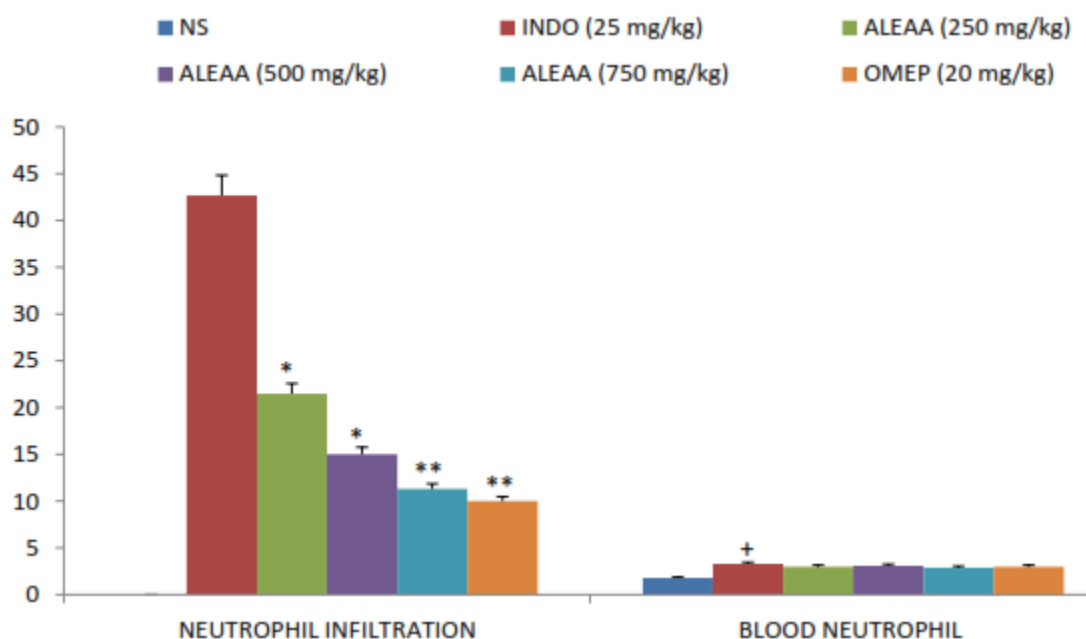
^a $P < 0.05$, indomethacin versus control group; ^b $P < 0.05$, ALEAA+ indomethacin versus indomethacin only; ^c $P < 0.05$, Omeprazole + indomethacin versus indomethacin only. (Mean \pm SEM, $n = 7$). Where, MDA = malondialdehyde, CAT = catalase, SOD = superoxide dismutase

Table 2:

Effect of varying doses of Aqueous Leaf Extract of *Aspilia africana* (ALEAA) on indomethacin induced gastric ulcer: gastric juice volume, pH and acid output.

Group	Treatment	Gastric juice volume (ml/4h)	pH	Acid output (X10 ⁴ mmol/4h)
1	Normal saline (1 ml/Kg b.w)	3.80±0.15	2.60±0.10	5.20±0.12
2	Indomethacin (25 mg/kg b.w)	6.10±0.20 ^a	1.25±0.20 ^a	8.15±0.05 ^a
3	ALEAA (250 mg/Kg b.w) +Indo (25 mg/kg)	6.00±0.10	1.50±0.35	6.50±0.03 ^b
4	ALEAA (500 mg/Kg b.w) + Indo (25 mg/kg)	5.20±0.12 ^b	2.00±0.10 ^b	6.10±0.02 ^b
5	ALEAA (750 mg/Kg b.w)+Indo (25 mg/kg)	4.10±0.10 ^b	2.40±0.15 ^b	5.20±0.04 ^b
6	Omeprazole (20 mg/kg b.w)+Indo (25 mg/kg)	3.50±0.05 ^c	2.90±0.10 ^c	4.50±0.05 ^c

^a*P* < 0.05, indomethacin versus control group; ^b*P* < 0.05, ALEAA+ indomethacin versus indomethacin only; ^c*P* < 0.05, Omeprazole + indomethacin versus indomethacin only. (Mean ± SEM, *n* = 7).

**Figure 2:**

Effect of varying doses of Aqueous Leaf Extract of *Aspilia africana* (ALEAA) on indomethacin induced gastric ulcer: neutrophil infiltration (cells/field) and blood neutrophil level (X10³/UL) (**p*<0.05, ***p*<0.001 cf ulcer control; (+*p*<0.05 cf NS) NS= Normal saline, INDO=Indomethacin, OMEP=Omeprazole.

Effect of ALEAA on gastric juice profile

Pylorus ligation for 4 h resulted in the accumulation of gastric secretion and increase in the titratable acidity. The extracts produced dose-dependent significant decrease in gastric juice volume, pH and acid output (Table 2).

Histopathological Examination: Effect of ALEAA on neutrophil infiltration

Aqueous leaf extracts of *Aspilia africana*, at 250, 500 and 750 mg/kg produced a significant decrease in the neutrophil counts of the ulcerated stomach pre-treated with the three doses of ALEAA (21.5 ± 1.40 cells/field, 15.0 ± 2.50 cells/field, 11.3 ± 1.00 cells/field versus

42.72 ± 5.50 cells/field) (Figure 2). Indomethacin caused mucosal cytoarchitectural damage with pronounced inflammatory cells infiltration, which is significantly remedied by ALEAA.

Effect of Aqueous Leaf Extract of *Aspilia africana* (ALEAA) on blood neutrophil count

Indomethacin caused a significant increase in the number of circulating neutrophils when compared with the overall control group treated with normal saline (3.3 x 10³/UL versus 1.8 x 10³/UL). However, pre-treatment with the three doses of extract revealed no significant difference in the ulcerated animals (Figure 1).

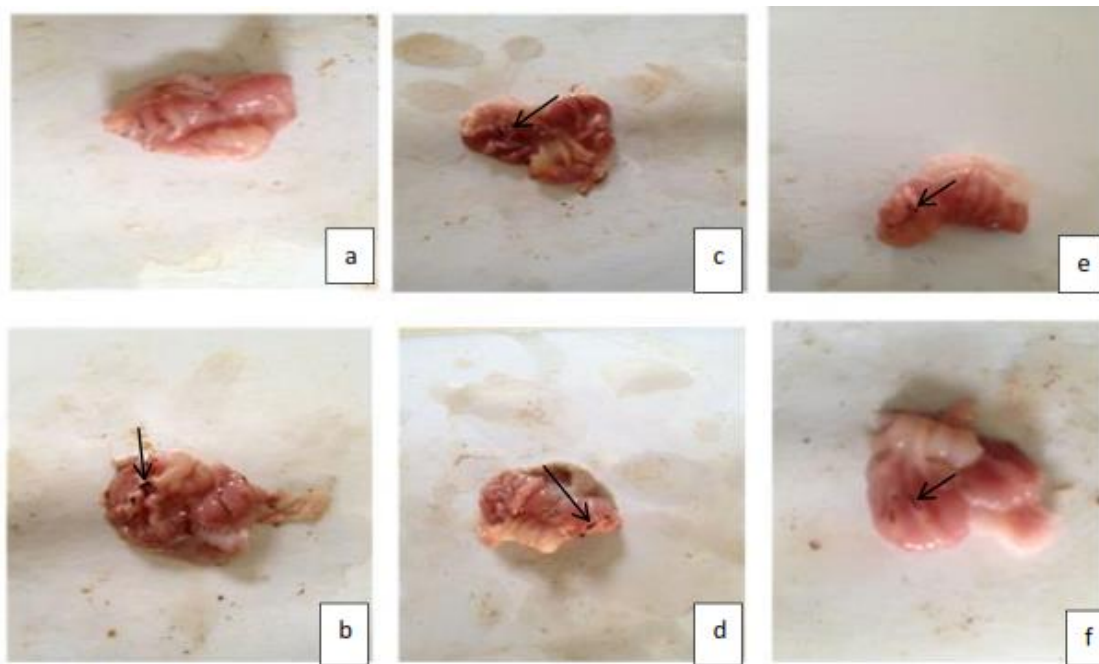


Plate 1:

Macroscopic inspection of the effects of *Aspilia africana* on indomethacin-induced gastric lesions in the rat. A=overall control; b= ulcer control (indomethacin (25 mg/kg) only), c=250 mg/kg ALEAA + indomethacin, d=500 mg/kg ALEAA + indomethacin, e=750 mg/kg ALEAA + indomethacin, f=omeprazole (20 mg/kg) + indomethacin

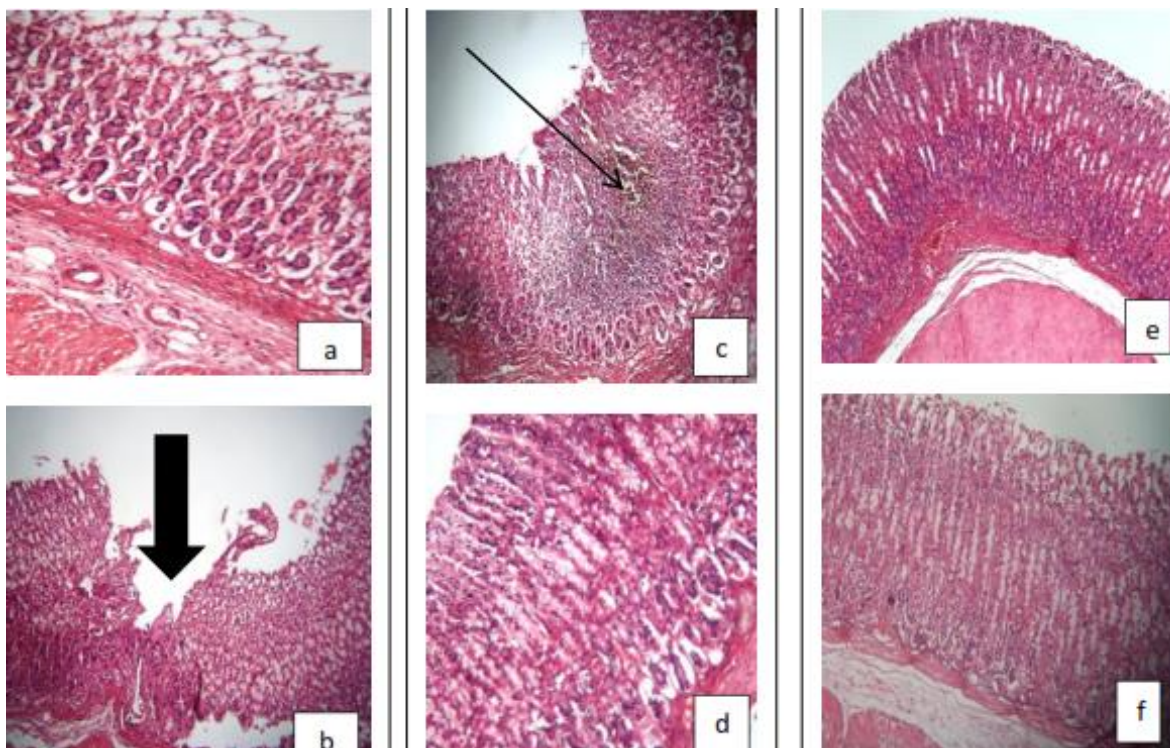


Plate 2:

Histological evaluation of rats' gastric tissues treated with varying doses of aqueous extract of *Aspilia africana* following indomethacin (H&E, X40):

a (overall control) = Normal mucosa and submucosa. b (Ulcer control) = Focal areas of ulceration of the whole mucosa which has undergone degenerative changes. c (250 mg/kg ALEAA) = Ulceration of the mucosa layer accompanied by necrotic tissue. d (500 mg/kg ALEAA) = Constriction of gastric glands above the muscularis mucosa and the gastric glands show vesicular nuclei with no ulcer. E (750 mg/kg) = Mild inflammatory cells in the submucosa with no ulcer. f (omeprazole) = The parietal cells show vesicular nuclei and there is mild constriction of the gastric glands above the muscularis mucosa.

DISCUSSION

Although *Aspilia africana* is used to treat different diseases in different ecological zones perhaps due to varying chemical composition (Oliver, 1960; Page, 1992), its leaves is claimed to be effective in the treatment of stomach ache and bleeding gastric ulcers especially when taken as aqueous decoction in Southern Nigeria (Omokehinde *et al.*, 2014). A number of scientific reports have presented its anti-ulcer activity in the literature but mechanism underlying the protective effect is still unclear. In the present study, we examined the antisecretory and cytoprotective potentials of the plant using indomethacin ulcer model. It is the most commonly used ulcer model in antiulcer studies probably because NSAIDs are the second most common cause of peptic ulcers aside those caused by *Helicobacter pylori* (Musumba *et al.*, 2009).

The molecular basis of NSAID induced gastropathy is widely ascribed to their inhibitory activity against cyclooxygenases, which causes them to block the prostaglandin synthesis leading to increased gastric acid, reduction of gastric mucosal blood flow, disturbance of microcirculation, increased leukocyte adherence, lipid peroxidation and neutrophil infiltration (Wallace, 2001; Naito and Yoshikawa, 2006).

The findings of the present study show that aqueous leaf extract of *Aspilia africana* prevents the formation of ulcer, reduces acid output and infiltrating neutrophil, and ameliorate the induced oxidative stress in the rat stomach.

First, gastric (hydrochloric) acid, produced by the parietal cells in the stomach, is finely regulated by overlapping neural, hormonal, paracrine pathways (Yao and Forte, 2003). When levels of the acid and proteolytic enzymes overwhelm the mucosal defense mechanisms, ulcers occur; and conversely reducing the rate of acid secretion is an important factor in anti-ulcerogenesis (Schmassmann, 1998). We observed, in the study, an elaboration of gastric juice volume, reduced pH with a corresponding increased titratable acid content in the indomethacin treated upon pylorus ligation. This is expected because prostaglandin is known to be a natural inhibitor of gastric acid secretion (Choquet *et al.*, 1993; Kato *et al.*, 2005), as it facilitates the production of mucus and bicarbonate. Hence, the inhibition of prostaglandin synthetase in the cyclooxygenase pathway to produce prostaglandin results in elaboration of gastric acid (Rainsford, 1987). However, the aqueous leaf extract of *Aspilia africana* attenuated the increase in acid output in a dose-dependent fashion. The value observed for the stomach pre-treated with 750 mg/kg of the extract is found to be even comparable with Omeprazole, the standard anti-ulcer (anti-secretory) drug used in the study. This implies that the plant has antisecretory

property attributable to parietal cell activity inhibition and/or cyclooxygenase (COX-1) stimulation.

Aside increase in acid output, lipid peroxidation, a result of the reaction between reactive oxygen species and the polyunsaturated fatty acids, is also an important aggressive factor on the gastric mucosa. When the oxygen metabolites overwhelm the antioxidant defence system, a condition called oxidative stress is created (Sies, 1991). Hence, pathophysiology of peptic ulceration has been associated with enhancement of oxidative stress in the gut by pro-ulcerative factors like *Helicobacter pylori* (Yamaguchi and Kakizoe, 2001), smoking (Ma *et al.*, 2000), psychological stress (Mawdsley and Rampton, 2006) and dietary intake of potential ulcerogens (Ibironke *et al.*, 1997) and use of non-steroidal anti-inflammatory drugs (NSAIDs) (Rostom *et al.*, 2000). In this study, indomethacin causes lipid peroxidation with depletion of endogenous antioxidant in the rat stomach, observed by the increase in malondialdehyde (MDA) concentration and decrease in superoxide dismutase (SOD) and catalase (CAT) in the homogenized gastric mucosa samples. However, pre-treatment with aqueous leaf extract of *Aspilia africana* ameliorate the increase in the lipid peroxidation induced by indomethacin, with a concomitant increase in the activity of endogenous antioxidant enzymes. This supports the earlier report of antioxidant activity of *Aspilia africana* by Faleye and Ogundaini (2012). The gastroprotective properties of the plant may be due to the enhanced antioxidant defence system which is known to be an embodiment of scavengers which mop up free radicals predisposing the stomach to inflammation. Moreover, the plant's activities have been linked with the high presence of flavonoids (Nwachukwu *et al.*, 2012), since many plants with flavonoidal activities have been shown to possess high antiulcer activity (Olaleye and Farombi, 2006).

Moreover, neutrophils play a negative role in normal tissue repair as they produce bioactive substances capable of accelerating tissue damage, including oxygen radicals (Shandall *et al.*, 1986; Dovi *et al.*, 2004), digestive enzymes and pro inflammatory cytokines (Alzoghaibi *et al.*, 2005). Previous reports have even implicated circulating activated and infiltrating leukocytes in the pathogenesis of NSAID induced damage due to reduced gastric mucosal blood flow and microvascular dysfunction (Musumba *et al.*, 2009). In this study, a substantial neutrophil infiltration was evident in the indomethacin treated group which was significantly attenuated in the extract treated groups dose-dependently. Interestingly, the effect of the extract on the neutrophil infiltration seemed to agree with what was observed in the lipid peroxidation study. This clearly supports the fact that neutrophils actually release reactive oxygen species when they infiltrate an ulcer site

as earlier established (Wallace *et al.*, 1991). Further work is on-going in our laboratory to investigate the role of inflammatory cytokines, epithelial cell proliferation and angiogenesis in the anti-ulcerogenic activity of *Aspilia africana*.

In conclusion, this study has emphasized previous scientific works, and folkloric medicinal exploration that aqueous leaves extract of *Aspilia africana* is a potent anti-ulcer agent. It reduces acid output, oxidative stress and neutrophil infiltration in ulcerated stomach.

Acknowledgement

The authors of this manuscript wish to acknowledge the support of the Senate Research Grant Committee of Igbinedion University, Okada, Nigeria for provision of funds for this study.

REFERENCES

- Adeniyi BA and Odufowora RO (2000): *In vitro* antimicrobial properties of *Aspilia africana*. *Afr J Biomed Res* 3:167-170.
- Ajeigbe KO, Olaleye SB, Oladejo EO, Olayanju AO (2011): Effect of folic acid supplementation on oxidative gastric mucosa damage and acid secretory response in the rat. *Indian J Pharmacol* 43:578-81.
- Al Mofleh I (2010): Spices, herbal xenobiotics and the stomach: Friends or foes? *World J Gastroenterol* 16 (22): 2710-2719.
- Alam S, Asad M, Asdaq SM, Prasad VS (2009): Antiulcer activity of methanolic extract of *Momordica charantia* L. in rats. *J Ethnopharmacol* 123: 464-469.
- Allen A, Garner A (1980): Progress report: Mucus and bicarbonate secretion in the stomach and their possible role in mucosal protection. *Gut* 21: 249-262.
- Alzoghaibi MA (2005): neutrophil expression and infiltration into Crohn's intestine. *Saudi J Gastroenterol* 11: 63-72.
- Cemek M, Yilmaz E, Buyukokuroglu ME (2010): Protective effect of *Matricaria chamomilla* on ethanol-induced acute gastric mucosal injury in rats. *Pharm Biol* 48: 757-63.
- Choquet A, Magous R, Bali JP (1993): Gastric mucosal endogenous prostanoids are involved in the cellular regulation of acid secretion from isolated parietal cells. *J Pharmacol. Exp. Ther.* 266: 1306-11.
- Dimaline R, Varro A (2007): Attack and defence in the gastric epithelium - A delicate balance. *Exp Physiol* 92: 591-601.
- Dovi JV, Szpadarska AM, Dipietro LA (2004): Neutrophil function in the healing wound: Adding insult to injury. *Thromb Haemost* 92: 275-280.
- Eweka AO (2007). Histological studies of the effects of oral administration of *Aspilia africana* (Asteraceae) leaf extract on the ovaries of female Wistar rats. *The Intern J Altern Med* 4:2.
- Faleye FJ, Ogundaini OA (2012): Evaluation of antioxidant and antimicrobial activities of two isolates from *Aspilia africana* (Pers) C.D Adams. *Int Res J Pharm* 3 (7): 135-138
- Gutteridge JMC, Wilkins S. (1982): Copper-dependent hydroxyl radical damage to ascorbic acid: Formation of a thiobarbituric acid reactive product. *FEBS Lett* 327-330.
- Haber MM, Lopez I (1999): Gastric histologic findings in patients with nonsteroidal anti-inflammatory drug-associated gastric ulcer. *Mod Pathol* 12: 592-8.
- Hutchinson J (1962): Flora of West Tropical Africa, Crown Agents for Overseas Government and Administration 4 Mill Bank, London, p. 119.
- Hunter GD, Millson GC, Chandler RL (1963): Observations on the comparative infectivity of cellular fractions derived from homogenates of mouse-scrapie brain. *Res Vet Sci* 4:543-9.
- Ibironke GF, Olaleye SB, Balogun O, Aremu DA. (1997). Effect of diets containing seeds of *Garcinia kola* (Heckel) on gastric acidity and experimental ulceration in rats. *Phytother Res* 1997; 11: 312-313.
- Iwu M (1993): Handbook of African Medicinal Plants. CRP Press, Boca Raton Florida.
- Kato S, Aihara E, Yoshii K, Takeuchi K (2005): Dual action of prostaglandin E2 on gastric acid secretion through different EP receptor subtypes in the rat. *Am J Physiol* 89 (1): G64-G69.
- Kuaite JR, Zollo RHA, Kammaty G, Menutand C, Bessiere JM (1999): Composition of the essential oils from the leaves of two varieties of *Aspilia Africana* (Pers.) C.D. Adams from Cameroon. *Flavour Fragr J* 14:167-169.
- Ma L, Wang WP, Chow JY, Yuen ST, Cho CH (2000): Reduction of EDF is associated with the delay of ulcer healing by cigarette smoking. *Am J Physiol Gastrointest Liver Physiol* 278: G10 – G17.
- Macfoy CA and Cline FI (1990): *In vitro* antibacterial activities of three plants used in traditional medicine in Sierra Leone. *J Ethnopharmacol* 28: 323-327.
- Magwere T, Naik YS, Hasler TA (1997): Effects of chloroquine treatment on antioxidants enzymes in rats liver and kidney. *Free Rad Biol Med* 22: 321-327.
- Malfetheriner P, Chan FK, McColl KE (2009). Peptic ulcer disease. *Lancet* 374: 1449-1461.
- Mawdsley JE and Rampton S (2006): The role of psychological stress in inflammatory bowel disease. *Neuroimmunomodulation* 13: 327 – 336.
- Misra HP and Fridovich I (1972): The role of superoxide ion in the auto-oxidation of epinephrine and a simple assay for superoxide dismutase. *J Biol Chem.* 247: 3170–3175.
- Musumba C, Pritchard DM, Pirmohamed M (2009): Cellular and molecular mechanisms of NSAIDs-induced peptic ulcers. *Aliment Pharmacol Ther* 30: 517-531
- Naito Y and Yoshikawa T (2006): Oxidative stress involvement and gene expression in indomethacin-induced gastropathy. *Redox Rep* 11: 243-53.
- Nguelefack TB, Watcho P, Wansi S, Mbonuh N, Ngamga D, Tane P Kamanyi A (2005): The antiulcer effects of the methanolic extract of the leaves of *Aspilia Africana* (Asteraceae) in rats. *Afr J Trad Comp Alt Med* 2(3):233-237.

- Nwachukwu CD and Okwousa NC (2012):** Investigation of the Anti-ulcer activity of chloroform leaf extract of *Aspilia africana* in rats. *IJNDD* 4 (1): 52-56.
- Ogihara Y and Okabe S (1993):** Effect and mechanism of sucralate on healing of acetic acid – induced gastric ulcers in rats. *J. Physiol. Pharmacol* 44: 109 – 118.
- Okoli CO, Akah PA, Okoli AS (2007):** Potential of leaves of *Aspilia Africana* (Composite) in wound care: An experimental evaluation. *BMC Comp Altern Med* 7(24):101-109.
- Olaleye SB and Farombi EO (2006):** Attenuation of Indomethacin- and HCl/Ethanol-induced oxidative gastric mucosa damage in rats by kolaviron (Garcinia biflavanones). *Phytother Res* 20: 14-20.
- Olaleye SB, Owoyele BV, Odukanmi AO (2008):** Antiulcer and Gastric Antisecretory Effects of *Landolphia owariensis* Extracts In Rats. *Niger J Physiol Sci* 23 (1-2): 23-26
- Oliver B (1960):** Medicinal Plants in Nigeria, College of Arts, Science and Technology, Lagos, p: 68.
- Omokehinde AO, Obijole OA, Oloyede HO (2014).** Ethno botanical Survey of Anti-Ulcer Plants in South-Western Nigeria. *Int J Pharm Sci* 4 (1): 431-433.
- Page JE, Balza F, Nistida T, Towere GHN (1992):** Biologically active diterpenes from *Aspilia mossambicensis*, a chimpanzee medicinal plant. *Phytochem* 31: 3437-3439.
- Rainsford KD (1987):** The effects of 5-lipoxygenase inhibitors and leukotriene antagonists on the development of gastric lesions induced by nonsteroidal anti-inflammatory drugs in mice. *Agents and Action* 21: 316 – 319.
- Rostom A, Wells G, Tugwell P, Welch V, Dube C and McGowon J (2000):** Prevention of chronic NSAID-induced upper gastrointestinal toxicity. *Cochrane Database Syst. Rev.* Samuel OI, Thomas N, Ernest OU, Imelda NN, Elvis NS,
- Ifeyinwa E (2010):** Comparison of haematological parameters determined by the sysmex KX-21N automated haematology analyzer and the manual counts. *BMC Clin Pathol* 10: 3.
- Schmassmann A (1998):** Mechanisms of ulcer healing and effects of Nonsteroidal anti-inflammatory drugs. *Am J Med* 104(3A): 43S-51S.
- Shandall AA, Williams GT, Hallett MB, Young HL (1986):** Colonic healing: A role for polymorphonuclear leucocytes and oxygen radical production. *Br J Surg* 73: 225-228.
- Sies H (1991):** Oxidative Stress: From Basic Research to Clinical Application. *Am J Med* 91: 31-38.
- Sinha KA (1972):** Colorimetric assay of catalase. *Anal Biochem* 47: 389-394.
- Trevethick MA, Clayton NM, Strong P, Harman IW (1993):** Do infiltrating neutrophils contribute to the pathogenesis of indomethacin induced ulceration of the rat gastric antrum? *Gut* 34:156–160.
- Tulassay Z and Herszényi L (2010).** Gastric mucosal defense and cytoprotection. *Best Pract & Res Clin Gastroenterol* 24 (2): 99-108.
- Uyanıkoğlu A, Danalıoğlu A, Akyüz F, Pınarbaşı B, Güllüoğlu M, Kapran Y, Demir K, Özdiş S, Beşışık F, Boztaş G, Mungan Z and Kaymakoglu S (2011):** The Etiological Factors of Duodenal and Gastric Ulcers, Peptic Ulcer Disease, Dr. Jianyuan Chai (Ed.), <http://www.intechopen.com/books/peptic-ulcer-disease/the-etiological-factors-of-duodenal-and-gastric-ulcers>
- Wallace JL (2001):** Pathogenesis of NSAID-induced gastroduodenal mucosal injury. *Best Pract Res Clin Gastroenterol* 15: 691-703.
- Wallace JL, Arfors KE, McKnight GW (1991):** A monoclonal antibody against the CD18 leukocyte adhesion molecule prevents indomethacin-induced gastric damage in the rabbit. *Gastroenterology*, 100: 878-883.
- Yamaguchi N and Kakizoe T (2001):** Synergistic interaction between *Helicobacter pylori* and gastric cancer. *Lancet Oncol* 2: 88-94.
- Yao X and Forte JG (2003):** Cell biology of acid secretion by the parietal cell. *Annu Rev Physiol* 65: 103 – 131.
- Zelickson MS, Bronder CM, Johnson BL, Camunas JA, Smith DE, Rawlinson D, Von S, Stone HH, Taylor SM (2011):** *Helicobacter pylori* is not the predominant etiology for peptic ulcers requiring operation. *Am Surg* 11 (77):1054–1060.