

www.ajbrui.net

Afr. J. Biomed. Res. Vol.18 (January, 2015); 55- 60

Full Length Research Paper

Beneficial Effects of Leaf Extracts of *Lycoperscon esculentum* on Wound Healing in Rats

Zamide E.I.¹, Ajani R.S.² and Oladapo O.O.²

¹*Department of Anatomy, College of Health Sciences, University of Port Harcourt, Nigeria*

²*Department of Anatomy, College of Medicine, University of Ibadan, Nigeria*

ABSTRACT

The study was aimed at determining the effects of the methanol extracts of the leaves of *Lycoperscon esculentum* on the wound healing in Wistar rats. Excisional wounds were inflicted on the upper dorsolateral trunk of normal saline (control) and tomato (*Lycoperscon esculentum*) leaf treated (TLT) adult rats and thereafter dressed four times daily for three days. Wound dimensions along two perpendicular axes were taken prior to dressings for the purpose of estimation of wound contraction rates. Granulation tissues were excised from five animals in each group and scar tissues obtained from the remaining animals. Fibroplasia and angiogenesis were evaluated histologically. Matched wound contraction rates were higher in the TLT group. Duration of healing was shorter in the TLT (19.80 ± 1.64 days) when compared with control (28.80 ± 4.55 days). Fibroblast counts of granulation tissue were 35.20 ± 17.53 (for TLT) and 24.00 ± 8.00 (for control), with respective angiogenesis counts of 12.60 ± 8.32 and 15.60 ± 5.77 . Respective values for fibroblast and angiogenesis of the scar tissues in experimental and control groups were 18.40 ± 3.7 vs 20.80 ± 5.21 ; and 14.20 ± 1.92 vs 13.20 ± 1.64 . Histological sections of the granulation and scar tissues revealed abundance of collagen and paucity of macrophages in the experimental group. Leaf extract of *Lycoperscon esculentum* promotes wound healing via bactericidal activity, rapid initiation and acceleration of wound contraction, increased fibroblast production and collagen synthesis

Key words: skin wound healing, *Lycoperscon esculentum*, tomato leaves, fibroplasia, angiogenesis.

INTRODUCTION

Wound is a full or partial interruption in the integrity of the skin. It may be self-inflicted or the result of an accident or violent attack. For the purpose of gaining

access to internal or deeper structures it is necessary to create a wound. Irrespective of the aetiology of the wound, what is desirable and should follow is healing. Wound healing in humans is largely by repair; involving some physiological, biochemical and histologic processes that occur in known and orderly sequence. In normal wound healing, these sequential processes are hemostasis, inflammation, proliferation and tissue remodeling (Mendel, 2002). The ultimate result of these sequential processes is the re-establishment of the integrity of the skin. The duration, extent and severity of each of these processes are predicated on the location and clinical classification of the wound; comorbid systemic diseases and nutritional status of the person or patient. When these factors are favourable to the patient, wound heals in days with production of fine scar.

There are several factors and or agents that are capable of promoting or retarding these processes. Various interventional or therapeutic modalities such as topical dressings and systemic drugs are targeted towards acceleration of the healing process. Thus any

*Corresponding author:

E-mail: rsaajani@yahoo.co.uk

Tel: +2348023007362

Date Received: February, 2014

Date Accepted: September, 2014

Abstracted by:

Bioline International, African Journals online (AJOL), Index Copernicus, African Index Medicus (WHO), Excerpta medica (EMBASE), CAB Abstracts, SCOPUS, Global Health Abstracts, Asian Science Index, Index Veterinarius

of such modalities that is readily available, affordable and that cannot be readily adulterated will not only accelerate the healing process but also reduce the morbidity associated with wounding and healing.

A number of medicinal plants have been reported to be useful in the management of skin ulcers. These include butanol extract of *Argyrea speciosa* (Jaiswal *et al.*, 2011), leaf extract of *Hippophae rhamnoides* (Upadhyay *et al.*, 2011) and snakehead fish extract (Khan *et al.*, 2014), had been used experimentally to manage ulcer (this is a form of wound). Also the ability of biologic agents such as combined alginate and recombinant human granulocyte-macrophage colony stimulating factor (rhGM-CSF) to promote healing in refractory chronic skin ulcers has been documented in literature. (Huang *et al.*, 2014). Another example of biologic agents used in wound dressing is mixture of fibrin glue with rat bone marrow stem cells. (Yang *et al.*, 2014). Novel as these approaches are, they may not be affordable by and accessible to majority of Nigerians. A significant percentage of Nigerian population (60.9-69 %) is at or below the poverty line (National Bureau of Statistics, 2012). Thus it becomes pertinent to find alternatives which are not only affordable and accessible but also efficacious, hence the need to investigate the efficacy of more agents in the management of wound.

Tomato (*Lycoperscon esculentum*) is universally available, easy to cultivate and can be grown at any period of the year. It has a short cultivation period. Be it raw, or in processed form, it is safe and edible. It has diverse health and medicinal applications. Useful secondary metabolites of tomato include phenolic compounds, phytoalexins, lycopenes, protease inhibitors, carotinoids and glycoalkaloids (Taveirat *et al.*, 2010). These compounds exhibit antibacterial (Mendel, 2004), antifungal and antiviral properties amongst others (www.holisticon-line.com). *Lycoperscon esculentum* is not only readily available, but also affordable and adulteration-proof. Hence the need to investigate its role in the histological and biochemical processes of wound healing. In this study, the extract obtained from the tomato leaves was used as topical dressing material and aimed at determining its effects on wound contraction, fibroplasia and angiogenesis.

MATERIALS AND METHOS

Experimental animals

Twenty adult male Wistar rats, (weight range: 150 to 220g) were utilized for the study. They were procured from the Animal House of the College of Medicine, University of Ibadan. The animals were fed with

standard rat pellets and water. They were housed in well ventilated cages placed in well-lit room with good air flow. This period of acclimatization lasted two weeks. The animals were handled in accordance with guidelines of the University of Ibadan Ethical Committee on Experimental Animals. Thereafter, they were randomly allotted into two equal groups of ten namely, control and Tomato leaf-treated (TLT).

Collection and Extraction of Plant material

The leaves of *Lycoperscon esculentum* (Tomato) were collected from a farm in Ibadan, Nigeria. The plant was Identified and authenticated as *Lycoperscon esculentum* of the Solanaceae family at the Herbarium of the Forestry Research Institute of Nigeria (FRIN), Ibadan. The leaves were subsequently dried and used to prepare the methanolic extract.

Fresh tomato leaves were cleaned and washed carefully in water and thereafter with distilled water. The washed leaves were then dried at room temperature for 3 weeks and then grounded to powder using a dry electric mill (Moulineux, UK). 750 g of the powdered plant material was extracted in cold methanol. Solvent from each sample was filtered, squeezed off and evaporated off under reduced pressure in a rotary evaporator to obtain crude methanol extract.

Excisional wound model

A 2cm by 2cm wound was created on the dorsolateral aspect of the thoracic wall under aseptic condition; achieving prior sedation with parenteral diazepam (2mg/kg) and ketamine hydrochloride at a dose of 120mg/Kg body weight. The hair over the wound site was initially removed with an electric shaver. The animals in the control group had their wounds dressed with saline soaked gauze while those of the TLT were dressed with gauze impregnated with the methanolic extract of *L. esculentum*. Both groups had four cycles of wound dressing at an interval of three days. Prior to change of dressing in each group, the dimensions of the wounds were measured along two perpendicular plane for the purpose of calculating the degrees of wound contraction in percentages. At the last wound dressing, granulation tissues from five randomly selected rats of each group were excised.

Light microscopy slides using Hematoxyline and Eosin dye were prepared from the harvested granulation tissues for the purpose of fibroplasia and angiogenesis estimation. Fibroplasia was estimated by fibroblast count and the number of blood vessels was used to determine the degree of angiogenesis. The wounds of the remaining ten rats were allowed to heal. Thereafter, the scars were excised for histological examinations (fibroplasia and angiogenesis). The last scar was excised on Day 37.

The results were analysed using the Student t- test was used for inter group comparison and level of significance was set at $p < 0.05$.

RESULTS

Although square shaped wounds were inflicted in all the animals, subsequently observed wound shapes varied from oval to round. The gradual reduction in wound size in both groups did not follow any specific order. The wounds of the experimental group were dark brown while those of the control were varied degree of redness. The resultant scars in both groups

were observed to be fine and linear. At each change of wound dressings, the animals in the TLT group exhibited greater wound contraction rates than the control animals. A plot of the degree of wound contraction against duration of healing revealed a more linear with higher gradient graph in the experimental group than that of the control group (Figure 1).

Eighty percent wound contraction rate was achieved on Day 9 in the experimental group as opposed to its being achieved on Day 12 in the control group. The wound contraction rate peaked 3 days earlier in the TLT group (Day 15) as compared with the control (Day 24).

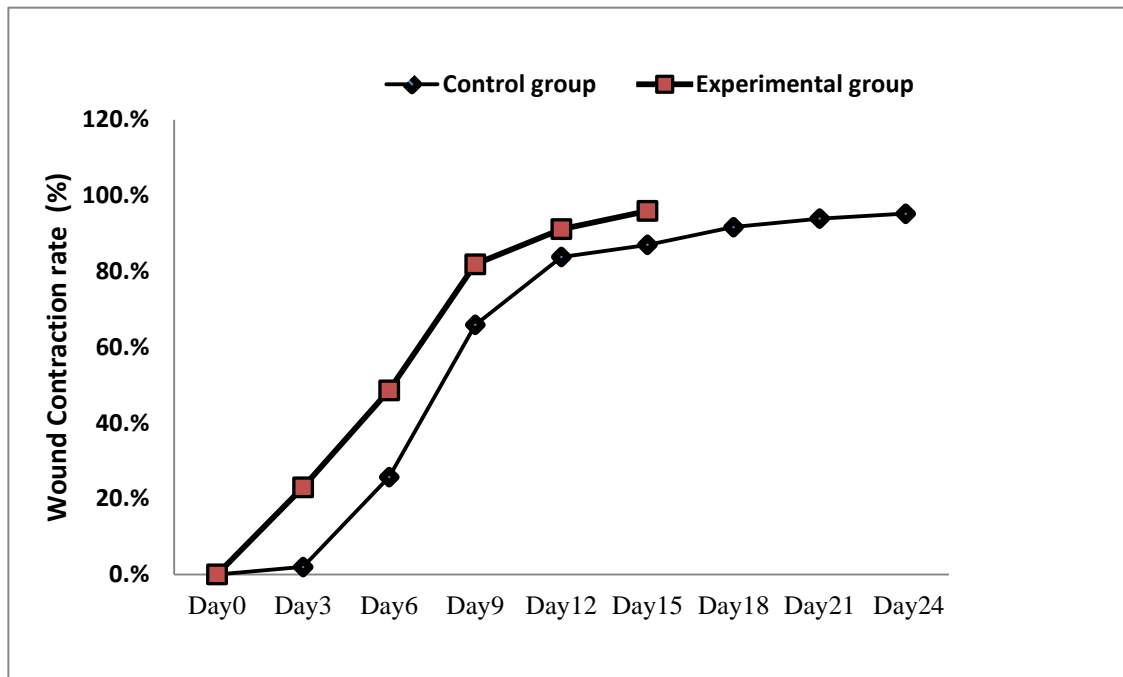


Figure 1:

Wound contraction rates in control rats and those given the leaf extract of *L. esculentum*. There was a lag period of about three days in the contraction rate of the control group, while the experimental group exhibited a linear take off. The percentages on the graphs indicate the contraction rates at specific comparable period.

Table 3:

Effect of *L. esculentum* on some indices of cutaneous wound healing in rats

Parameter	Control (N=5)	Experimental (N=5)	p-value (0.05)
Duration of Healing (days)	28.80 ± 4.55	19.80 ± 1.64	0.003
Granulation tissue for:			
(a) Fibroblast count	24.00 ± 8.00	35.20 ± 17.53	0.23
(b) Angiogenesis	15.60 ± 5.77	12.60 ± 8.32	0.52
Healed scar for:			
(a) Fibroblast	20.80 ± 5.21	18.40 ± 3.57	0.42
(b) Angiogenesis	13.20 ± 1.64	14.20 ± 1.92	0.40

Values are mean ± SEM of n animals

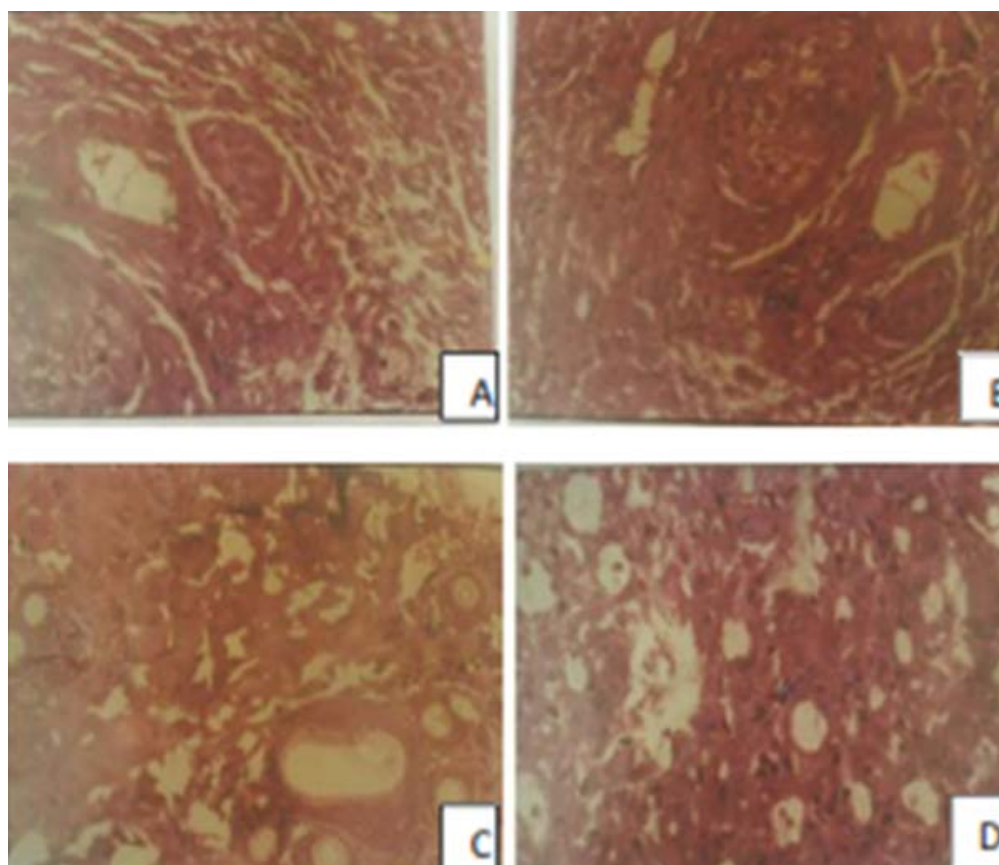


Plate 1: (**A**). Granulation tissue obtained from the control group on day 9(H &E) x 400. Fibroblast(F). Blood vessel (BV). (**B**): Granulation tissue obtained from the experimental control group on day 9(H &E) x 400. Fibroblast (F).Blood vessel (BV). Note more collagen fibres and less macrophages when compared with that of control group (A). (**C**): Scar tissue obtained from the control group.(H&E) x 400. Fibroblast (F),Blood vessel (BV). Collagen bundle (C). The macrophages are more abundant than those of the experimental group. Although collagen fibres are abundant but not as much as in the experimental group (D). (**D**):Scar tissue obtained from the experimental group (H&E) x 400. Fibroblast (F),Blood vessel (BV). Collagen bundle (C). Note the paucity of macrophages and abundance of collagen

The parameters that were used to assess healing include the degrees of fibroplasia and angiogenesis and durations of healing as shown in table 1. The mean duration of healing was significantly lower in the experimental group (19.80 ± 1.64 days) when compared with the control (28.80 ± 4.55 days; $p= 0.003$) The levels of abundance of fibroblasts, collagen bundles and macrophages are depicted in the histological sections of granulation and scar tissues of both groups (Plate 1)

DISCUSSION

Wound healing is a multiphase, sequential, physiological process that attempts to restore the integrity of the disrupted tissue with ultimate production of varying degree of scar. Consequent on the above, any intervention, in form of topical dressing with or without adjunct therapy is targeted towards achieving this natural physiologic process. Such

interventions in concert with other comorbid factors that may be present in the person or patient may accelerate or retard the healing process.

Wound contraction is one of the early processes in healing; it attempts to reduce the wound size. Thus any interventional agent that is able to produce greater wound contraction rate has a positive impact on wound healing. Results of this study clearly demonstrated greater wound contraction rates in the tomato leaf-treated group over the control. Some negative values were recorded in some of the control animals in this study, indicating expansion rather than reduction in wound size. These values were recorded at the first change of wound dressing. This expansion in wound size could be indicative of sepsis (infection). Since this was observed more in the control group, it may be reasonably concluded that *L. esculentum* possesses bactericidal property. Further work is however needed to clarify this assumption.

The interval differences in the mean percentage wound contraction were more pronounced between Day 3 and Day 9. Although wound contraction has been demonstrated to reach its peak by Day 9, these wide margin differences within the stated period imply the ability of *L. esculentum* to accelerate wound healing. This assertion was also reinforced by the shorter mean healing period observed in the experimental group. Observations made from the graphic representations of wound contraction rates could be suggestive of the ability of *L. esculentum* to rapidly initiate and accelerate fibroblast synthesis.

It is the activity of myofibroblasts that is responsible for wound contraction (i.e. post injury wound closure) (Junqueira *et al.*, 2005). These myofibroblasts, though predominantly fibroblastic in nature, also have smooth muscle features. The higher mean percentage wound closure observed in the experimental group implies greater content of myofibroblasts. Consequently, it is safe and reasonable to conclude that *L. esculentum* has the propensity to increase myofibroblast synthesis and by extension promote wound healing. This assertion is further strengthened by the higher fibroblast count observed in the granulation tissue of the experimental group.

In wound healing, as maturity advances, the granulation tissue becomes progressively pale due to reduction in neovascularization and formation of immature vessels that characterize the healed scar. In this study, the granulation tissue of the control animals exhibited greater angiogenesis than those of the experimental group. However, angiogenesis in the healed scars of the experimental group was slightly higher than that of the control group. When these observations are considered in the context of healing rate a reasonable deduction that could be made is that the wounds of the experimental group healed faster than those of the control group. Thus this study has been able to demonstrate the ability of *L. esculentum* to promote the changes in angiogenesis that occur during wound healing.

This study also demonstrated significant difference in the mean duration of healing, with the experimental group having shorter duration. The importance of this observation is the wound healing enhancing ability of *L. esculentum*. Lycopene, an important, abundant and active ingredient of *L. esculentum* is a more effective low density lipoprotein antioxidant (Tsuchiya *et al.* 1996) than β -carotene. It has been demonstrated that any agent or compound that is capable of reducing lipid peroxidation will increase the strength of collagen fibres and improve blood circulation (Manjunatha *et al.*, 2005). These two physiological phenomena will enhance wound healing. This explains the ability of *L. esculentum* as a potent wound healing agent.

Bioflavonoids are present in *L. esculentum*. Flavonoids, via their antimicrobial and astringent properties (Douglas *et al.*, 2003) enhance wound healing (S'untar *et al.*, 2011)

The literature is awash with wound healing potentials of various extracts of diverse plants. Such plant diversity include *Vernonia arborea* Hk. (Manjunatha *et al.*, 2005), *Rubus sanctus* (Rosaceae) (S'untar *et al.*, 2011), *Allamanda cathartica*. L. and *Laurus nobilis*. L (Nayak *et al.*, 2006), *Hyptis suaveolens* (L.) Poit (Lamiaceae) (Shenoy *et al.*, 2009), *Adhatoda vasica* (Subhashshini *et al.*, 2010), *Myristica andamanica* (Arunachalam *et al.*, 2011), *Ficus racemosa* L (Murti *et al.*, 2012), *Eucheuma cottonii* (Fard *et al.*, 2011), *Carapa guianensis* L. (Meliaceae) (Nayak *et al.*, 2010), *Indigofera aspalathoides* (Subhashshini *et al.*, 2011), *Boesenbergia rotunda* (L.) (Mahmood *et al.*, 2010), *Lawsonia ulba* Linn (Nitthya *et al.*, 2011), *Pentas lanceolata* (Nayak *et al.*, 2005), *Catharanthus roseus* (Nayak *et al.*, 2006), *Alternanthera sessilis* Linn (Jalalpure *et al.*, 2008). The extracts (aqueous, methanol, ethyl acetate, hexane and chloroform) of these plants, have all been demonstrated to have positive impact on wound healing, thus the impact of plants be it the seed, fruit, leaves or stem or root on wound healing has been strongly demonstrated and well documented. It is pertinent to note that this study did not set out to compare the efficacy of *L. esculentum* against the extracts of other plants in wound healing; the mentioning of these plants is to highlight the prominent role of some natural plants in wound healing.

This study has been able to demonstrate that the methanol extract of *L. esculentum* promotes wound healing. Mechanisms through which this is achieved include more rapid initiation and faster wound contraction. Increased fibroblasts production and collagen synthesis as evidenced by the histological sections produced from the granulation tissues and wound scars respectively.

Since *L. esculentum* is widely and easily cultivated, readily available and relatively cheap, its use as dressing agent for uncomplicated wounds is advocated. This will contribute in no small at reducing complications of wound such as chronicity, tetanus infection, pyomyositis and septicemia

REFERENCES

- Chitra Shenoy, M B Patil and Ravi Kumar (2009):** Wound Healing Activity of *Hyptis suaveolens* (L.) Poit (Lamiaceae). *Int. J. Pharm Tech Res.* 2009; 1(3): 737-744
- Douglas, M. and L. Miller Alan (2003):** Nutritional support for wound healing. *Alternative Med. Rev.* 2003; 8: 359-377

- Friedman Mendel (2002):** Tomato glycoalkaloids: Role in the plant and diet. *J. Agric and Food Chemistry* 2002; 50, (21): 5751-5780
- Friedman Mendel (2004):** Analysis of biologically active compounds in potatoes (*Solanum tuberosum*), tomatoes (*Lycopersicon esculentum*) and jimson weed (*Datura stramonium*) seeds. *Journal of Chromatography A* 2004; 1054: 143-155.
- Guobao Huang, Tangqing Sun, Lei Zhang and Qiuhe Wu (2014):** Combined application of alginate dressing and human granulocyte –macrophage colony stimulating factor promotes healing in refractory chronic skin ulcers. *Experimental and Therapeutic Medicine* 2014;7:1772-1776.
- Herb data, Tomato, healing benefits of tomato, medicinal properties of tomato.....http://www.holistic-online.com/Herbal-med/_Herbs/h_tomato-heal.....
- Ipek S'untar, Ufuk Koca, Hikmet Keles and Esra K'upeli Akkol (2011):** Wound healing activity of *Rubus sanctus* Schreber (Rosaceae): Preclinical Study in Animal Models. Evidence-Based Complementary and Alternative Medicine 2011;doi:10.1093/ecam/nep137.
- Jalalpure SS, Agrawal N, Patil MB, Chimkode R, Tripathi A (2008):** Antimicrobial and wound healing activities of leaves of *Alternanthera sessilis* Linn. *Int J Green Pharm* 2008;2:141-4
- Junqueira Luiz Carlos and Carneiro Jose (2005):** Basic Histology. New York: McGraw-Hill,2005; 93.
- Kantha D. Arunachalam and Subhashini S (2011):** Preliminary phytochemical investigation and wound healing activity of *Myristica andamanica* leaves in Swiss albino mice. *Journal of Medicinal Plants Research* 2011; 5(7):1095-1106.
- Krishna Murti and Upendra Kumar (2011).** Enhancement of wound healing with roots of *Ficus racemosa* L. in albino rats. *Asian Pacific Journal of Tropical Biomedicine* 2012:276-280.
- Mohammed Safwan Ali Khan, Abdul Manan Mat Jais, Javeed Husain, Faiza Siddiqua, A. Gopala Reddy, P. Shivakumar and D. Madhuri (2014):** Gastroprotective Effect of Freeze Dried Stripped Snakehead Fish (*Channa striata* Bloch.) Aqueous Extract against Aspirin induced Ulcerogenesis in Pylorus ligated rats. *ISRN Pharmacology* 2014; Article ID 327606, 8 pages, doi:10.1155/2014/327606.
- Mahmood. A.A, Abdalbasit A. Mariod, Siddig Ibrahim Abdelwahab, Salmah Ismail and Fouad Al-Bayat (2010):** Potential activity of ethanolic extract of *Boesenbergia rotunda* (L.) rhizomes extract in accelerating wound healing in rats. *Journal of Medicinal Plants Research* 2010; 4(15): 1570-1576.
- Manjunatha BK, Vidya SM, Rashmi KV, Mankani KL, Shilpa HJ, Singh SJ (2005):** Evaluation of wound-healing potency of *Vernonia aborea* Hk. *Indian J. Pharmacol* 2005;37:223-226
- Marcos Taveirat, Luis R. Silvat, Luis A Vale-Silvat (2010):** *Lycopersicon esculentum* seeds: An industrial byproduct as an antimicrobial agent. *J. Agric and Food Chemistry* 2010; 58, (17): 9529-9536.
- National Bureau of Statistics (2010):** Harmonised Nigeria Living Standard Survey. Nigeria Poverty Profile Report 2010. www.nigerianstat.gov.ng.
- Nayak. B.S and Lexley M Pinto Pereira (2006):** *Catharanthus roseus* flower extract has wound-healing activity in Sprague Dawley rats. *BMC Complementary and Alternative Medicine* 2006, 6:41
- Nayaka. B.S, Vinuthaa. B, Geethaa. B, Sudhac. B (2005):** Experimental evaluation of *Pentas lanceolata* flowers for wound healing activity in rats *Fitoterapia* 2005;76(7-8):671-675
- Nithya. V and Anusha Baskar (2011):** A Preclinical Study on Wound Healing Activity of *Lawsonia ulba* Linn. *Research Journal of Phytochemistry* 2011; 5: 123-129.
- Samaneh Ghasemi Fard, Rosalina Tan Roslan Tan, Ajwad Awad Mohammed, Goh Yong Meng, Sharifah Kharidah, Syed Muhamad, Karim Alwan AL-Jashamy and Suhaila Mohamed (2011):** Wound healing properties of *Eucheuma cottonii* extracts in Sprague-Dawley rats. *Journal of Medicinal Plants Research* 2011; 5(27) : 6373-6380.
- Shivananda Nayak. B, Joel Kanhai, David M. Milne, William H. Swanston, Shabana Mayers, Mathew Eversley, and A.V. Chalapathi Rao (2010): Investigation of the Wound Healing Activity of *Carapa guianensis* L. (Meliaceae) Bark Extract in Rats Using Excision, Incision, and Dead Space Wound Models. *Journal of Medicinal Food*. October 2010, 13(5): 1141-1146.
- Shivananda Nayak, Poorna Nalabothu, Steve Sandiford Vidyasagar Bhogadi and Andrew Adogwa (2006):** Evaluation of wound healing activity of *Allamanda cathartica*. L. and *Laurus nobilis*. L. extracts on rats. *BMC Complementary and Alternative Medicine* 2006. 6:12. doi:10.1186/1472-6882-6-12
- Subhashini S. and Kantha D. Arunachalam (2010):** Investigations on the phytochemical activities and wound healing properties of *Adhatoda vasica* leave in Swiss albino mice. *African Journal of Plant Science*; 4 (12): 467-479.
- Subhashini. S , Kantha D. Arunachalam and Sathesh Kumar A (2011):** Preclinical studies on the Phytochemical, Antimicrobial, and Wound healing properties of *Indigofera aspalathoides* leaves. *Journal of Pharmacy Research* 2011; 4(9):3206-3211.
- Sunil K. Jaiswal, Chandana V. Rao, Brijesh Sharma, Pritee Mishra, Sanjib Das and Mukesh K Dubey (2011):** Gastroprotective effect of standardized leaf extract from *Argyrea speciosa* on experimental gastric ulcers in rats. *Journal of Ethnopharmacology* 2011; 137(1):341-344.
- Tsuchiya. H, Sato.M, Miyazaki. T (1996):** Comparative study on the antibacterial activity of phytochemical flavanones against methicillin- resistant *Staphylococcus aureus*. *Journal of Ethnopharmacology* 1996; 50 (1): 27-34.
- Yadong Yang, Wenyan Zhang, Ying Li, Guojian Fang, Keji Zhang (2014):** Scalded skin of Rat treated by using fibrin glue combined with Allogeneic Bone Marrow mesenchymal stem cells. *Ann Dermatol*. 2014; 26(3): 289-295.