

Case Report

Isolated Blunt Lingual Artery Injury Secondary to a Road Traffic Accident: Diagnostic and Therapeutic Approach

Azman MAWADDAH¹, Bee See GOH¹, Thean Yean KEW², Zakaria ROZMAN²

Submitted: 22 Jun 2011

Accepted: 21 Aug 2011

¹ Department of Otorhinolaryngology–Head and Neck Surgery, Faculty of Medicine, Universiti Kebangsaan Malaysia, Jalan Yaacob Latiff, Bandar Tun Razak, 56000 Cheras, Kuala Lumpur

² Department of Radiology, Faculty of Medicine, Universiti Kebangsaan Malaysia, Jalan Yaacob Latiff, Bandar Tun Razak, 56000 Cheras, Kuala Lumpur

Abstract

Neurologic and airway compromise as a result of traumatic vascular injuries to the neck region often lead to more severe complications and thus require special consideration. Furthermore, these cases pose diagnostic and therapeutic challenges to healthcare providers. Here, we report a case of a 28-year-old motorcyclist presenting with progressively enlarged Zone 2 neck swelling on the left side following a high impact collision. There were no symptoms or signs suggesting neurologic or laryngeal injury. Computed tomography angiogram of the neck revealed signs of an active arterial bleed. The apparent vascular injury was managed by close observation for signs of airway compromise, urgent angiogram, and selective catheter embolisation of the left lingual artery. The patient subsequently recovered without further operative exploration of the neck. At 6 months post-trauma, the neck swelling fully subsided with no complications from angioembolisation. This case illustrates the individualised treatment and multidisciplinary approach in managing such cases. We review our rationale for this diagnostic and therapeutic approach.

Keywords: diagnostic imaging, embolisation, neck, trauma, vascular system injury

Introduction

Traffic accidents are the leading cause of mortality among Malaysians aged 20–30 years. Neck injuries account for 5%–10% of all serious traumatic injuries. Even in this era of modern medicine, management of a patient with a neck injury still poses significant challenges. The neck is a compact conduit of various organ systems (airway, vascular, neurological, and gastrointestinal) anteriorly protected by skin and subcutaneous tissue only. Therefore, a single insult is capable of considerable harm. Life-threatening complications include airway occlusion and exsanguinating haemorrhage. A concerted multidisciplinary approach to the management of potential complications remains the cornerstone of diagnosis and treatment. Lingual artery avulsion rarely occurs in isolation without any associated cervical spine or facial trauma. The latter can be attributed to the beneficial effects of protective helmets. New advances in selective arterial embolisation allow

better treatment outcomes in vascular injuries, preventing the need for exploratory neck surgery.

Case Report

A 28-year-old male was referred to the otolaryngology team 2 hours following a hit-and-run traffic accident with a rapidly expanding neck swelling on the left side. The patient had been involved in a high impact front collision with a car while wearing a protective strapped helmet, causing him to be thrown from his motorcycle. Primary and secondary examinations revealed no evidence of injury or haemorrhage to the head, neck, or face. He later underwent observation in the emergency department due to a history of post-traumatic amnesia in anticipation of other potential injuries. He developed a rapidly expanding swelling on the left side of his neck that started at Zone 2 but later expanded to Zone 1 of the neck over a period of 2 hours. It

was associated with pain and reduced the range of movement in the neck area. There was no hoarseness, difficulty in breathing, swallowing problems, numbness, or weakness of the upper limbs. Local examination revealed a diffuse anterior mass on the left side of the neck, extending from the lower border of the mandible to the supraclavicular region and measuring 14×10 cm. The mass was neither expansile nor pulsatile, and there was no loss of carotid pulsation distal to the swelling. No palpable thrill or audible bruit was present. He had no signs of airway compromise nor did he show any cranial nerve deficit or peripheral nerve damage.

Contrasted computed tomography of the neck (Somatom Sensation 64; Siemens AG, Berlin, Germany) showed an intramuscular haematoma with its epicentre within the left sternocleidomastoid muscle. A mild tracheal shift to the right was noted, with no luminal narrowing. The haematoma presented with a thick, irregular, enhancing capsular wall with a hypodense centre. Within the hypodense centre, a focal hyperdense region of active contrast extravasation (indicating active haemorrhage) was noted during the arterial phase scanning, arising from a branch of the left external carotid artery (Figure 1). Due to the hairpin turn of this artery, the injured artery was initially thought to be the left lingual artery. The region of active haemorrhage was enlarged in the venous phase. Catheter angiography of the left external carotid artery revealed the injured artery to be a proximal branch of the left lingual artery (Figure 2). Gelfoam (Lyostypt, B Braun, Aesculap AG & Co, Tuttlingen, Germany) embolisation of the injured artery under selective cannulation of the lingual artery was performed. Reflux of embolic material into the lingual artery could not be avoided, as the calibre of the injured artery was not compatible with microcatheter superselective embolisation. Post-embolisation angiography showed successful embolisation of the transected artery (Figure 3).

The patient underwent the procedures 5 hours post-trauma without any deterioration of the airway. Post-embolisation, he was observed for 2 days, during which the neck swelling decreased in size by more than 50%. He did not experience ipsilateral tongue numbness or sustain any neurological deficits as a complication of the procedure. At 6 months post-trauma, his neck was healed with total resolution of swelling and normal mobility.

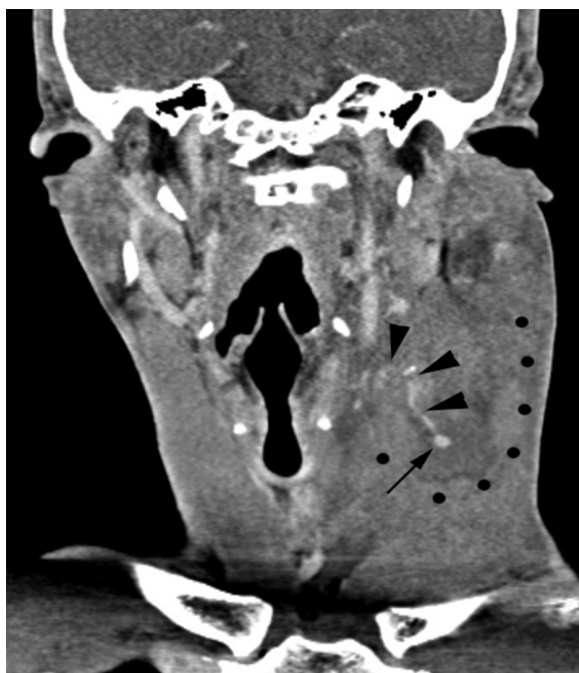

Figure 1: Coronal reformatted contrasted computed tomography of the neck showing an opacified artery (arrowheads) demonstrating a hairpin turn that leads to a focal ovoid region of active contrast extravasation (arrow) within the neck haematoma (its inferolateral margin is marked by dotted lines).

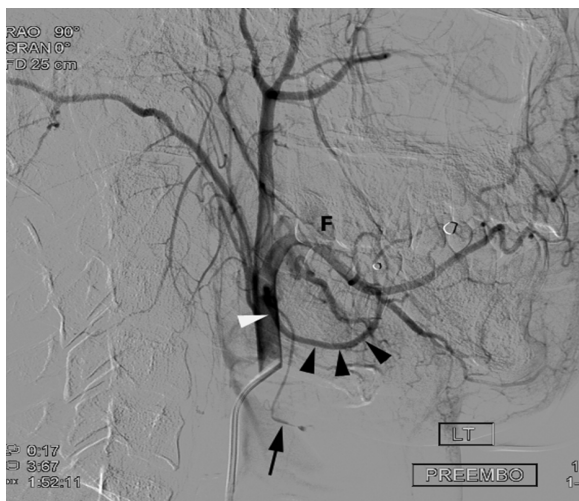


Figure 2: Digitally subtracted arteriogram of the pre-embolisation, left, external carotid artery. The artery showing contrast extravasation (arrow) is a proximal branch of the left lingual artery (arrowheads). F = left facial artery.

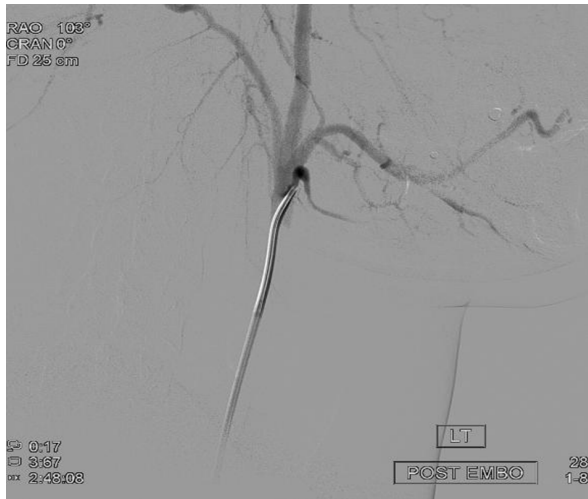

Figure 3: Post-embolisation, digitally subtracted, selective angiography of the lingual artery shows non-opacification of the embolised artery.

Discussion

Ambroise Pare described the first case of successful management of a patient with a neck injury in 1552 (8). Over 400 years later, there is still continuing debate about the best approach to managing neck trauma. The role of a well-conceived multidisciplinary plan cannot be underestimated and is critical for improved patient outcome.

For clinical and uniformity purposes, in a trauma setting, the neck is divided into 3 zones. This anatomical division provides the means for a systematic approach to evaluating potential injuries (1). Clinical criteria used to diagnose vascular injury are divided into hard and soft signs. Hard signs include massive bleeding, pulsating haematoma, severe ischaemia, shock, and thrill or bruit. Soft signs include moderate haematoma, a reduced ankle-brachial index in a vessel close to the injury and nerve damage (1). However, these signs can be deceptive with low sensitivity, at 61% (2). Carotid pulsation distal to the haematoma is present in 36% of carotid injury cases, and bruits are detected in only 2% of the cases (2). In contrast, several articles have demonstrated the safety and reliability of physical examination alone in detecting Zone 2 vascular injuries that require treatment (3). A retrospective study of 2674 patients showed that physical examination yielding hard signs of vascular injury had a positive predictive value of nearly 100% in vascular trauma requiring surgery. In this

series, only 2 vascular injuries were missed using physical examination alone (4).

The sensitivity of helical computed tomography angiography (CTA) in the detection of vascular neck injuries ranges from 80% to 100% (5). The morphology of an injured artery can be readily detected and serves as a triaging tool for further management strategies. Traumatic stenosis or occlusion can be managed conservatively; in contrast, pseudoaneurysm, active extravasation, and arteriovenous fistula require active management by either endovascular or open surgery (9).

Conventional or digital subtracted angiography (DSA) has traditionally been regarded as the standard of reference imaging modality for traumatic vascular lesions of the head and neck (6). In addition, haemorrhage control can be achieved through embolisation, stent placement, or temporary balloon occlusion (6). In some instances, CTA may be superior to DSA in regards to the relative speed of lesion detection. Cox et al. (7) noted that certain lesions readily detected on CTA were not detected by DSA until selection of the injured artery was performed. CTA, especially on multislice scanners with their multiplanar capabilities, also provides a useful “angiographic roadmap” to the interventional radiologist, enabling specific targeting of a vessel during DSA (7). By reviewing the available evidence and diagnostic options, the challenge in the current medical environment is to choose the imaging examination that is the least time consuming, least invasive, most readily available, and most cost effective.

In this particular case, the ideal embolisation procedure would have been the advancement of a suitable microcatheter into the distal active bleeding site using microcoils or permanent embolic material such as Histoacryl glue (10). However, the acute angle and the calibre of the arterial branch precluded the use of a microcatheter. Thus, Gelfoam was used as a temporary embolic agent, with the expectation of embolic reflux into the lingual artery. In our experience, inadvertent embolisation of arteries within richly vascularised anatomic regions (such as the head and the neck) very rarely leads to permanent vascular deficit of the affected end organs.

Existing reports of traumatic lingual artery injury are mainly of patients with trauma involving multiple organs, multiple fractures, and iatrogenic injury secondary to tonsillectomy. The incidence of blunt craniocervical arterial injury in a trauma setting is as low as 0.4% (11).

The lingual artery is the most vulnerable at its oblique, superficial portion as it branches from the external carotid artery and as it loops forward to its horizontal portion. These segments of the lingual artery can be injured by shear forces due to deceleration from high impact collision or helmet-strap-related injury, precluding other organ injuries.

In the past, mandatory surgical exploration for Zone 2 injuries that crossed the platysma muscle was the rule (8). However, several series of mandatory explorations yielded a negative rate of 40%–60% (9).

Selective non-operative management of neck injuries has steadily gained favour over the past few decades and even more so with recent advances in interventional radiology. It is generally thought that unstable patients should undergo emergency exploration while stable patients are reserved for interventional angiography. Although technically demanding, interventional angiography has diagnostic value and has been shown to significantly reduce morbidity rates (10). However, it is important that personnel trained to perform an emergency tracheostomy monitor the patient for signs of respiratory distress during this therapeutic procedure because loss of airway patency in neck trauma occurs precipitously, resulting in mortality rates as high as 33% (9).

The advantage of endovascular therapy in the avoidance of acute complications related to conventional open surgical repair (e.g., excessive haemorrhage and fluid shifts, possible anatomic distortion, and contaminated fields) is obvious (10). However, the challenge of endovascular repair remains the management of long-term complications, particularly in the case of endografts, due to their potential for migration and endoleaks (10).

In conclusion, isolated lingual arterial injury is uncommon in trauma settings. This report illustrates an example of safe and effective endovascular therapy of an actively haemorrhaging branch of the lingual artery.

Acknowledgement

The computed tomography films and description are courtesy of the Department of Radiology and Diagnostic Imaging, Universiti Kebangsaan Malaysia Medical Centre. No financial support was received from any other companies or agencies for the preparation of this report. The authors signed disclosures stating

that they have no proprietary or financial interest with any organisations with a direct interest in the subject matter of this manuscript.

Authors' Contributions

Conception and design, analysis and interpretation of the data, drafting of the article: AM

Provision of patient: BSG

Critical revision and final approval of the article: BSG, TYK, ZR

Correspondence

Associate Professor Dr Goh Bee See
MD (UKM), MS (ORL–Head and Neck Surgery) UKM
Department of Otorhinolaryngology–
Head and Neck Surgery
9th Floor, Clinical Block
Universiti Kebangsaan Malaysia Medical Centre
Jalan Yaacob Latiff, Bandar Tun Razak
56000 Cheras
Kuala Lumpur, Malaysia
Tel: +603-9145 6045
Fax: +603-9145 6675
Email: irenegbs@yahoo.com

References

1. Larsen DW. Traumatic vascular injuries and their management. *Neuroimaging Clin N Am*. 2002;**12**(2):249–269.
2. Scalfani SJ, Cavaliere G, Atweh N, Duncan AO, Scalea T. The role of angiography in penetrating neck trauma. *J Trauma*. 1991;**31**(4):557–563.
3. Sekharan J, Dennis JW, Veldenz HC, Miranda F, Frykberg ER. Continued experience with physical examination alone for evaluation and management of penetrating zone II neck injuries: Results of 143 cases. *J Vasc Surg*. 2000;**32**(3):483–489.
4. Atteberry LR, Dennis JW, Menawat SS, Frykberg ER. Physical examination alone is safe and accurate for evaluation of vascular injuries in penetrating Zone II neck trauma. *J Am Coll Surg*. 1994;**179**(6):657–662.
5. LeBlang SD, Nunez DB Jr. Noninvasive imaging of cervical vascular injuries. *AJR Am J Roentgenol*. 2000;**174**(5):1269–1278.
6. Demetriades D, Skalkides J, Sofianos C, Melissas J, Franklin J. Carotid artery injuries: Experience with 124 cases. *J Trauma*. 1989;**29**(1):91–94.
7. Cox MW, Whittaker DR, Martinez C, Fox CJ, Feuerstein IM, Gillespie DL. Traumatic pseudoaneurysms of the head and neck: Early endovascular intervention. *J Vasc Surg*. 2007;**46**(6):1227–1233.
8. Monson DO, Saletta JD, Freeark RJ. Carotid-vertebral trauma. *J Trauma*. 1969;**9**(12):987–999.

9. Jarvik JG, Philips GR 3rd, Schwab CW, Schwartz JS, Grossman RI. Penetrating neck trauma: Sensitivity of clinical examination and cost-effectiveness of angiography. *AJNR Am J Neuroradiol*. 1995;**16(4)**:647–654.
10. Reuben BC, Whitten MG, Sarfati M, Kraiss LW. Increasing use of endovascular therapy in acute arterial injuries: Analysis of the National Trauma Data Bank. *J Vasc Surg*. 2007;**46(6)**:1222–1226.
11. Fleck SK, Langner S, Baldauf J, Kirsch M, Kohlmann T, Schroeder HWS. Incidence of blunt craniocervical artery injuries: Use of whole body CT trauma imaging with adapted CT angiography. *Neurosurgery*. 2011;**69(3)**:615–624.