

# Ward Round: a jaundiced 43 year old man with cavitary lesions on chest radiograph

T Hartung<sup>1</sup>, J van Oosterhout<sup>2</sup>

1. Department of Respiratory Medicine, Victoria Hospital, Kirkcaldy, UK
  2. Department of Medicine, College of Medicine, Blantyre, Malawi
- Corresponding author: Thomas K Hartung, 7 Scotland Street, Edinburgh, EH3 6PP, UK, Tel: 0044 131 5563391, Email: Thartungafrika@yahoo.com

A 43 year old Malawian man was admitted to Queen Elizabeth Central Hospital (QECH) in March 2006. He complained of anorexia, vomiting and right upper quadrant abdominal pain for one week. He also reported weight loss and intermittent fevers for the past month. A productive cough was still troubling him despite starting treatment for sputum smear acid fast bacteria (AFB) negative pulmonary tuberculosis (PTB) two months earlier.

He had previously received treatment for AFB smear positive PTB in 1997 and AFB smear negative PTB in 2003. His HIV-infection had progressed to AIDS with episodes of shingles in 2003 and cryptococcal meningitis in November 2005. Persistent chest symptoms and an abnormal chest xray (figures 1a,b) but negative AFB sputum smears prompted commencement of anti-tuberculous medication when seen at QECH outpatients in early January 2006. Six weeks later triple antiretroviral therapy (ART) with Triomune® (a fixed dose combination of stavudine, lamivudine and nevirapine) was introduced at a district hospital.

Further medications on admission included fluconazole 200 mg daily as secondary prophylaxis after cryptococcal meningitis and ethambutol/isoniazid (EH) daily. He was unable to tolerate cotrimoxazole prophylaxis due to a previous severe skin rash. He denied usage of traditional medicine and did not take alcohol.

When first examined he was jaundiced, emaciated and a healed zoster scar over the left thigh were noted. His temperature was 38.8C, pulse rate 84/min, respiratory rate 16/min. Chest auscultation revealed bilateral coarse crackles. The right upper abdominal quadrant was tender but the liver could not be palpated.

Figure 1a: Chest Xray January 2006

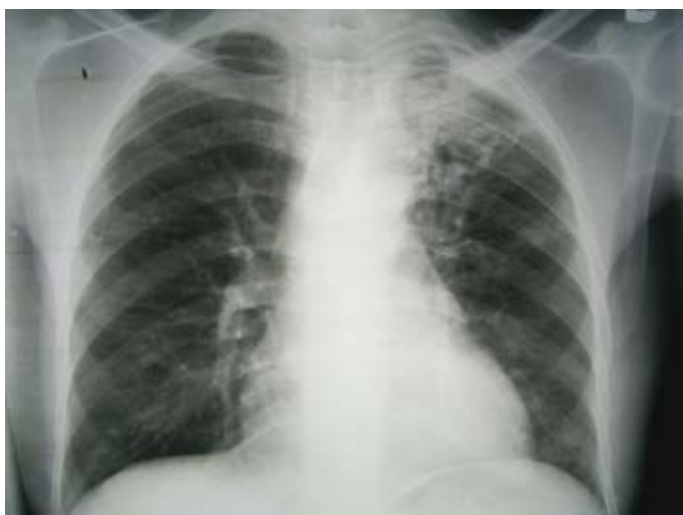
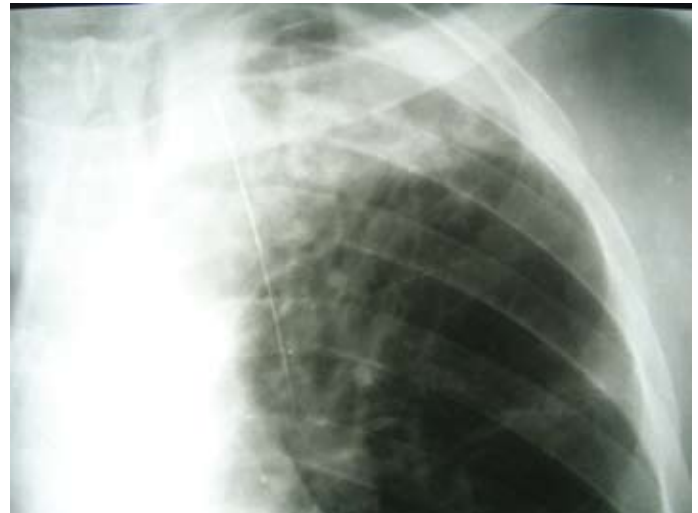
Figure 1b: Close up of left apical cavity

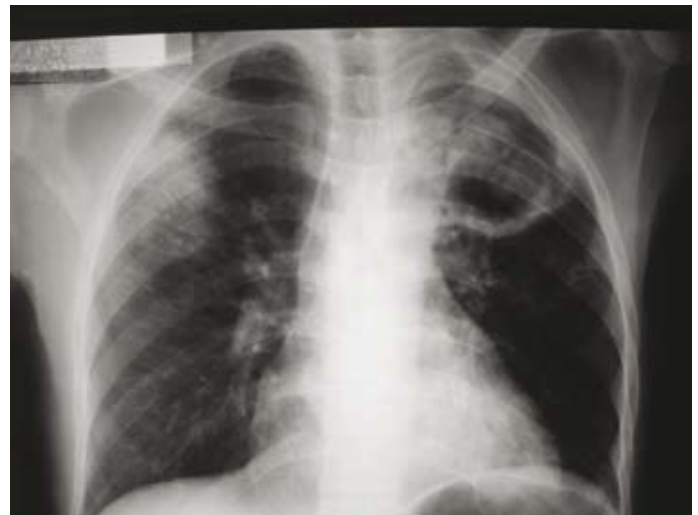

Blood Test		Normal Range
SGOT	233 U/l	<37
SGPT	159 U/l	<42
Alkaline phosphatase	592 U/l	<306
Albumin	3.0g/dl	3.8 - 5.1
Total bilirubin	3.7 mg/dl	<1.1
Direct bilirubin	2.7 mg/dl	<0.25
White blood counts	5.6 10 <sup>3</sup> /ul	3.6 - 10.8
Lymphocytes	1.2 10 <sup>3</sup> /ul	1.3 - 2.9
Neutrophils	3.9 10 <sup>3</sup> /ul	2.2 - 4.8
Haemoglobin	7.1g/dl	14 - 18

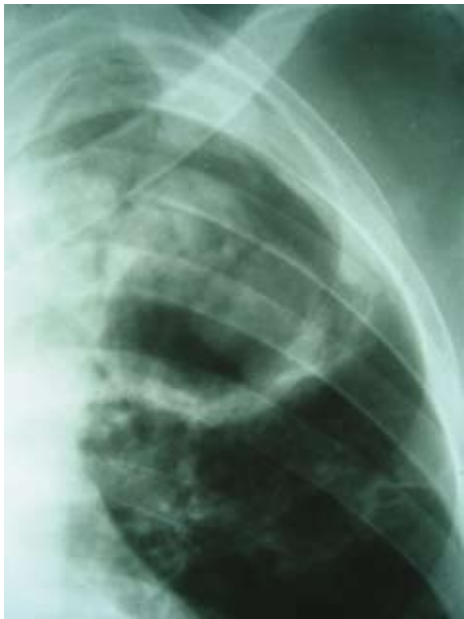Hepatitis B surface Antigen negative

The chest radiograph showed consolidation peripherally in the right upper and mid zones. A large, thick walled cavity containing 2 densities were seen in the left apex and, more faintly, a thin walled cavity in the left mid zone (figures 2a,b). Sputum smear for acid fast bacilli was negative on 3 occasions. Abdominal ultrasound showed a normal liver, biliary tree, pancreas and spleen.

Figure 2a: Chest Xray 2006



*Figure 2b: Close up of left upper and mid-zone cavities*



- 1. What are the possible causes for this man's jaundice?*
- 2. How do you explain the abnormalities seen on CXR?*

***Turn to pg 135 for discussion of this case.***

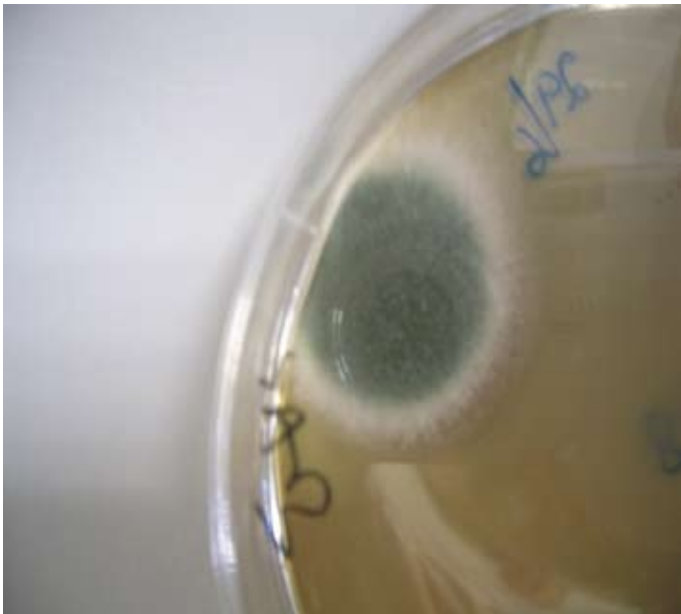
# Ward Round: a jaundiced 43 year old man with cavitary lesions on chest radiograph

*Continued from page 125*

## Progress

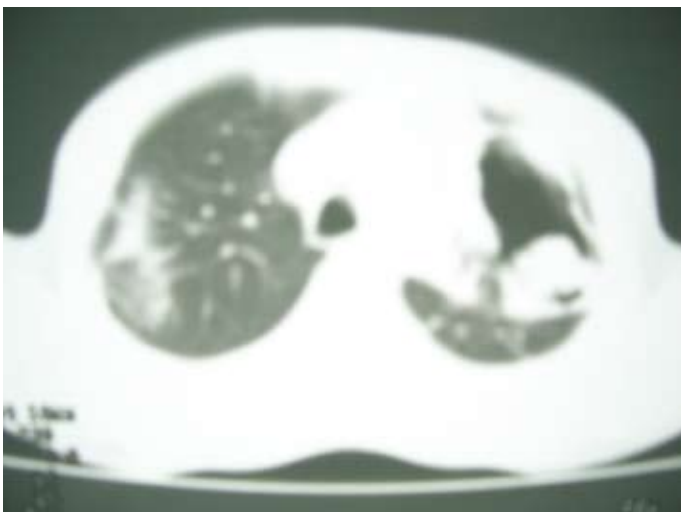
All drugs were discontinued except a tail of Lamivir-S 30® (stavudine, lamivudine) for a further week to prevent emergence of nevirapine resistance. He was given intravenous cefotaxime 2g bid for 10 days. His chest symptoms slowly improved and the fever settled. Bronchoalveolar lavage fluid of the left upper lobe and lingua segments grew a mould which was identified as likely *Aspergillus* spp (figure 3). Gram stain, culture, AFB smear and mycobacterial culture were all negative. Four weeks after stopping ART the CD4 count was 75 cells/ml.

*Figure 3: Fungal growth*

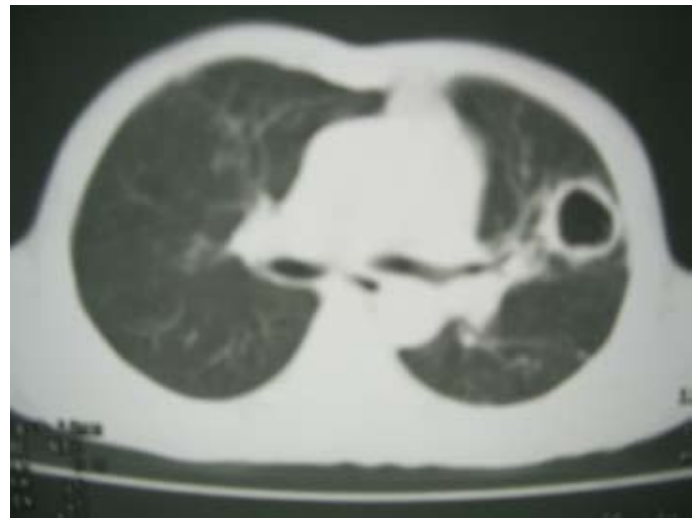

A CT chest more clearly showed a mass (fungus ball) within the left upper lobe cavity (figure 4a) and another cavity in the left mid zone (figure 4b). These cavities further evolved during the subsequent months (figures 5, 6).

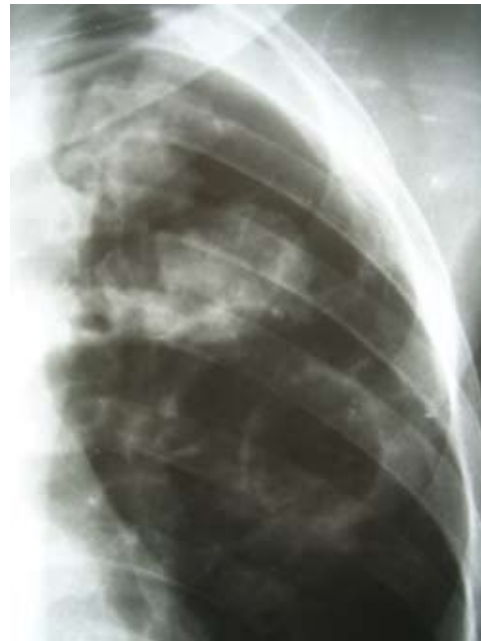*Figure 4a: CT chest April 2006, Left upper zone cavity with fungus ball*



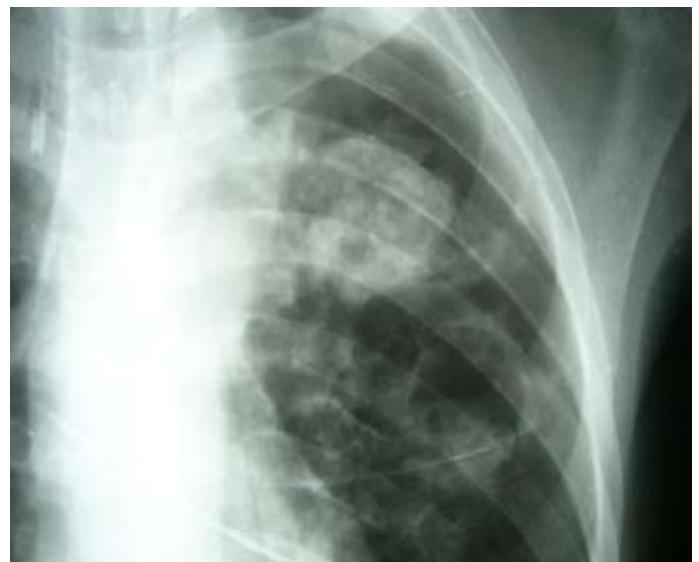*Figure 4b Left mid zone cavity*



*Figure 5 Chest Xray April 2006*



*Figure 6 Chest Xray May 2006*



## Discussion

1. The three principal mechanisms causing jaundice are pre-hepatic haemolysis, hepatocellular disruption and post-hepatic biliary obstruction. This patient was thought to have sustained drug induced hepatocellular inflammation given the medication history preceding this admission. Although both fluconazole and anti-tuberculous drugs are well known to cause hepatitis, the time-course would suggest nevirapine as the offending drug. There are reports suggesting that fluconazole can increase the nevirapine plasma level, but a study from Thailand did not show an increased risk of hepatotoxicity with combined use of nevirapine and fluconazole.<sup>1</sup> A viral etiology, such as hepatitis C, cytomegaly and EBV also has to be considered, either recently acquired or pre-existing and exacerbated by a reconstituting immune system as ART had been commenced 6 weeks earlier.<sup>2</sup>
2. The CXR most likely displayed several pathologies. Firstly, the history of sputum production, fever and abnormal auscultatory chest findings would suggest that the dense, rather ill defined right mid and upper zone consolidation was pneumonic in aetiology. Secondly, the evolving and enlarging left sided cavitary lesions give rise to a wider differential diagnosis and are more ambiguously explained. The presence of rounded densities within the left apical cavity as clearly demonstrated on CT imaging of his chest is highly suggestive of fungus balls due to *Aspergillus* spp (Figure 5a). Aspergillomas usually reside in preformed, often old tuberculous cavities. The main risk is massive haemoptysis if a bronchial artery is eroded.<sup>3</sup> A second left mid zone cavity, only faintly seen on the admission CXR in March but more obvious on subsequent images evolved and grew in size (figures 4, 5, 6). A clinical entity, termed 'chronic necrotizing aspergillosis' might account for these changes.<sup>4</sup> This is distinct from invasive aspergillosis which is classically seen in neutropenic patient and universally fatal if not recognised and treated early. The more indolent and much less dramatic picture of chronic necrotizing aspergillosis also named 'semi-invasive aspergillosis' has been described in patients with a lesser degree of immuno-suppression e.g. diabetes, malnutrition or steroid usage and usually in the context of pre-existing structural lung damage. Fever, cough and sputum production, though non-specific are often present. Cavitary infiltrates are seen on chest imaging which occasionally contain a fungus ball (mycetoma). Serum precipitins against *Aspergillus* are confirmatory and sputum culture might show fungal growth. Reports in HIV co-infected individuals exist<sup>5</sup>, however only 1 case of chronic necrotizing aspergillosis in the context of an immune reconstitution illness has previously been described.<sup>6</sup>

Management is far from straight forward and comprises surgical and medical approaches. Induction treatment with intravenous amphotericin-B followed by itraconazole in the consolidation phase has been tried but recurrences are feared. More recently a new antifungal drug, Voriconazole, has been reported to be equally effective and much better tolerated.<sup>7</sup> Fluconazole seems to have no effect. Ultimately, recovery of the immune system in patients with AIDS is the chief treatment goal and ART has been shown to prolong survival.<sup>5</sup> Alternative diagnoses include: 1. Worsening and

possibly drug resistant pulmonary tuberculosis or PTB immune reconstitution inflammatory syndrome (IRIS) after the start of ART, though these are less likely in the presence of negative mycobacterial microscopy and culture of bronchoalveolar lavage fluid. 2. Necrotizing bacterial pneumonia due to *Klebsiella pneumoniae* or *Staphylococcus aureus*, which tend to present in a more fulminant fashion. 3. More uncommon infections such as *Nocardia* (weakly gram positive and acid fast bacteria responding to high dose cotrimoxazole and other antimicrobials such as cephalosporins) or *Rhodococcus equi* (weakly acid-fast coccobacillus with typical salmon-coloured appearance of culture colonies requiring combination therapy of at least 2 drugs eg. vancomycin, rifampicin, imipenem, erythromycin). 4. Cavitary cryptococcal pneumonia has been described in the immune reconstitution phase of patient who started anti-retroviral (ART).<sup>8</sup> 5. Necrotizing malignancies such as bronchogenic squamous cell carcinoma (rare in young nonsmokers) or primary pulmonary lymphoma generally evolve more slowly. 6. Rheumatological disorders and the small vessel vasculitis of Wegner's Granulomatosis can present with cavitary lung lesions but usually other coexisting clinical pointers lead to the diagnosis.

Treatment with amphotericin-B was considered but not given as side effects of fever, nephrotoxicity, hypokalaemia and hepatotoxicity are commonly observed and close monitoring of renal and liver function tests could not be guaranteed at QECH. As his clinical condition improved, rapid reconstitution of the immune system through restarting ART was given first priority.

Liver enzymes normalised within 4 weeks and initially EH and then fluconazole were successively re-introduced uneventfully. Two months after the initial presentation he was commenced on alternative first line ART with Lamivir-S 30® (a fixed dose combination of lamivudine and stavudine) and efavirenz. He remained reasonably well with no fever and little sputum production. A further CXR showed the left mid zone cavity to have receded slightly. Sputum culture continued to grow a mould. He remained stable 2 months after starting ART. One year later he still returns bi-monthly for collection of ART and fluconazole.

## Conclusion

The combined treatment of tuberculosis and HIV can be extremely challenging in resource poor settings. As an example we described a patient with advanced AIDS presenting with drug-induced hepatitis, constitutional symptoms and progressive cavitary pulmonary lesions despite treatment with anti-tuberculous drugs. Although antituberculous drug resistance or tuberculosis-IRIS in patients commenced on ART might be implicated, alternative explanations should be sought. Here, repeated identification of a mould resembling *Aspergillus* spp. in sputum and BAL suggested the diagnosis of chronic necrotizing aspergillosis in the context a reconstituting immune system.

## References

1. Manosuthi W, Chumpathat N, Chaovavanich A, Sungkanuparph S. Safety and tolerability of nevirapine-based antiretroviral therapy in HIV-infected patients receiving fluconazole for cryptococcal prophylaxis: a retrospective cohort study. *BMC Infectious diseases* 2005;5:67-74.

2. Jevtovic DJ, Salemovic D, Ranin J, Zerjav S, Djurkovic-Djakovic O. The prevalence and risk of immune restoration disease in HIV-infected patients treated with highly active antiretroviral therapy. *HIV Med* 2005;6:104-43.
  3. Soubani AO, Chandrasekar PH. The clinical spectrum of pulmonary aspergillosis. *Chest* 2002;121:1988-99.
  4. Binder RE, Faling LJ, Pugatch AD, Mahasaen C, Snider GL. Chronic necrotizing pulmonary aspergillosis: A discrete clinical entity. *Medicine* 1982;61:109-24.
  5. Moreno A, Perez-Elias M, Casado J, Navas E, Pintado V, Fortun J, Quereda C, Guerrero A. Role of antiretroviral therapy in long-term survival of patients with AIDS-related pulmonary aspergillosis. *Eur J Clin Microbiol Infect Dis* 2000;19:688-
  6. Hasse B, Strebel B, Thurnheer A, Uhlmann F, Krause M. Chronic necrotizing pulmonary aspergillosis after tuberculosis in an HIV-positive woman: an unusual immune reconstitution phenomenon. *AIDS* 2005;19:2179-81.
  7. Herbrecht R, Denning DW, Patterson TF et al. Voriconazole versus amphotericine B for primary therapy of invasive aspergillosis. *N Engl J Med* 2002;347:408-15.
  8. Jenny-Avital ER, Abadi M. Immune reconstitution cryptococcosis after initiation of successful highly active antiretroviral therapy. *Clin Infect Dis* 2002;35:128-33.
-