

Ceftriaxone-Associated Nephrolithiasis in Children

Azita Fesharakinia*¹, MD; Ali-Reza Ehsanbakhsh², MD; Nasrin Ghorashadizadeh², MD

1. Department of Pediatrics, Birjand University of Medical Sciences, Birjand, Iran
2. Department of Radiology, Birjand University Medical Sciences, Birjand, Iran

Received: Jun 07, 2013; Accepted: Aug 26, 2013; First Online Available: Sep 28, 2013

Abstract

Objective: Ceftriaxone is a third-generation cephalosporin which is widely used for treatment of infection in children accompanied by complications like urinary tract lithiasis and gallbladder psudolithiasis or sludge. The aim of this study was to investigate the incidence and predisposing factors that contribute to these complications in children.

Methods: This quasi-experimental and before- and after-study was conducted in 96 children who were hospitalized for treatment of different bacterial infections and received 50-100 mg/kg/day ceftriaxone divided into two equal doses intravenously under conditions of adequate hydration. Sonographic examinations of urinary tract and gallbladder were carried out before and after treatment for that purpose. Patients with positive sonographic findings after treatment were followed with serial sonographic examinations.

Findings: Post-treatment sonography demonstrated nephrolithiasis in 6 (6.3%) and gallbladder stone in one (1%), all were asymptomatic. Comparison of the groups with and without nephrolithiasis demonstrated no significant differences with respect to age, body weight, diagnosis, season of hospitalization, dosage of drug and the duration of treatment. Nephrolithiasis had a significant relation with male gender ($P=0.02$).

Conclusion: Our results showed that pediatric patients may develop small sized, asymptomatic renal stones during a 2-6 day course of normal or moderate dose of ceftriaxone therapy. Close monitoring of ceftriaxone treated patients especially on high dose long term therapy for nephrolithiasis and gallbladder psudolithiasis or sludge is recommended.

*Iranian Journal of Pediatrics, Volume 23 (Number 6), December 2013, Pages: 643-647***Key Words:** Ceftriaxon; Children; Nephrolithiasis; Gallstone; Sonography

Introduction

Ceftriaxone is a widely used third-generation semi synthetic cephalosporin commonly administrated for treatment of different bacterial infections in children. Due to its broad spectrum against bacteria, long half-life and single daily dosing, physicians prefer to use it more frequently^[1]. Ceftriaxone is mostly eliminated through kidney and the remainder is eliminated via the biliary system. Its concentration in bile is 20 to 150 times

more than in plasma. It binds with calcium ions producing reversible precipitations that form biliary sludge and/or lithiasis, called psudolithiasis both in children and adults^[1-7]. A few studies have reported nephrolithiasis as another complication of ceftriaxone therapy^[8,9]. There are contradictory reports about the incidence of biliary pseudolithiasis and nephrolithiasis as well as the predisposing factors like age, gender, body weight, dose of drug and the duration of treatment^[6,7,9,10]. The aim of this study

* Corresponding Author;

Address: Pediatric Department, Vali-e-asr Hospital, Birjand University of Medical Sciences, Birjand, IR Iran

E-mail: fesharakinia@yahoo.com

© 2013 by Pediatrics Center of Excellence, Children's Medical Center, Tehran University of Medical Sciences, All rights reserved.

was to investigate the incidence and predisposing factors that contribute to this kind of complications in children.

Subjects and Methods

This quasi-experimental and before- and -after study was conducted in 96 children aged from one month to 13 years (mean age 1.88 ± 1.98 years) hospitalized with different types of infection in Vali-e-Aser Hospital in Birjand city from September 2011 until March 2012. The infections included gastroenteritis (48%), pneumonia (26%), septicemia (14%), sinusitis (6%), pyelonephritis (5%) and febrile convulsion with acute otitis media (1%). Patients suffering from renal disease, hepatobiliary disease, hemolytic anemia, malabsorption or any chronic disease were excluded. All patients received the same ceftriaxone preparation (Rocephin) intravenously with different daily doses (50-100mg/kg/day divided into two equal doses) during 15 minutes under adequate hydration. The children were monitored every day for signs of dehydration and if they were dehydrated, received enough oral or intravenous fluids in adequate doses. For each case, urea, creatinin and calcium serum levels recorded before and after treatment. Demographic parameters: age, gender, body weight, diagnosis, season of hospitalization, dosage of ceftriaxone and the duration of treatment were assessed. All patients underwent sonography of the gallbladder and urinary tract before the first injection of ceftriaxone and after the end of treatment period. Sonography was performed by a Medison model V-10, with convex probe 3-5 MHz and linear probe 5-10 MHz.

Patients demonstrating any pre-existing or underlying urinary tract abnormalities such as

obstructive malformation and/or stone in urinary tract and/or gallbladder in first sonography were excluded from the study. Diagnosis of nephrolithiasis and biliary stone was based on standard criteria including the presence of echogenic foci with posterior shadow in the renal pelvicalical system or in the gall bladder which were indicative of renal or gall stones. Moreover, low-level echo materials which lined in the dependent portion of the gall bladder without posterior acoustic shadowing were diagnosed as biliary sludge. Positive sonographic findings were confirmed by another sonographer. Emergency sonography was carried out if patients showed any renal symptoms and complications (colicky abdominal pain, anuria, acute renal failure) and/or biliary symptoms (right upper quadrant pain, cholestasis). Children with positive sonographic findings after treatment were followed with weekly sonography in the first two weeks and thereafter every two weeks until disappearance of these findings. Statistical analysis was performed using SPSS version 13, Mann-Whitney, Fisher's exact test and independent t-test. A *P*-value of less than 0.05 was considered to indicate statistical significance.

Findings

A total of 96 children participated in the study, 55 (57.3%) of the patients were boys. While 22% of them were admitted in summer, numbers of participants in three other seasons were equal (26% in each season). Serum levels of urea, creatinine and calcium were in normal range before and after treatment. Post-treatment sonography demonstrated nephrolithiasis in six (6.3%) and gallbladder stone in one (1%) of the 96 subjects without any related symptoms.

Table 1: Characteristics of patients with and without nephrolithiasis

Parameter	With(n=6)	Without (n=90)	P-value
Gender (male/female)	6/0	49/41	0.02
Mean age (SD) (years)	2.18 (2.95)	1.86 (1.93)	NS
Mean weight (SD) (kg)	12.33 (5.4)	9.58 (4.4)	NS
Mean dosage (SD) (mg/kg/day)	55 (9.4)	58.9 (15.4)	NS
Duration of treatment (SD) (days)	3.86 (1.34)	3.38 (1.2)	NS

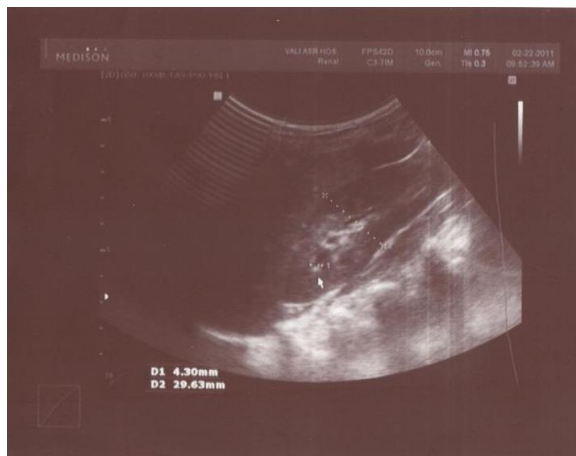


Fig. 1: white arrow shows renal stone in upper pole of right kidney (patient number 6)

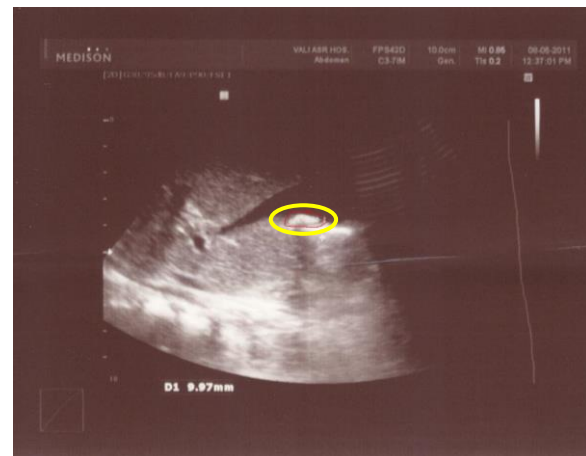


Fig. 2: Circle shows stone in the gallbladder

Comparison of the groups with and without nephrolithiasis demonstrated no significant differences with respect to age, body weight, dosage of drug and the duration of treatment. Nephrolithiasis showed a significant relation with male gender ($P=0.02$) (Table 1).

There was no significant differences between the two groups in terms of diagnosis and season of hospitalization ($P>0.05$) (Table 2).

In patient number 1, stone was disappeared in the third sonography. In patients number 2 and 6 (Fig. 1), stones were present till the third sonography, the patients did not reappear for further examinations. Patient number 2, 4 and 5 did also not come back for follow up. Only in one patient, a 22-month old boy, who was admitted for gastroenteritis and received 50mg/kg/day ceftriaxone for 3 days, a 10 mm stone was detected in gallbladder after completion of treatment. He was not brought back for follow up (Fig. 2). Nephrolithiasis was not present in any of our patients with diagnosis of pyelonephritis.

Discussion

Biliary sludge or pseudolithiasis is a known side effect of ceftriaxone therapy which has been reported since 1986^[11]. Nephrolithiasis is a less common side effect of ceftriaxon^[8,9]. Chutipongtanate and Thongboonkerd^[12] showed that ceftriaxone at therapeutic levels could be crystallized with free calcium in the urine under physiologic condition. They hypothesize that tubular occlusion and crystal-cell adhesion may play an important role in pathogenic mechanisms of ceftriaxon-induced nephrolithiasis.

Present study showed that 6.3% of the children developed small sized renal stone and one (1%) patient had gallbladder stone while on ceftriaxone and all were silent.

In Mohkam et al study^[8] in 284 children with pyelonephritis, the incidence of nephrolithiasis was 1.4%. Avci^[9] et al detected nephrolithiasis in 4 (7.8%) of 51 children with various infections, and all were silent.

Table 2: Clinical features and details of the six nephrolithiasis cases

No	Sex	Age	Infection type	Dose (mg/kg/day)	Tx duration (days)	Nephrolithiasis location
1	M	5 months	Pneumonia	55	3	2mm, Rk middle pole
2	M	7 months	pneumonia	75	6	3mm, Rk upper calyx
3	M	12 months	Gastroenteritis	60	5	2mm, Lk upper pole
4	M	31 months	acute sinusit	60	2	2mm, Rk upper pole
5	M	8 years	Gastroenteritis	50	4	2mm, Rk upper pole
6	M	8years	acute sinusit	50	4	3mm, Rk upper pole

Tx: treatment; RK: right kidney; LK: left kidney

Acun et al^[13] reported that 5 of 35 children developed gallbladder and urinary tract precipitations; three of them had gallbladder pseudolithiasis, one gallbladder sludge and one gallbladder pseudolithiasis and urinary bladder sludge. Biner et al^[3] in 156 children demonstrated abnormal gallbladder sonograms in 27 (17%) children and urolithiasis in 1 (0.6%). Five (19%) children with pseudolithiasis became symptomatic. In Schaad study^[11] Biliary concerns developed in 16 of 37 (43%) patients causing symptoms in 3, one of whom also had urolithiasis with renal colic and obstructive ureteropyelectasia. Araz et al^[4] found that all 8 (100%) children who received ceftriaxone 100mg/kg/day for meningitis had positive sonographic findings: 4 patients had biliary sludge with gallstone, 3 had gallstone and one biliary sludge.

The incidence of pseudolithiasis and sludge in the gallbladder was 57.6% in Ozturk study^[5], 3.3% in Kong study^[6], 17% in Palanduz study^[7] and 18.5% in Esmaeili study^[10]; all of them were asymptomatic.

In present study, as that Mohkam^[8] and Avci^[9] studies, there was no significant difference in terms of age between patients with and without nephrolithiasis, but in Avci study^[9] the mean of patients' age in the nephrolithiasis group was significantly lower than that of the group without nephrolithiasis. The authors suggested that young age may be a risk factor for the formation of urinary stones during ceftriaxone therapy.

In the present study, there was a significant relation between nephrolithiasis and male gender. While there was no significant difference according to gender in Mohkam^[8] and Avci^[9] studies.

In Avci study^[9], renal stones developed during a 7-day course of normal or high doses of ceftriaxone therapy. In the present study, small size renal stones developed during a 2-6 day course of normal or moderate doses of ceftriaxone therapy and there was no significant difference according to dose of ceftriaxone and duration of treatment between two groups with and without nephrolithiasis. Some authors have reported high doses of ceftriaxone and longer treatment time are risk factors for the development of nephrolithiasis^[14,15].

In present study, most of the patients did not come back for follow up sonography. In Mohkam

study^[8], follow up sonography after 3 months of treatment was normal. In Avci study^[9], the renal stones disappeared spontaneously 3-4 weeks later in three out of four cases; however, it was still present in one patient 7 months after ceftriaxone therapy. The time for disappearance of ceftriaxone associated nephrolithiasis was varied from 5 days to three weeks in other reports^[14,15].

Our study had some limitations. Most of our positive sonographic patients did not come back for complete follow up sonography and we did not investigate the metabolic disturbances such as hypercalciuria, hyperuricuria, cystinuria and hyperoxaluria.

Conclusion

Our study showed that pediatric patients may develop small sized, asymptomatic renal stones during a 2-6 day course of normal or moderate dose of ceftriaxone therapy. Close monitoring for nephrolithiasis and gallbladder stone or sludge in ceftriaxone treated patients is recommended especially on high dose and long term therapy.

Acknowledgment

This study was approved by the ethical committee of Birjand University of Medical Sciences. The authors would like to thank Dr. Mohamad-reza Abedini for his assistance for editing this article.

Conflict of Interest: None

References

1. Richards DM, Heel RC, Brogden RN, et al. Ceftriaxone. A review of its antibacterial activity, pharmacological properties and therapeutic use. *Drugs* 1984;27(6):469-527.
2. Choi YY, Jung YH, Choi SM, et al. Gallbladder pseudolithiasis caused by ceftriaxone in young adult. *J Korean Surg Soc* 2011;81(6):423-6.
3. Biner B, Oner N, Celtik C, et al. Ceftriaxone-associated biliary pseudolithiasis in children. *J Clin Ultrasound* 2006;34(5):217-22.

4. Araz N, Okan V, Demirci M, et al. pseudolithiasis due to ceftriaxon treatment for meningitis in children: report of 8 cases. *Tohoku J Exp* 2007;211(3):258-90.
5. Ozturk A, Kaya M, Zeyrek D, et al. Ultrasonographic findings in ceftriaxon: associated biliary sludge and psudolithiasis in children. *Acta Radiol* 2005;46(1):112-6.
6. Kong MS, Chen CY. Risk factors leading to ceftriaxon - associated biliary psudolithiasis in children. *Changcheng yi Xue za Zhi* 1996;19(1):50-4.
7. Palanduz A, Yalcin L, Tonguc E, et al. Sonographic assessment of ceftriaxon-associated biliary psudolithiasis in children. *J Clin Ultrasound* 2000;28(4): 166-8.
8. Mohkam M, karimi A, Gharib A, et al. Ceftriaxon associated nephrolithiasis: a prospective study in 284 children. *Pediatr Nephrol* 2007;22(5):690-4.
9. Avci Z, Koktener A, URAS N, et al. Nephrolithiasis associated with ceftriaxon therapy: a prospective study in 51 children. *Arch Dis Child* 2004;89(11):1069-72.
10. Esmaeili Dooki MR, Norouzi A. Cholelithiasis in Childhood: A Cohort Study in North Iran. *Iran J Pediatr* 2013;23(5):588-592.
11. Schaad UB, Wedgwood-Krucko J, Tschaeppler H. Reversible ceftriaxon- associated biliary psudolithiasis in children. *Lancet* 1988;2(8625):1411-3.
12. Chutiponqtanate S, Thonqboonkerd V. Ceftriaxon crystallization and its potential role in kidney stone formation. *Biochem Biophys Res Commun.* 2011; 406 (3):396-402.
13. Acun C, Erdem Lo, Sogut A, et al. Gallbladder and urinary tract precipitations associated with ceftriaxon therapy in children: a prospective study. *Ann Trop Paediatr* 2004;24(1):25-31.
14. Prince JS, Senac MO. Ceftriaxon associated nephrolithiasis and biliary psudolithiasis in a child. *Pediatr radiol* 2003;33(9):648-51.
15. De Moor RA, Egberts AC, Schroder CH. Ceftriaxon-associated nephrolithiasis and biliary psudolithiasis. *Eur J Pediatr* 1999;158(12):975-7.