

## CASE REPORT

# AN UNUSUAL CASE OF CONJOINED TWINS

J. Hitayezu<sup>1</sup>, J. Gashegu<sup>2</sup>, J. Vyankandondera<sup>3</sup>, L. Mutesa<sup>4,\*</sup>

<sup>1</sup> Kabutare District Hospital, Southern Province, Rwanda

<sup>2</sup> Clinical Anatomy Laboratory, Faculty of Medicine, National University of Rwanda,

<sup>3</sup> Department of Gynecology & Obstetrics, Kigali University Teaching Hospital,

<sup>4</sup> Center for Medical Genetics, Faculty of Medicine, National University of Rwanda,

## ABSTRACT

Conjoined twins are not a usual anomaly seen at birth and certainly people may have different or wrong beliefs about this malformation especially when seen for the first time. In this article, we review some important cases of conjoined twins in the history and we present a very rare case of parapagus united twins after an overview of literature. We will end up with a short discussion and conclusion.

**Key-words:** Biddenden maids, siamese twins, parapagus

## RESUME

Les jumeaux siamois ne sont pas une anomalie habituellement constatée à la naissance et ils peuvent susciter des convictions différentes ou erronées à des gens différents, surtout lorsque vus pour la première fois. Dans cet article on passe en revue quelques cas intéressants de jumeaux conjoints décrits dans l'histoire, la littérature et on présente un cas très rare de jumeaux conjoints parapagus. On terminera par une brève discussion et conclusion.

**Mots clés:** Servantes Biddendon, jumeaux siamois, parapagus

## INTRODUCTION

The earliest example of conjoined twins is a statue of sisters dating from the sixth millenium BC and housed in the Anatolian Civilisation Museum in Ankara, Turkey. The first anecdotal reports of viable conjoined twins in european medical history have cited a case of the Biddenden maids- Mary and Eliza- born in AD 1100 and joined at the hips and the shoulders. They lived together for 34 years. Eliza refused to be separated from her dead sibling and she also died 6 hours later. The first successful separation of conjoined twins was performed by Johannes Fatio in 1689, but it was credited to Koenig who published the case as his own. Nevertheless, the first well-known case was not documented until 1811, when two boys, Chang and Eng, were born to chinese parents in Siam (now Thailand) attached to each other at the sternum; they were exhibited world wide by P.T. Barnum. They married sisters and had 22 children between them. They lived together for 63 years. Hence conjoined twins are commonly referred to as siamese twins [1,2,3,4].

The frequency of conjoined twins is not well established,

and the estimated incidence varies in the literature occurring in approximately 1 in 50 000–100 000 and 1:600 twin births. Conjoined twinning is three times more common in female fetuses than in males [3].

Conjoined twins are classified according to the most prominent site of union together with the suffix pagus, meaning fixed. Ventral unions occur 87% of the time and are classified as: cephalopagus (11%), thoracopagus (19%), omphalopagus (18%), ischiopagus (11%), and parapagus (28%). Dorsal unions occur in 13% of conjoined twins and are classified as: craniopagus (5%), rachiopagus (2%), and pygopagus (6%) [ 3,4]. Another most used classification takes into account the shared body site as follows: anterior or thoracopagus, posterior or pygopagus, cephalic or craniopagus and caudal or ischiopagus.

Surgical treatment is nowadays more and more performed around the world. Among known recent siamese separated these 4 last years, we can quote 5 cases: 1) Milagros and Ruth Guelac born in Lima, Peru on October 22, 2009. They shared one heart and intestines, so they were impossible to separate. 2) Hassan and Hussein Benhaffal were born on December 2, 2009 at University College Hospital, London and then transferred to Great Ormond Street Hospital, london where they were successfully separated in March 2010. Their parents are natives of Cork, Ireland. 3) Kauany Aparecida and Keroly Joice born in Campo Grande, Brazil on March 5, 2010. They share one thorax and one abdomen. 4) Hanna Yaneth and Hanna Yineth born in Panama. They

\* Correspondence to:

Léon MUTESA, MD, PhD  
Center for Medical Genetics  
University Teaching Hospitals/Kigali & Butare  
National University of Rwanda  
Tel : +250 788 45 10 13  
E-mail address: lmutesa@nur.ac.rw

shared the liver and were connected through the abdomen. They were separated successfully on September 28, 2010. Hanna Yineth's kidney never worked after the separation and in October 10th died as result of a cardiac arrest. 5) Ram and Laxman born in Chhattisgarh, India in 2006, successfully separated at MCHR, Raipur, CG.

### Pathogenesis

Conjoined twinning is a rare complication affecting monozygotic twinning. Monozygotic twins result from splitting of embryo at different stage of development. The most common monozygotic twinning mechanism is splitting of the inner cell mass of the blastocyst during the hatching process around 7 days after fertilization. Most of the time, this complication happens when the division initiates after eighth days, the embryonic disk completely formed and results in a monozygotic, monoamniotic, monochorionic twin pregnancy.

Conjoined twins are developed if there is incomplete division of the inner cell mass or if there is late fusion of the two inner cell masses. In rare cases the separation occurs at the bilaminar germ disc stage, just before the appearance of the primitive streak. At later stage of the early embryo development during the formation of primitive node and streak the twinning process may occur.

The outcome of the twinning process depends on when the splitting occurs. If division is initiated early at the blastocyst stage, the twins develop normally and the extent of connection between conjoined twins depends on the amount of non splitting area but the general appearance may be quite normal. Late division of the primitive node and streak generally results in conjoined as the node and streak split after initiation of the gastrulation. The precise etiology of conjoined twinning is still unknown but misexpression of developmental genes such as Goosecoid by the primitive node or notochord is known to result in conjoined twins [1,3, 5, 6].

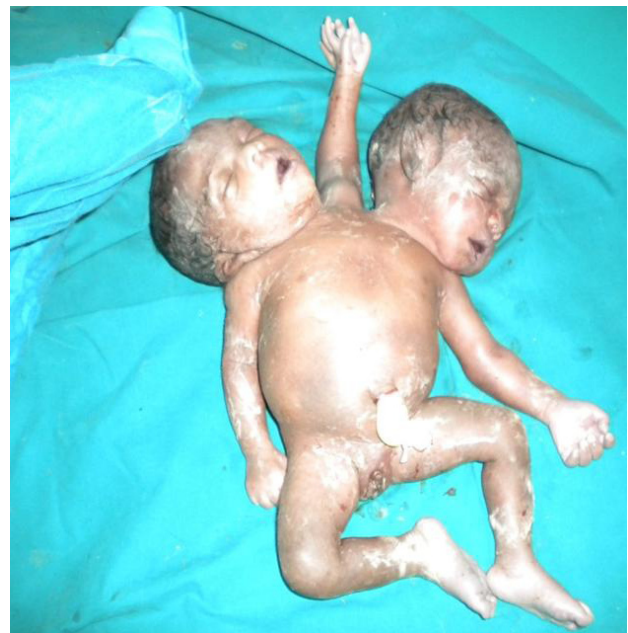Depending on the pole where incomplete division of the embryonic disc occurs, the result will be 2 heads, 2 to 4 arms, etc. If both poles are involved, combinations are then observed [7]. Diagnosis, Management and outcome The diagnosis of conjoined twins can be made by ultrasound in the first trimester or at middle pregnancy. Suspicious features include among others lack of a separating membrane between the twins and a constant position of the fetal heads. Follow-up imaging should be performed to confirm the diagnosis and further information may be gained by magnetic resonance imaging (MRI) and computed tomography (CT) evaluation. Prenatal diagnosis is important before counseling is provided and allows parents to decide whether to continue the pregnancy. The prognosis and surgical separation (that may be emergent or elective at 2-4 months of age) success of conjoined twins largely depend on the site of conjoining and the

organs involved.

Most of cases die in utero or immediately after birth [3].

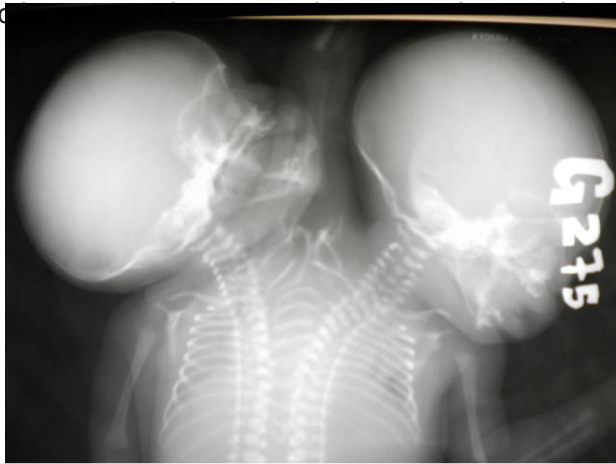
### Case presentation: a rare form of parapagus conjoined twins

During the night of August 18-19th, 2010, a 28-year old woman, gravida 4, para 3, alive 3 was referred to Kabutare district hospital from a local health center for breech presentation after a delivery labor had started. In her personal history, she did not remember the date for her last menstrual periods, used to take contraceptives (pills or injections) between a pregnancy and the following and she had not been aware of the current pregnancy until she started feeling fetal movements because she conceived after missing an appointment for injection of a contraceptive. No special remarks were detected during prenatal visits at health center and there was no ultrasound performed before. On arrival an emergent cesarean delivery was performed and we extracted a two headed female baby with 2 separate upper limbs, a third common upper limb bearing 8 fingers on fused hands, on mirror image feature according to Bateson's rule, which states that when duplicated structures are joined during critical developmental stages, one structure is the mirror image of the other, between the 2 heads and 2 lower limbs on a single trunk (Fig. 1).

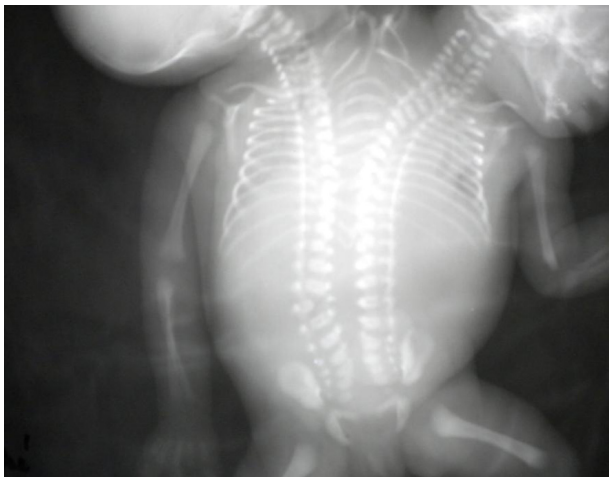


**Figure 1:** Photograph of parapagus conjoined twins born on August 19th, 2010 in Kabutare district hospital.

The baby (or babies) died within five minutes after birth. Post mortem X-rays revealed two vertebral columns on a common pelvis and there was no autopsy done on the baby.



**Figure 2:** Postmortem X-rays of the parpagus united twins photographed above showing skulls and chest.



**Figure 3:** Postmortem X-rays of the parpagus united twins photographed above showing the entire trunk and pelvis skeleton.

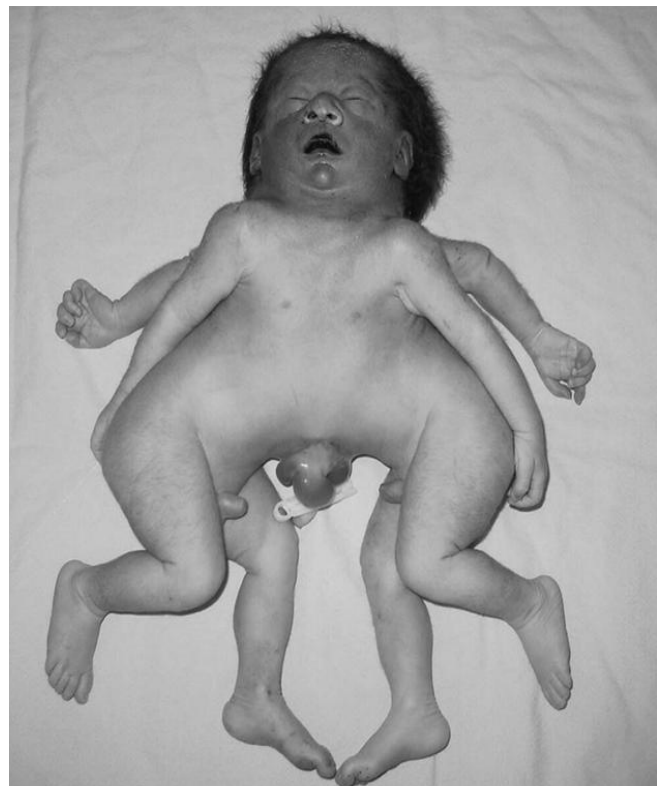The first 3 children of the family are healthy. The DNA sample for these conjoined twins was extracted and conserved for further molecular genetic tests.

## DISCUSSION

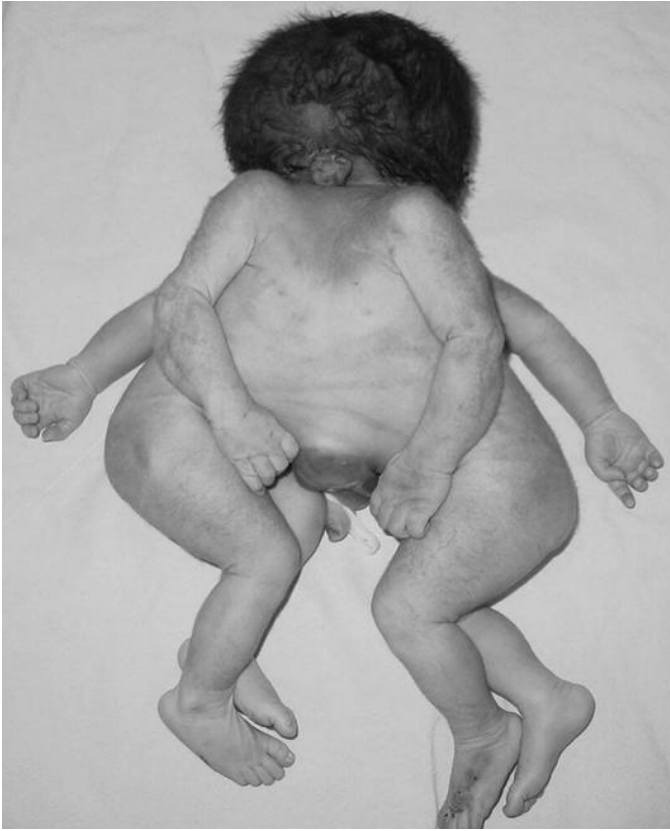The conjoined twins presented in this paper may have resulted from late splitting at gastrulation stage of embryo development. The primitive streak and node start at caudal part of the embryonic disc and progress cranially [5, 6]. When the node reach the prechordal plate at the edge of the pharyngo-oral membrane, the node regress cranio-caudally and induce neural tube development. The developing neural tube induce myotome development, the sclerotome component of the myotome is the primordial of the vertebral column [5, 6]. The fact that this conjoined twins have two vertebral columns but common pelvis and lumbar is a testimony that gastrulation began but then split into two primitive streak and node which induce two axial skeletons. As consequence of these common caudal structure of the axial skeleton, this conjoined

twins have one pair of lower limbs which is an additional argument supporting the idea that the splitting began after gastrulation has started.

In humans, delayed ovum transport through the fallopian tube increases the risk of twinning; progestational agents and combination contraceptives may be the origin of this delay due to decreased tubal motility [1]. This lady conceived in close temporal proximity of contraceptive use, which may have increased the risk of twin pregnancy of course not the risk congenital abnormality happened and this should not be a pretext to fear or reject the use of contraceptives. On the classification point of view, these twins were conjoined laterally and may be classified as parapagus united twins (Fig. 4, 5) [3, 8], and the fused parts could not allow extra uterine survival. Pregnancy termination, if informed consent obtained, would have been a better option if ultrasound prenatal diagnosis was made.



**Figure 4:** Postmortem photograph of cephalothoracoomphalopagus conjoined twins- anterior aspect [3].



**Figure 5:** Postmortem photograph of cephalothoracoomphalopagus conjoined twins- posterior aspect [3].

is unknown although the mechanism may be understood by good examination of the conjoined. Surgical separation might be possible if conjoined twins do not share vital organs and depending on the complexity of the fusion area. Prenatal diagnosis is essential and therapeutic pregnancy termination may be a parental option, especially for cases with a poor prognosis after genetic counseling.

### REFERENCES.

1. Cunningham FG, et al: William's obstetrics, 22nd edition. Dallas 2005: The McGraw-Hill Companies.
2. Dwight PC. Intrapartum management of twin gestations. *Obstetrics and gynecology* 2007; 109:1167-1176.
3. Kokcu A, Catinkaya MB, Tosun M, et al. Conjoined twins: historical perspective and report of a case. *The journal of maternal-fetal and neonatal medicine* 2007; 23(9): 923-926
4. Spitz L, Kiely EM. Conjoined twins. *JAMA* 2003; 289(10):1307-1310.
5. Langman's Medical Embryology, 9th Edition 2004, Lippincott Williams & Wilkins
6. Carlson BM, Human Embryology & Developmental Biology, 2nd Edition 1999, Mosby.
7. Cunningham FG, Leveno Bloom SL, et al. Williams Obstetrics, 20th edition 2005.
8. Kim SC, Jo DS, Jang KY, et al. Extremely rare case of cephalothoracopagus characterized by differences of external genitalia. *Prenat diagn.* 2007; 27: 1151-3.

### CONCLUSION

Conjoined twins commonly referred to as siamese twins may have been known for many years. Their exact cause