

EFFECTS OF *FICUS THONNINGII* EXTRACTS ON THE GASTROINTESTINAL TRACT AND CLINICAL BIOCHEMISTRY OF SUCKLING RATS*R. Dangarembizi^{1,2}, K.H. Erlwanger¹, E. Chivandi¹¹School of Physiology, Faculty of Health Sciences, University of the Witwatersrand, 7 York Road, Parktown 2193, Johannesburg, South Africa²Faculty of Medicine, National University of Science and Technology, Box AC939, Ascot, Bulawayo, Zimbabwe*E-mail: rachaeldangarembizi@gmail.com**Abstract****Background:** *Ficus thonningii* is commonly used in traditional medicine across the African continent. We investigated the effects of crude *Ficus thonningii* extracts on growth, morphology and morphometry of the abdominal viscera and clinical biochemistry of neonatal rats.**Materials and Methods:** Forty, 6-day old Sprague Dawley rat pups were orally gavaged once daily with either low (50 mg.kg⁻¹ b.w) or high (500 mg.kg⁻¹ b.w) doses of aqueous or methanolic *F. thonningii* leaf extracts while the control received distilled water. After 7 days of treatment, the pups were euthanased and gross morphometric measurements of the abdominal visceral organs were recorded. Samples of the liver, caecum and proximal small intestine were processed for histology. Plasma biochemical parameters were analysed colorimetrically.**Results:** High methanolic doses of *F. thonningii* extracts exhibited trophic effects on the stomach while both aqueous and methanolic extracts had trophic effects on the ceecal mucosa of rats. No significant growth-promoting effects were observed in other visceral organs. Histological analysis revealed no mucosal damage or necrosis. Clinical biochemistry parameters were not abnormally altered. There was a significant decrease ($p < 0.05$, ANOVA) in the plasma concentration of non-fasting glucose in the high methanolic group but triglycerides and cholesterol were unaltered.**Conclusion:** The findings suggest that at low doses, *F. thonningii* extracts can be safely used without the risk of any disruption in the structural integrity of the neonatal rat GIT and function of the liver and kidneys.**Key words:** *Ficus thonningii*, neonate, clinical biochemistry, gastrointestinal tract, histology**Introduction**

Ficus thonningii is a traditionally important plant species with both nutritional and therapeutic benefits. Commonly known as the common wild fig, *F. thonningii* is mainly distributed in upland forests of tropical and sub-tropical Africa (Agroforestry tree database, 2011). *F. thonningii* leaves are alternate and dark green whilst the fruits which are about 10-20 mm in diameter are usually yellow, turning pinkish when ripe (Schmidt et al., 2002). The tree is popular for its medicinal properties and is used in the treatment of various disease conditions. A full botanical and taxonomic description and a detailed review of the nutritional benefits, phyto-chemical content, and pharmacological properties of *F. thonningii* has been reported by Dangarembizi et al. (In Press). The leaves are used for the treatment of diarrhoea, gonorrhoea, diabetes, jaundice, scabies, wounds, bronchitis, urinary tract infections, urinary schistosomiasis, gastric ulcers and colitis (Njoronge and Kibunga, 2007; Cousins and Huffman, 2002; Bah et al., 2006; Nwude and Ibrahim, 1980; Alawa et al., 2002). The stem bark is used for treating colds, arthritis, inflammation, pneumonia, bronchitis, diarrhoea, constipation, bowel disorders and to stimulate lactation (Prelude medicinal plant database, 2011; Teklehaymanot and Gidday, 2007; Watt and Breyer-Brandwijk, 1962; Gelfand et al., 1985; Minja, 1994). *F. thonningii* roots are used for treating malaria, fever, hepatitis; for preventing miscarriages and for stopping bleeding (Gelfand et al., 1985, Prelude medicinal plant database, 2011).

The therapeutic properties of *F. thonningii* result from the presence of a number of phytochemical compounds. Flavonoids (orientin, vitexin and isovitexin), and stilbenes which include the cardio-protective stilbene resveratrol and its glycosides have been isolated from *F. thonningii* leaves (Greenham et al., 2007). Tannins, alkaloids, terpenes, saponins and cardiac glycosides have also been isolated from various parts of *F. thonningii* (Ndukwe et al., 2007; Usman et al., 2009; Bamikole et al., 2004). *F. thonningii* leaves contain other secondary metabolites such as lignins, lignans and active proteins such as ficin, which add to their pharmacological and biological activity (Ahur et al., 2010). *F. thonningii* leaves have also been shown to contain essential oils which are composed mainly of 6, 10, 14 trimethyl-2-pentadecanone (18.8%), phytol (14.7 %), acorenone (7.6 %) and β -gurjunene (6.3%), (Ogunwande et al., 2008).

F. thonningii remedies are commonly prepared as decoctions, macerations and infusions and the extracts are taken orally. The gastrointestinal tract (GIT), is the first point of contact of the extracts with the body. The GIT is a sensitive specialised organ whose exposure to phytochemicals could result in beneficial or detrimental physiological effects. Exposure to phyto-chemicals has been shown to induce structural, maturational and functional changes on the GIT particularly in neonates where permeability is relatively high (Linderth et al., 2005; Erlwanger and Cooper, 2008; Beya et al., 2012). We hypothesised that exposure to phytochemicals from *F. thonningii* may affect the proliferation and differentiation of intestinal epithelial cells resulting in structural and functional changes in the GIT without adverse effects on the general health of the rats. This study was therefore carried out to determine the effects of *F. thonningii* extracts on growth, gastrointestinal morphometry and clinical biochemistry using the neonatal rat model.

Materials and Methods**Plant collection and Extraction**

Ficus thonningii leaves were sourced from Gweru (19.75°S: 29.9°E), in the Midlands province of Zimbabwe. Verification of the specimen was done by botanists Burrows and Burrows, facilitated by the School of Animal, Plant and Environmental Sciences within the Faculty of Science at the University of the Witwatersrand. The leaves were cleaned of all foreign material and dried in an oven at 40°C for 24 hrs. The crisp, dry leaves were ground to a fine powder using a Waring blender (Waring®, Lasec SA Company, USA). Eighty grammes of the leaf powder were macerated in 1L of either distilled water or methanol at 25°C for 24 hours. Extracts were filtered using Whatman 1 filter paper and the filtrate was concentrated using a rotor evaporator (Labocon (Pty) Ltd, Krugersdorp, Transvaal, South Africa). Extracts were dried in an oven

<http://dx.doi.org/10.4314/ajtcam.v11i2.10>

(Salvis®, Salvis Lab, Schweiz, Switzerland), at 40°C and the residual solid extracts were recovered and stored in dark sealed bottles in a cool dry place until use. The yield for the alcohol extracts was 3.80 % and for the aqueous extracts it was 4.24 %.

Phyto-chemical screening

Phyto-chemical screening was carried out using standard qualitative methods described by Harbone (1973), Sowofora (1993), and Trease and Evans (2002). The extracts were screened for the presence of terpenoids, alkaloids, saponins, flavonoids, anthraquinones and phlobatannins.

Brine shrimp toxicity assay

The Brine shrimp toxicity assay was conducted as described by Vanhaecke et al, (1981), and Wanyoike et al, (2004). Briefly, Brine shrimp (*Artemia salina*) cysts were hatched in 2.9 % saline solution in an aerated incubation chamber for 24 hrs. The larvae (nauplii), were harvested by attracting them with light. To test the toxicity of the methanolic extracts, 50 g of *F. thonningii* methanolic extracts were dissolved in 5 ml DMSO and the solution was made up to 100 ml with 2.9 % saline solution. Aqueous extract solutions for the toxicity assay were made by dissolving 50 g of *F. thonningii* aqueous extracts in 100 ml of 2.9 % saline solution. Stock solutions were serially diluted to achieve the final working test solutions (5000, 500, 50, 5 and 0.5 µg/ml). Saline solution (2.9 %) was used as a negative control while potassium dichromate (3000, 300, 30 and 3 µg/ml) was used as a positive control. After 24 hrs, the numbers of dead nauplii were counted using a microscope. Nauplii were considered dead if no movements of appendages were observed within 10 s. The percentage mortality was then calculated for each concentration using the formula:

$$\text{Mortality (\%)} = \frac{\text{Number of dead nauplii}}{\text{Initial number of live nauplii}} \times 100$$

A graph relating mortality and the concentration of extracts was plotted using non linear regression.

Experimental animals

All experimental methods used in this study were approved by the Animal Ethics Screening Committee of the University of the Witwatersrand, Johannesburg (AESC 2011/22/2A). Five Sprague Dawley rat dams each with 8±1, six-day old pups were sourced from the Central Animal Services, University of the Witwatersrand. The dams and their respective litters were each allocated a perspex cage lined with wood shavings. Temperatures were maintained at 22±2°C and 12 hr light cycles (lights on at 0700 hrs), were followed.

Treatments

The suckling littermates were randomly divided (in a split-litter basis) into 5, treatment groups and remained with their respective dams for the duration of the study. The groups were distinctly identified using unique, colour-coded markings on their tails. Group 1 was the control and received distilled water (10 ml/kg b.w), while Groups 2 and 3, received low (50 mg/kg b.w), and high (500 mg/kg b.w) doses of aqueous extracts respectively. Groups 4 and 5 received low (50 mg/kg b.w), and high (500 mg/kg b.w), doses of methanolic extracts respectively. All test extracts were administered once daily between 08h00-10h00 by orogastric tube, for 7, consecutive days. Pups were allowed to nurse freely in between treatments. Dams did not receive test extracts but were given normal rat chow and water *ad libitum*.

Terminal studies

Blood for glucose and TG determinations was collected using the tail prick method before pups were euthanased by intra-peritoneal injection of sodium pentobarbitone (150mg.kg⁻¹). Blood was collected by cardiac puncture into heparinised tubes. Morphometric measurements of the empty GIT, and other visceral organs were carried out (Beya et al., 2012). Samples of the liver, caecum and the proximal small intestine were preserved in 10 % phosphate buffered formalin, routinely processed in paraffin embedded blocks and sectioned. The sections were stained with haematoxylin-eosin stain and examined under a light microscope. The right tibia and the right femur were dissected out and (after drying at 50°C for 7 days and weighed until their dry mass was constant) their lengths and masses were measured for linear growth determination. Plasma biochemical parameters were analysed using a colorimetric chemistry analyser (IDEXX VetTest, Netherlands). Hepatic lipids were measured as described by Bligh and Dyer (1959) and hepatic glycogen was determined using the indirect hydrolysis method (Passonneau and Lauderale, 1974).

Statistical Analysis

Data was expressed as mean ± SD. Statistical analysis was carried out using one way ANOVA followed by the Bonferroni post-hoc test with a significance level at p< 0.05.

Results

Phyto-chemical screening

Table1, shows the results obtained following the screening of *Ficus thonningii* leaf extracts for the presence of phytochemicals. Detectable levels of flavonoids, saponins, phlobatannins, and anthraquinones were observed in both aqueous and methanolic extracts while terpenoids and alkaloids were detected in methanolic extracts only. Aqueous extracts contained relatively higher levels of saponins than methanolic extracts.

Brine shrimp toxicity assay

The percentage mortalities of brine shrimp (*Artemia salina*), larvae in *F. thonningii* extracts are as shown in Figure 1 and 2. The median lethality concentration (LC₅₀-24 hr) for methanolic extracts of *F. thonningii* was 31.62 ± 2.8 µg/ml while the LC₅₀-24 hr of aqueous extracts was 119.3 ± 1.10 µg/ml. Potassium dichromate was used a positive control and its LC₅₀-24 hr was 0.3 µg/ml.

Table 1: Phyto-chemical constituents of *Ficus thonningii* extracts

Phytoconstituent	Methanolic extract	Aqueous extract
Terpenoids/ steroids	++	-
Alkaloids	+	-
Saponins	+	+++
Flavonoids	++	+
Phlobatannins	+	+
Anthraquinones	+	+

KEY: (+++) = very high, (++) = high, (+) = low, (-) = not detected

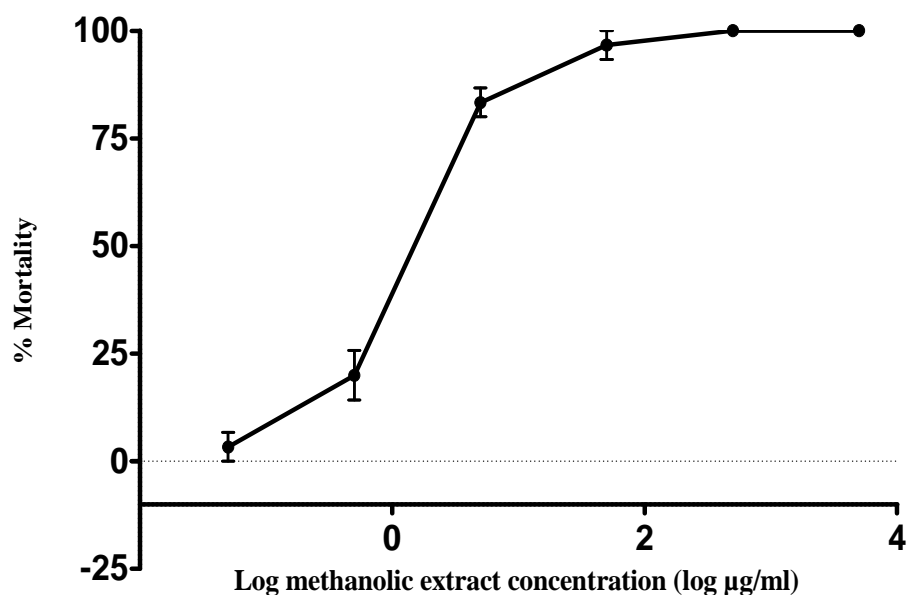


Figure 1: The toxicity effects of methanolic extracts of *Ficus thonningii* against brine shrimp (*Artemia salina*) larvae. Each point represents the mean mortality and error bars indicate the standard error of the mean (SEM).

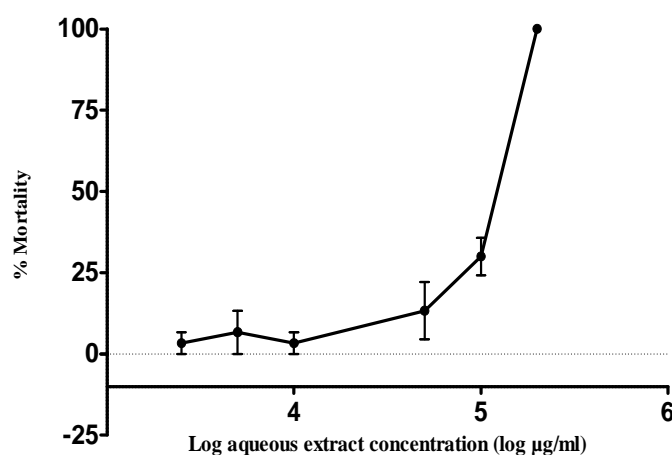


Figure 2: The toxicity effects of aqueous extracts of *Ficus thonningii* against brine shrimp (*Artemia salina*) larvae. Each point represents the mean mortality and error bars indicate the standard error of the mean (SEM).

Table 2: Effects of *Ficus thonningii* on the morphometry of the GIT and viscera of suckling rats

Organ		Treatment				
		Control	Low aqueous	High aqueous	Low methanolic	High methanolic
S.I	(%)	3.65 ± 1.18	4.01 ± 1.02	4.73 ± 1.31	4.51 ± 1.40	4.97 ± 1.22
S.I	(mm)	577.22 ± 54.26	588.50 ± 52.58	603.75 ± 33.67	582.22 ± 74.67	616.88 ± 38.72
L.I	(%)	0.44 ± 0.21	0.43 ± 0.11	0.45 ± 0.10	0.47 ± 0.13	0.49 ± 0.07
L.I	(mm)	78.89 ± 3.92	76.00 ± 6.97	78.25 ± 8.00	73.33 ± 11.73	73.13 ± 2.59
Caecum	(%)	0.42 ± 0.14	0.45 ± 0.12	0.64 ± 0.16	0.58 ± 0.28	0.59 ± 0.14
Stomach	(%)	0.63 ± 0.09	0.63 ± 0.06	0.64 ± 0.06	0.71 ± 0.06	0.77 ± 0.08**
Liver	(%)	3.48 ± 0.76	3.49 ± 0.53	3.58 ± 0.61	3.88 ± 0.72	3.79 ± 0.49
Spleen	(%)	0.63 ± 0.08	0.66 ± 0.12	0.62 ± 0.10	0.61 ± 0.10	0.59 ± 0.10
Pancreas	(%)	0.27 ± 0.05	0.29 ± 0.09	0.34 ± 0.11	0.27 ± 0.05	0.31 ± 0.13
Kidneys	(%)	1.17 ± 0.10	1.27 ± 0.12	1.22 ± 0.11	1.25 ± 0.13	1.26 ± 0.09

**= p<0.01

Effects on GIT and viscera

Table: 2, shows data obtained following gross morphometric measurements of the GIT and other visceral organs of the suckling rats after 7, days of treatment with *F. thonningii* extracts. The relative masses of the stomach were significantly higher in rats treated with the high dose (500 mg/kg b.w), of *F. thonningii* methanolic extracts in comparison to the control (p = 0.0007). The low methanolic dose exhibited no significant increase in relative masses of the stomach. There was an increase in the relative masses of the caeca across all treatment groups but this increase was not statistically significant (p = 0.0817). However, histological examination of the caeca showed a significant dose dependent increase in the thickness of mucosal layers of the aqueous and methanolic treatment groups (p = 0.0001) (Table 3).

Table 3: Effects of *Ficus thonningii* extracts on the morphometry of the caecum of suckling rats

	Treatment				
	Control	Low aqueous	High aqueous	Low methanolic	High methanolic
Mucosal layer (µm)	11.20 ± 0.84	14.80 ± 0.8**	16.20 ± 1.30***	12.75 ± 2.22	16.00 ± 0.82***
Muscularis + serosa (µm)	3.00 ± 0.71	3.80 ± 0.84	3.80 ± 0.84	3.25 ± 0.50	3.25 ± 0.5
Total thickness (µm)	14.40 ± 0.55	18.60 ± 1.34**	20.00 ± 2.12***	16.00 ± 2.58	19.25 ± 0.96**

=p<0.01; *=p<0.001

The muscularis and serosa of the caecum were not significantly different across all treatments. There were no significant difference/s observed between the relative masses of the small intestine across all treatment groups (p = 0.2155). Microscopic morphometric measurements showed a non significant increases in the villi height (p = 0.2431) and crypt depth (p = 0.6069) of treated groups in comparison to the control. The relative masses of the large intestine, liver, pancreata, spleen and kidneys of treated groups were not significantly different from the control (p > 0.05).

Effects on general health markers and hepatic storage metabolites

There was no significant difference in the hepatic lipid and glycogen content following 7, days of treatment with *F. thonningii* extracts. The high methanolic extract group had a significantly lower mean non fasting blood glucose concentration compared to the control and aqueous groups (p = 0.0008), but not compared to the low methanolic group. All other clinical biochemistry parameters were not significantly altered (Table 4).

Discussion

Preliminary, qualitative phyto-chemical screening of *F. thonningii* leaves revealed the presence of alkaloids, tannins, anthraquinones, terpenoids (steroids), flavonoids and saponins. Previous studies on the phyto-chemistry of *F. thonningii* have also reported the presence of these phytochemicals (Ndukwe et al., 2007; Usman et al., 2009; Ahur et al., 2010). These phyto-chemicals could be responsible for the broad pharmacological activity of *F. thonningii* that supports its widespread use in African traditional medicine. Although the methods used in this study were qualitative, the intensity of colour development in the determination of terpenoids, flavonoids, and alkaloids was higher in methanolic extracts as compared to aqueous extracts. These observations suggest that there were higher concentrations of these phyto-chemicals in methanolic extracts than there were in the aqueous extracts. This is probably because methanol has a higher polarity index than water hence will extract a higher concentration of phenolic compounds (Cowan, 1999). In addition, most plant secondary metabolites are organic in nature and hence partition well in organic solvents. This justifies the use of palm wine as a solvent in ethno-medicinal systems of West Africa (Akinsulire et

<http://dx.doi.org/10.4314/ajtcam.v11i2.10>

al., 2007). On the other hand, the degree of frothing observed when the aqueous extracts were tested for saponins was higher than in methanolic extracts. This suggests that there were higher saponin levels in aqueous extracts as compared to methanolic extracts. Saponins possess hydrophilic glycoside moieties which increases their solubility in water as compared to methanol (Cowan, 1999).

Our animal ethics screening committee does not permit the use of animals for acute toxicity studies so the brine shrimp lethality test was used to determine the *in vivo* toxicity of *F. thonningii* extracts. Plant extracts with LC₅₀-24 hr values greater than 1 mg/ml are considered to be non toxic (Sasidharan et al., 2010). The low LC₅₀-24 hr of methanolic extracts (31.62 ± 2.8 µg/ml) shows that the extracts are highly toxic to brine shrimp larvae, while aqueous extracts were non-toxic (LC₅₀-24 hr = 119.3 ± 1.10 mg/ml). These results also suggest that there are higher concentrations of bioactive compounds in methanolic extracts in comparison with aqueous extracts. However, although the methanolic extracts of *F. thonningii* were toxic to brine shrimp larvae, they did not exhibit any adverse effects on the general health profile of the rat pups.

Morphological assessment of the developing gut is a useful tool in evaluating the effects of dietary changes on the physiology of neonates (Baltrop and Brueton, 1990). Rats have an altricial mode of GIT development which is characterised by a relatively immature gut at birth which undergoes major structural and functional changes post-natal wise (Linderroth et al., 2005). Dietary changes during the suckling period are often followed by changes in mass, surface area, digestive and absorptive capacity of the neonatal GIT (Sangild, 2006). Phytochemicals increase proliferation of the enterocytes and growth of the gut mucosa (Pusztai et al., 1999), and hence they can induce precocious maturation of the neonatal GIT. Lectins from the red kidney bean (*Phaseolus vulgaris*), administered orally for 3, days, and were shown to induce precocious structural and functional maturation of the GIT in suckling rats (Linderroth et al., 2005). In the present study, the administration of *F. thonningii* extracts for 7, days led to a significant increase in the stomach mass and mucosal layer thicknesses of caeca of the suckling rat pups. The increase in stomach weights could indicate that *F. thonningii* extracts contain phytochemicals that mimic the action of and/or increase the release of regulatory peptides which increase the proliferation of parietal cells and hence exhibit trophic effects on the gut mucosa (Jain and Samuelson 2006). Unfortunately, histology was not performed on the stomach to ascertain whether the increase in mass was due to hypertrophy, hyperplasia or both. The higher activity of the high methanolic dose when compared to the low methanolic dose suggests a dose-related effect.

The increased thickness of the caecal mucosa and submucosal layers could be the result of the presence of soluble, non-digestible, fermentable polysaccharides in the extracts. Non-digestible polysaccharides (also known as prebiotics), increase proliferation of the mucosal cells of the caecum and colon (Steed and Macfarlane, 2009). They do so by stimulating the activity and growth of intestinal saccharolytic microbes which ferment non-starch polysaccharides to short chain fatty acids (SCFAs), (Steed and Macfarlane, 2009). SCFAs especially butyrate, have trophic effects on the caecal mucosa and are likely to be responsible for the architectural changes observed in the caecal walls of rats in this study (Lobo et al., 2007). An increase in caecal weight and the production of SCFAs could contribute to metabolic energy requirements of animals (Tagang et al., 2010). The phytochemicals in *F. thonningii* did not appear to have any adverse effects on the integrity of small intestine. Histomorphological analysis showed that there was no mucosal damage, villous atrophy or any apparent pathology in the intestine of treated rats.

Table 4: Effects of *Ficus thonningii* extracts on the clinical biochemistry, packed cell volume and hepatic storage metabolites of suckling rats

Plasma biochemical parameter	Treatment				
	Control	Low aqueous	High aqueous	Low methanolic	High methanolic
Glucose	6.20 ± 0.51	5.98 ± 0.28	5.83 ± 0.28	5.58 ± 0.61	5.00 ± 0.65***
Cholesterol (mmol/L)	4.44 ± 0.35	4.44 ± 0.46	4.31 ± 0.54	4.44 ± 0.70	4.37 ± 0.72
Urea (mmol/L)	7.26 ± 2.09	5.90 ± 1.10	5.81 ± 1.90	7.50 ± 1.8	5.98 ± 1.77
Creatinine (µmol/L)	31.75 ± 6.60	48.00 ± 54.99	31.38 ± 8.20	48.8 ± 48.36	33.63 ± 4.00
Phosphate (mmol/L)	3.14 ± 0.36	3.32 ± 0.52	3.05 ± 0.25	3.22 ± 0.24	2.93 ± 0.25
Calcium (mmol/L)	2.88 ± 0.34	2.91 ± 0.19	2.80 ± 0.13	2.99 ± 0.22	2.75 ± 0.17
Total protein (g/L)	42.63 ± 2.72	44.35 ± 2.49	42.00 ± 2.45	44.25 ± 5.70	43.38 ± 6.25
Globulin (g/L)	20.12 ± 1.89	20.75 ± 2.82	19.00 ± 1.69	17.25 ± 3.92	18.25 ± 2.43
Albumin (g/L)	22.50 ± 1.60	23.50 ± 1.69	22.75 ± 1.67	27.13 ± 6.79	25.38 ± 6.95
ALT (U/L)	31.00 ± 13.04	27.00 ± 11.55	25.63 ± 9.58	31.50 ± 18.28	28.38 ± 7.65
ALP (U/L)	410.38 ± 41.44	385.75 ± 86.75	371.00 ± 84.71	414.88 ± 77.29	363.50 ± 85.86
Amylase (U/L)	1117.88 ± 136.67	1061.63 ± 128.18	1092.75 ± 128.14	1140.75 ± 289.32	1064.50 ± 195.05
Total bilirubin (µmol/L)	10.38 ± 3.82	10.38 ± 3.89	8.25 ± 3.45	6.5 ± 2.93	8.25 ± 2.87
Glycogen	3.85 ± 0.74	4.31 ± 0.57	4.03 ± 0.57	3.68 ± 1.06	3.96 ± 1.5
Hepatic lipids	4.89 ± 1.00	4.29 ± 0.97	5.89 ± 1.47	5.98 ± 0.97	5.78 ± 1.07
Packed Cell Volumes	35.20 ± 2.51	34.50 ± 2.78	30.33 ± 3.05*	31.13 ± 2.90	34.45 ± 3.49

*=p<0.05; ***=p<0.001

Circulating levels of the enzymes alanine transaminase (ALT), and alkaline phosphatase (ALP), were used as surrogate markers of liver damage in this study. The results obtained show that at the doses used, *F. thonningii* extracts did not seem cause any parenchymal cell lesions, necrosis or drug induced-hepatitis confirming the histological observations. It was notable that ALP levels were significantly elevated in all of the pups including the control. ALP is also associated with osteoblastic activity and hence its levels are elevated in rapidly growing animals (Alhassan et al., 2009). Serum albumin, total bilirubin and total protein concentrations were also used as clinical tools in assessing the hepatosynthetic function. The concentrations of these biochemical markers of liver function in the blood were unaltered by administration of *F. thonningii* extracts at the doses used, confirming that *F. thonningii* was not hepatotoxic in the short term.

<http://dx.doi.org/10.4314/ajtcam.v11i2.10>

The glomerular filtration rate (GFR), is the gold standard for measuring kidney function (Stevens and Levey, 2009). Due to limitations in the study design, timed collections of urine for the determinations of GFR were difficult to achieve. As a result, serum concentrations of creatinine and urea were used as surrogate markers of kidney function. Serum creatinine concentrations depend exclusively on the GFR therefore can be used as a more reliable clinical estimation of GFR (Stevens and Levey, 2009). Increased levels of plasma creatinine and urea could indicate compromised tubular function and/or impaired glomerular filtration. Based on the use of these markers, the results obtained in this study showed that short term administration of crude extracts of *F. thonningii* exhibited no notable alterations in renal physiology.

Coker et al, (2009) reported that *F. thonningii* extracts had no deleterious effects on the haematonic value, whilst ethyl acetate leaf extracts of *F. thonningii* were reported to improve red blood cell counts in acetaminophen-treated rats (Ahur et al., 2010). Contrary to these reports, the results obtained in this study showed a significant reduction in the packed cell volumes of rats treated with high aqueous doses of *F. thonningii*. High levels of saponins, (detected in aqueous extracts), have been associated with haemolysis of red blood cells through interaction with membrane components such as proteins, phospholipids and cholesterol (Makkar et al., 2007). However, although the PCVs were reduced in the high aqueous group, there was no significant rise in the circulating bilirubin concentrations to confirm destruction of red blood cells. Reduced PCVs could result from reduced bioavailability of dietary iron due to the action of anti-nutritional factors such as tannins, phytate and other polyphenolic phyto-chemicals (Sandberg, 2002).

Although the treatments did not significantly alter the storage of metabolic substrates; the high methanolic dose (500 mg/kg b.w), significantly reduced glucose concentrations in comparison to the control. *Ficus thonningii* has been shown to possess hypoglycemic effects (Bwititi and Musabayane, 1997; Musabayane et al., 2007) and this supports its ethno-medicinal use in the treatment and management of diabetes mellitus.

Conclusion

The results obtained in this study introduce the first *in vivo* evidence that short term exposure to *F. thonningii* might exhibit trophic effects on the GIT of neonates. The study also showed that methanolic extracts of *F. thonningii* possess glucose-lowering effects which support the use of *F. thonningii* in managing diabetes mellitus.

Acknowledgements

The authors would like to thank the Faculty Research Committee, of the Faculty of Health Sciences, University of the Witwatersrand, Johannesburg; the Faculty of Medicine, National University of Science and Technology and the National Research Foundation of South Africa (NRF) for financial support for the study. We would also like to thank Ms Margaret Badenhorst, Mr Davison Moyo and the staff in the Central Animal Services for their technical assistance.

References

1. Agroforestry Tree Database. (2011). (<http://www.worldagroforestrycentre.org/sea/Products/AFDbases/AF/asp/speciesInfo.asp?SpID=866>) accessed 03/07/11.
2. Ahur, V. M., Madubunyi, I., Adenkola, A. Y. and Udem, S. C. (2010). The effect of acetyl acetate extract of *Ficus thonningii* (Blume) leaves on erythrocyte osmotic fragility and haematological parameters in acetaminophen-treated rats. *Com. Clin. Pathol.*, **10**: 1107-1111.
3. Akinsulire, O. R., Aibim, I. E., Adenipekun, T., Adelowotan, T. and Odugbemi, T. (2007). *In vitro* antimicrobial activity of crude extracts from plants *Bryophyllum pinnatum* and *Kalanchoe crenata*. *Afr. J. Tradit. Complement. Altern. Med.*, **4**: 338-344.
4. Alawa, J. P., Jokthan, G. E. and Akut, K. (2002). Ethnoveterinary medical practice for ruminants in the sub-humid zone of the northern Nigeria. *Prev. Vet. Med.*, **54**: 79-90.
5. Alhassan, A. J., Sule, M. S., Aliyu, S. A. and Aliyu, M. D. (2009). Ideal hepatotoxicity model in rats using carbon tetrachloride (CCl₄). *Bayero J. Pure and Appl. Sci.* **2**: 185-187.
6. Bah, S., Diallo, D., Dembele, B. and Paulsen, S. (2006). Ethnopharmacological survey of plants used for the treatment of schistosomiasis in Niono district, Mali. *J. Ethnopharmacol.*, **105**: 387-399.
7. Baltrop, D. and Brueton, M. J. (1990). The gastrointestinal tract and short term toxicity tests. In: *Short Term Toxicity Tests for Non-genotoxic Effects* (Bourdeoui, P. eds), John Wiley and Sons, pp 99.
8. Bamikole, M. A., Ikhatua, U. J., Arigbede, O. M., Babayemi, O. J. and Etela, I. (2004). An evaluation of the acceptability as forage of some nutritive and antinutritive components and of the dry matter degradation profiles of five species of *Ficus*. *Trop. Anim. Health Prod.*, **36**: 157-167.
9. Beya, W., Davidson, B. and Erlwanger, K. H. (2012). The effect of crude aqueous and alcohol extracts of *Aloe vera* on growth and abdominal viscera of suckling rats. *Afr. J. Tradit. Complement. Altern. Med.*, **9**: 553-560.
10. Bligh, E. G. and Dyer, W. J. (1959). A rapid method of total lipid extraction and purification. *Can. J. Anim. Sci.*, **37**: 911-917.
11. Bwititi, P. and Musabayane, C. T. (1997). The effect of plant extracts on plasma glucose in rats. *Acta Med Biol.*, **45**: 167-169.
12. Coker, M. E., Emikpe, B. O., Adeniyi, B. A. and Budale, B. A. (2009). The inflammatory potential, haematological and histological changes induced in rats due to the administration of methanolic extracts of *Ficus thonningii* leaves. *Afr. J. Pharm.*, **3**: 273-276.
13. Cousins, D. and Huffman, M. A. (2002). Medicinal properties in the diets of gorillas: an ethno-pharmacological evaluation. *Afr. Study Monogr* **23**: 65-89.
14. Cowan, M. M. (1999). Plant products as antimicrobial agents. *Clin. Microbiol Rev.*, **12**: 564-582.
15. Dangarembizi, R., Erlwanger, K. H., Moyo, D. and Chivandi, E. (2013). Phytochemistry, pharmacology and ethnomedicinal uses of *Ficus thonningii* (Blume Moraceae): A review. *Afr. J. Tradit. Complement. Altern. Med.* **10**: 203-212.
16. Erlwanger, K. H. and Cooper, R. G. (2008). The effects of orally administered crude alcohol and aqueous extracts of African potato (*Hypoxis hernerocallidea*) corm on the morphometry of viscera of suckling rats. *Food Chem. Toxicol.*, **46**: 136-139.
17. Gelfand, M., Mavi, S., Drummond, R. B. and Ndemera, B. (1985). *The Traditional Medicinal Practitioner. His principles of practice and pharmacopoeia*. Mambo Press, Gweru, Zimbabwe, pp. 411.
18. Greenham, J. R., Grayer, R. J., Harbone, J. B. and Reynolds, V. (2007). Intra- and Interspecific variations in vacuolar flavonoids among *Ficus* species from the Budongo forest, Uganda. *Biochem. System Ecol.*, **35**: 81-90.

<http://dx.doi.org/10.4314/ajtcam.v11i2.10>

19. Harbone, J. B. (1973). Phytochemical methods. Chapman Hall, London, United Kingdom, pp. 49-188.
20. Jain, R. N. and Samuelson L. C. (2006). Differentiation of the Gastric Mucosa II. Role of gastrin in gastric epithelial cell proliferation and maturation. *Am. J. Physiol. Gastrointest.*, **291**: 762-765.
21. Linderth, A., Biernat, M., Prykhodko, O., Kornolovska, I., Pusztai, A., Pierzynowski, S. G. and Westrom B. R. (2005). Induced growth and maturation of the gastrointestinal tract after *Phaseolus vulgaris* lectin exposure in suckling rats. *J. Pediatr. Gastroenterol. Nutr.* **41**:195-203.
22. Lobo, A. R., Colli, C., Alvares, E. P. and Fillisetti, T. M. C. (2007). Effects of fructans-containing yacon (*Smilax sonchifolius* Poepp & Endl) flour on caecum mucosal morphometry, calcium and magnesium balance and bone calcium retention in growing rats. *B. J. Nutr.*, **97**: 776-785.
23. Makkar, H. P. S., Siddhuraju, P. and Becker, K. (2007). Plant secondary metabolites. In: *Methods in Molecular Biology* (Walker, J.M eds). Humanapress, New Jersey, USA, pp. 171.
24. Minja, M. M. J. (1994). Medicinal plants used in promotion of animal health in Tanzania. *Animal Diseases Research Insit. Presses Universitaires de Namur, Dar Es Salaam*, pp. 335-364.
25. Musabayane, C. T., Gondwe, M., Kamadyaapa, D. R., Chuturgoon, A. A. and Ojewole, J. A. O. (2007). Effects of *F. thonningii* (Blume) Moraceae stem bark ethanolic extract on blood glucose, cardiovascular and kidney cell lines of the proximal (LLC-PK1) and distal tubules (MDBK). *Ren Fail.*, **29**: 389-397.
26. Ndukwe, I. G., Bello, A. I., Habila, J. D. and John, C. (2007). Phytochemical and antimicrobial screening of the crude petroleum spirit and methanol extracts of the stem bark, leaves and roots of *Ficus thonningii* (Blume). *Afr. J. Biotechnol.*, **16**: 2645-2649.
27. Njoronge, G. N. and Kibunga J. W. (2007). Herbal medicine acceptance, sources and utilisation for diarrhoea management in a cosmopolitan urban area (Thika, Kenya). *Afr. J. Ecol.*, **45**: 65-70.
28. Nwude, N. and Ibrahim, M. A. (1980). Plants used in traditional veterinary medical practice in Nigeria. *J. Vet. Pharmacol. Ther.*, **3**: 271-273.
29. Ogunwande, I. A., Sonibare, M. A., Thangi, T. D., Dung, N. X., Soladaye, M. O. and Monohunfolu, O. O. (2008). Comparative analysis of the oils of three *Ficus* species from Nigeria. *J. Essent. Oil Res.*, **20**
30. Passonneau, J. V. and Lauderale, V. R. (1974). A comparison of three methods of glycogen measurement in tissue. *Anal. Biochem.*, **60**: 405-412.
31. Prelude medicinal plants database. (2011). (http://www.metafro.be/prelude/view_plant?pi=06040 accessed 27/04/11.)
32. Pusztai, A., Ewen, S. W. B., Grant, G. and Bardocz, S. (1999). Effect of lectins on digestion of food and body metabolism. *COST-98 Effects of antinutrients on the nutritional value of legume diets* **1**, 22-28.
33. Sandberg, A. S. (2002). Bioavailability of minerals in legumes. *B. J. Nutr.*, **88**: 281-285.
34. Sangild, P. T. (2006). Transitions in the life of the gut at birth. In: *Digestive Physiology of Pigs; Proceedings of the 8th Symposium* (Lindberg, J. E. and Ogle, B eds.), pp. 1695-1711.
35. Sasidharan, S., Jinxuan, O., Latha, L. Y. and Amutha, S. (2011). *In vivo* toxicity study of *Ganoderma boninense*. *Afr. J. Pharm. Pharmacol.*, **16**: 1819-1823.
36. Schmidt, E., Lutter, M. and McClelland, W. (2002). *Trees and Shrubs of Mpumalanga and Kruger National Park*. Jacana, South Africa, pp. 80.
37. Sowofora, A. (1993). *Medicinal plants and Traditional Medicine in Africa*. Spectrum Books, Ibadan, Nigeria, pp. 55-71.
38. Steed, H. and Macfarlane, S. (2009). Mechanisms of prebiotics – impact on health. In: *Prebiotics and Prebiotics Science and Technology Volume 1* (Charalampopoulos, D. and Rastall, R.A. eds.). Springer, New York, USA , pp. 136-139.
39. Stevens, L. A. and Levey, A. S. (2009). Measured GFR as a confirmatory test for estimated GFR. *J. Am. Soc. Nephrol.*, **20**: 2305-2313.
40. Tagang, A., Ishaku, P. K and Abdullah, A. (2010). Volatile fatty acids: production in ruminants and the role of monocarboxylate transporters. A review. *Afr. J. Biotechnol.*, **9**: 6229-6232.
41. Teklehaymanot, T. and Giday, M. (2007). Ethnobotanical study of medicinal plants used by people in Zegie Peninsula, North Western Ethiopia. *J. Ethnobiol. Ethnomedicine.*, **3**:12.
42. Trease, G. E. and Evans, W. C. (2002). *Pharmacognosy* 15th edition. Saunders, London, United Kingdom. pp. 42-44, 221-229, 246-249, 304-306.
43. Usman, H., Abdulrahman, F. I. and Usman, A. (2009). Qualitative phytochemical screening and *in vitro* antimicrobial effects of methanol stem bark extract of *Ficus thonningii* (Moraceae). *Afr. J. Tradit. Compliment. Altern. Med.*, **6**: 289-295.
44. Vanhaecke, P., Persoone, G., Claus, C. and Sorgeloos, P. (1981). Proposal for a short-term toxicity with *Artemia nauplii*. *Ecotox. Environ. Safe* **5**: 382-387.
45. Wanyoike, G. N., Chhabra, S. C., Langat-Thoruwa, C. C. and Omar, S. A. (2004). Brine shrimp toxicity and antiplasmodial activity of five Kenyan medicinal plants. *J. Ethnopharmacol.*, **90**: 129-133.
46. Watt, J. M. and Breyer-Brandwijk, G. M. (1962). *The medicinal and poisonous plants of Southern and Eastern Africa*, 2nd ed. E. and S Livingstone Ltd, Edinburgh and London, pp. 773.